

# e8 Approach to the Patient with a Heart Murmur

Patrick T. O’Gara, Eugene Braunwald

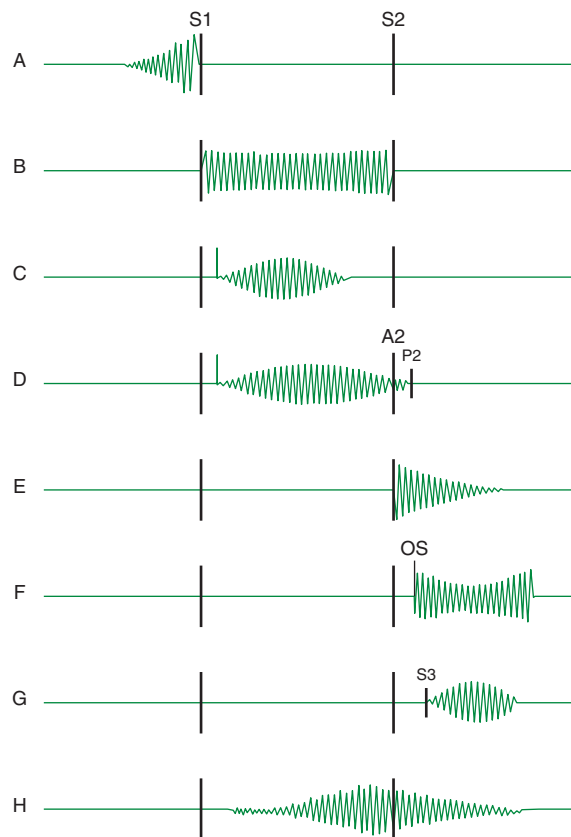
The differential diagnosis of a heart murmur begins with a careful assessment of its major attributes and response to bedside maneuvers. The history, clinical context, and associated findings provide additional clues by which the significance of a heart murmur is established. Following completion of these initial steps, noninvasive testing can be pursued to clarify any remaining ambiguity and to provide additional anatomic and physiologic information that will impact patient management. Accurate bedside identification of a heart murmur can also inform decisions regarding referral to a cardiovascular specialist, the indications for antibiotic or rheumatic fever prophylaxis, and the need to restrict various forms of physical activity.

Heart murmurs are caused by audible vibrations that are due to increased turbulence from accelerated blood flow through normal or abnormal orifices; flow through a narrowed or irregular orifice into a dilated vessel or chamber; or backward flow through an incompetent valve, ventricular septal defect, or patent ductus arteriosus. They are traditionally defined in terms of their timing within the cardiac cycle (Fig. e8-1). *Systolic murmurs* begin with or after the first heart sound ( $S_1$ ) and terminate at or before the component ( $A_2$  or  $P_2$ ) of the second heart sound ( $S_2$ ) that corresponds to their side of origin (left or right, respectively). *Diastolic murmurs* begin with or after the associated component of  $S_2$  and end at or before the subsequent  $S_1$ . *Continuous murmurs* are not confined to either phase of the cardiac cycle, but rather begin in early systole and proceed through  $S_2$  into all or part of diastole. The accurate timing of heart murmurs is the first step in their identification. The distinction between  $S_1$  and  $S_2$ , and therefore systole and diastole, is usually a straightforward process, but can be difficult in the setting of a tachyarrhythmia, in which case the heart sounds can be distinguished by simultaneous palpation of the carotid arterial pulse. The upstroke should closely follow  $S_1$ .

**Duration** The duration of a heart murmur depends on the length of time in the cardiac cycle over which a pressure difference exists between two cardiac chambers, the left ventricle and the aorta, the right ventricle and the pulmonary artery, or the great vessels. The magnitude and variability of this pressure difference dictate the velocity of flow; the degree of turbulence; and the resulting frequency, configuration, and intensity of the murmur. The diastolic murmur of chronic aortic regurgitation (AR) is a blowing, high-frequency event, whereas the murmur of mitral stenosis (MS), indicative of the left atrial–left ventricular diastolic pressure gradient, is a low-frequency event, heard as a rumbling sound with the bell of the stethoscope. The frequency components of a heart murmur may vary at different sites of auscultation. The coarse systolic murmur of aortic stenosis (AS) may sound higher-pitched and more acoustically pure at the apex, a phenomenon eponymously referred to as the *Gallavardin effect*. Some murmurs may have a distinct or unusual quality, such as the “honking” sound appreciated in some patients with mitral regurgitation (MR) due to mitral valve prolapse (MVP).

The configuration of a heart murmur may be crescendo, decrescendo, crescendo-decrescendo, or plateau. The decrescendo configuration of the murmur of chronic AR (Fig. e8-1E) can be understood in terms of the progressive decline in the diastolic pressure gradient between the aorta and the left ventricle. The crescendo-decrescendo configuration of the murmur of AS reflects the changes in the systolic pressure gradient between the left ventricle and the aorta as ejection occurs, whereas the plateau configuration of the murmur of chronic rheumatic MR (Fig. e8-1B) is consistent with the large and nearly constant pressure difference between the left ventricle and the left atrium.

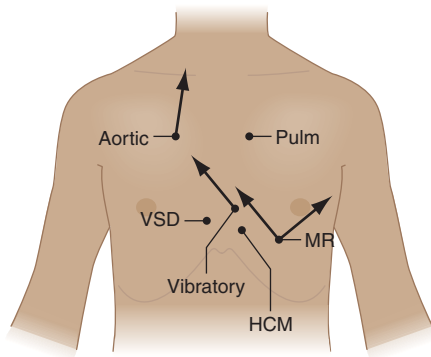
**Intensity** The intensity of a heart murmur is graded on a scale of 1–6 (or I–VI). A grade 1 murmur is very soft and is heard with great effort.



**FIGURE e8-1** Diagram depicting principal heart murmurs. **A.** Pre-systolic murmur of mitral or tricuspid stenosis. **B.** Holosystolic (pansystolic) murmur of mitral or tricuspid regurgitation or of ventricular septal defect. **C.** Aortic ejection murmur beginning with an ejection click and fading before the second heart sound. **D.** Systolic murmur in pulmonic stenosis spilling through the aortic second sound, pulmonic valve closure being delayed. **E.** Aortic or pulmonary diastolic murmur. **F.** Long diastolic murmur of mitral stenosis following the opening snap. **G.** Short mid-diastolic inflow murmur following a third heart sound. **H.** Continuous murmur of patent ductus arteriosus. (Adapted from P Wood, *Diseases of the Heart and Circulation*, London, Eyre & Spottiswood, Ltd., 1968.)

A grade 2 murmur is easily heard, but not particularly loud. A grade 3 murmur is loud, but is not accompanied by a palpable thrill over the site of maximal intensity. A grade 4 murmur is very loud and accompanied by a thrill. A grade 5 murmur is loud enough to be heard with only the edge of the stethoscope touching the chest, whereas a grade 6 murmur is loud enough to be heard with the stethoscope slightly off the chest. Murmurs of grade 3 or greater intensity usually signify important structural heart disease and indicate high blood flow velocity at the site of murmur production. Small ventricular septal defects (VSDs), for example, are accompanied by loud, usually grade 4 or greater, systolic murmurs as blood is ejected at high velocity from the left to the right ventricle. Low velocity events, such as left-to-right shunting across an atrial septal defect (ASD), are usually silent. The intensity of a heart murmur may also be diminished by any process that increases the distance between the intracardiac source and the stethoscope on the chest wall, such as obesity, obstructive lung disease, and a large pericardial effusion. The intensity of a murmur may also be misleadingly soft when cardiac output is significantly reduced.

**Location and Radiation** Recognition of the location and radiation of the murmur helps facilitate its accurate identification (Fig. e8-2). Adventitious sounds, such as a systolic click or diastolic snap, or abnormalities of  $S_1$  or  $S_2$ , may provide additional clues. Careful attention to the characteristics of the murmur and other heart sounds during the



**FIGURE e8-2 Maximal intensity and radiation of six isolated systolic murmurs.** HOCM, hypertrophic obstructive cardiomyopathy; MR, mitral regurgitation; Pulm, pulmonary stenosis; Aortic, aortic stenosis; VSD, ventricular septal defect. (From JB Barlow, *Perspectives on the Mitral Valve*. Philadelphia, FA Davis, 1987, p 140.)

respiratory cycle and the performance of simple bedside maneuvers when indicated complete the auscultatory examination. These features, and recommendations for further testing, are discussed below in the context of specific systolic, diastolic, and continuous heart murmurs (Table e8-1).

### SYSTOLIC HEART MURMURS

**Early Systolic Murmurs** Early systolic murmurs begin with  $S_1$  and extend for a variable period of time, ending well before  $S_2$ . Their causes are relatively few in number. *Acute severe MR* into a normal-sized, relatively noncompliant left atrium results in an early, decrescendo systolic murmur best heard at or just medial to the apical impulse. These characteristics reflect the progressive attenuation of the pressure gradient between the left ventricle and the left atrium during systole due to the rapid rise in left atrial pressure caused by the sudden volume load into an unprepared chamber, and contrast sharply with the auscultatory features of chronic MR. Clinical settings in which acute, severe MR occur include: (1) papillary muscle rupture complicating acute myocardial infarction (MI) (Chap. 239), (2) rupture of chordae tendineae in the setting of myxomatous mitral valve disease (MVP, Chap. 230), (3) infective endocarditis (Chap. 118), and (4) blunt chest wall trauma.

Acute, severe MR from papillary muscle rupture usually accompanies an inferior, posterior, or lateral MI and occurs 2–7 days after presentation. It is often signaled by chest pain, hypotension, and pulmonary edema, but a murmur may be absent in up to 50% of cases. The posteromedial papillary muscle is involved six to ten times more frequently than the anterolateral papillary muscle. The murmur is to be distinguished from that associated with post-MI ventricular septal rupture, which is accompanied by a systolic thrill at the left sternal border in nearly all patients and is holosystolic in duration. A new heart murmur following MI is an indication for transthoracic echocardiography (TTE) (Chap. 222), which allows bedside delineation of its etiology and pathophysiologic significance. The distinction between acute MR and ventricular septal rupture can also be achieved with right heart catheterization, sequential determination of oxygen saturations, and analysis of the pressure waveforms (tall  $v$  wave in the pulmonary artery wedge pressure in MR). Post-MI mechanical complications of this nature mandate aggressive medical stabilization and prompt referral for surgical repair.

Spontaneous chordal rupture can complicate the course of myxomatous mitral valve disease (MVP) and result in new-onset or “acute on chronic” severe MR. MVP may occur as an isolated phenomenon or the lesion may be part of a more generalized connective tissue disorder as seen, for example, in patients with Marfan syndrome. Acute severe MR as a consequence of infective endocarditis results from destruction of leaflet tissue, chordal rupture, or both. Blunt chest wall trauma is usually self-evident, but may be disarmingly trivial. It can result in papillary muscle contusion and rupture, chordal detachment,

**TABLE e8-1 PRINCIPAL CAUSES OF HEART MURMURS**

#### Systolic Murmurs

Early systolic	
Mitral	Acute MR
VSD	Muscular Nonrestrictive with pulmonary hypertension
Tricuspid	TR with normal pulmonary artery pressure
Mid-systolic	
Aortic	Obstructive Supravalvular—supravalvular aortic stenosis, coarctation of the aorta Valvular—AS and aortic sclerosis Subvalvular—discrete, tunnel or HOCM Increased flow, hyperkinetic states, AR, complete heart block Dilatation of ascending aorta, atheroma, aortitis
Pulmonary	Obstructive Supravalvular—pulmonary artery stenosis Valvular—pulmonic valve stenosis Subvalvular—infundibular stenosis (dynamic) Increased flow, hyperkinetic states, left-to-right shunt (e.g., ASD) Dilatation of pulmonary artery
Late systolic	
Mitral	MVP, acute myocardial ischemia
Tricuspid	TVP
Holosystolic	Atrioventricular valve regurgitation (MR, TR) Left-to-right shunt at ventricular level (VSD)

#### Early Diastolic Murmurs

Aortic regurgitation	Valvular: congenital (bicuspid valve), rheumatic deformity, endocarditis, prolapse, trauma, post-valvulotomy Dilatation of valve ring: aorta dissection, annulo-aortic ectasia, cystic medial degeneration, hypertension, ankylosing spondylitis Widening of commissures: syphilis
Pulmonic regurgitation	Valvular: post-valvulotomy, endocarditis, rheumatic fever, carcinoid Dilatation of valve ring: pulmonary hypertension; Marfan syndrome Congenital: isolated or associated with tetralogy of Fallot, VSD, pulmonic stenosis

#### Mid-Diastolic Murmurs

Mitral	Mitral stenosis Carey-Coombs murmur (mid-diastolic apical murmur in acute rheumatic fever) Increased flow across nonstenotic mitral valve (e.g., MR, VSD, PDA, high-output states, and complete heart block)
Tricuspid	Tricuspid stenosis Increased flow across nonstenotic tricuspid valve (e.g., TR, ASD, and anomalous pulmonary venous return)
	Left and right atrial tumors (myxoma) Severe AR (Austin Flint murmur)

#### Continuous Murmurs

Patent ductus arteriosus	Proximal coronary artery stenosis
Coronary AV fistula	Mammary souffle of pregnancy
Ruptured sinus of Valsalva aneurysm	Pulmonary artery branch stenosis
Aortic septal defect	Bronchial collateral circulation
Cervical venous hum	Small (restrictive) ASD with MS
Anomalous left coronary artery	Intercostal AV fistula

**Note:** AR, aortic regurgitation; AS, aortic stenosis; ASD, atrial septal defect; AV, arteriovenous; HOCM, hypertrophic obstructive cardiomyopathy; MR, mitral regurgitation; MS, mitral stenosis; MVP, mitral valve prolapse; PDA, patent ductus arteriosus; TR, tricuspid regurgitation; TVP, tricuspid valve prolapse; VSD, ventricular septal defect.

**Source:** E Braunwald, JK Perloff, in D Zipes et al (eds): *Braunwald's Heart Disease*, 7th ed. Philadelphia, Elsevier, 2005; PJ Norton, RA O'Rourke, in E Braunwald, L Goldman (eds): *Primary Cardiology*, 2d ed. Philadelphia, Elsevier, 2003.

or leaflet avulsion. TTE is indicated in all cases of suspected acute severe MR to define its mechanism and severity, delineate left ventricular size and systolic function, and provide an assessment of suitability for primary valve repair.

A congenital, small muscular VSD (Chap. 229) may be associated with an early systolic murmur. The defect closes progressively during septal contraction and thus the murmur is confined to early systole. It is localized to the left sternal border (Fig. e8-2) and is usually of grade 4 or 5 intensity. Signs of pulmonary hypertension or left ventricular volume overload are absent. Anatomically large and uncorrected VSDs, which usually involve the membranous portion of the septum, may lead to pulmonary hypertension. The murmur associated with the left-to-right shunt, which may earlier have been holosystolic, becomes limited to the first portion of systole as the elevated pulmonary vascular resistance leads to an abrupt rise in right ventricular pressure and an attenuation of the interventricular pressure gradient during the remainder of the cardiac cycle. In such instances, signs of pulmonary hypertension (right ventricular lift, loud and single or closely split  $S_2$ ) may predominate. The murmur is best heard along the left sternal border but is softer. Suspicion of a VSD is an indication for TTE.

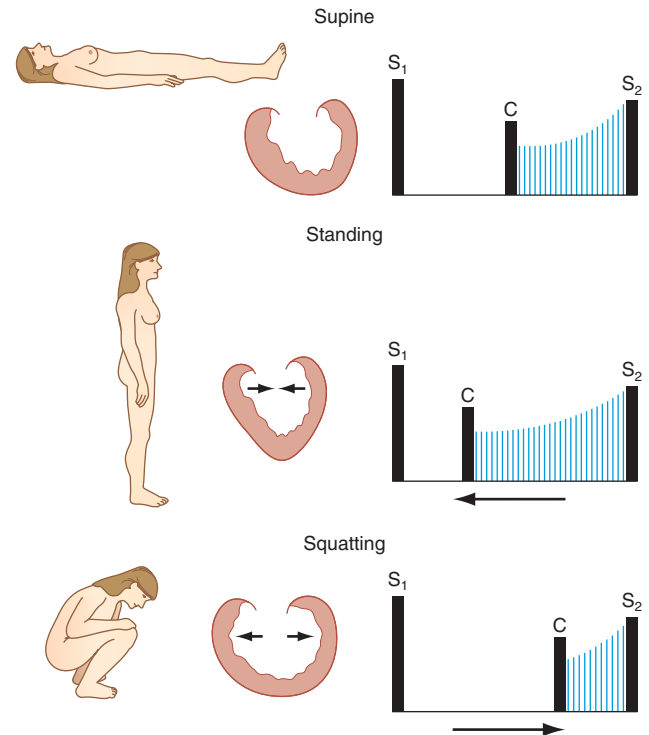
Tricuspid regurgitation (TR) with normal pulmonary artery pressures, as may occur with infective endocarditis, may produce an early systolic murmur. The murmur is soft (grade 1 or 2), best heard at the lower left sternal border, and may increase in intensity with inspiration (Carvallo's sign). Regurgitant "c-v" waves may be visible in the jugular venous pulse. TR in this setting is not associated with signs of right heart failure.

**Mid-Systolic Murmurs** Mid-systolic murmurs begin at a short interval following  $S_1$ , end before  $S_2$  (Fig. e8-1C), and are usually crescendo-decrescendo in configuration. Aortic stenosis is the most common cause of a mid-systolic murmur in an adult. The murmur of AS is usually loudest to the right of the sternum in the second intercostal space (aortic area, Fig. e8-2) and radiates into the carotids. Transmission of the mid-systolic murmur to the apex, where it becomes higher pitched, is common (Gallavardin effect, see above).

Differentiation of this apical systolic murmur from MR can be difficult. The murmur of AS will increase in intensity, or become louder, in the beat following a premature beat, whereas the murmur of MR will remain of constant intensity from beat to beat. The intensity of the AS murmur also varies directly with the cardiac output. With a normal cardiac output, a systolic thrill and grade 4 or higher murmur suggest severe AS. The murmur is softer in the setting of heart failure and low cardiac output. Other auscultatory findings of severe AS include a soft or absent  $A_2$ , paradoxical splitting of  $S_2$ , an apical  $S_4$ , and a late-peaking systolic murmur. In children, adolescents, and young adults with congenital valvular AS, an early ejection sound (click) is usually audible, more often along the left sternal border than at the base. Its presence signifies a flexible, noncalcified bicuspid valve (or one of its variants) and localizes the left ventricular outflow obstruction to the valvular (rather than sub- or supra-valvular) level.

Assessment of the volume and rate of rise of the carotid pulse can provide additional information. A small and delayed upstroke (*parvus et tardus*) is consistent with severe AS. The carotid pulse examination is less discriminatory, however, in older patients with stiffened arteries. The electrocardiogram (ECG) shows signs of left ventricular hypertrophy (LVH) as the severity of the stenosis increases. TTE is indicated to assess the anatomic features of the aortic valve, the severity of the stenosis, left ventricular size, wall thickness and function, and the size and contour of the aortic root and proximal ascending aorta.

The obstructive form of hypertrophic cardiomyopathy (HOCM) is associated with a mid-systolic murmur that is usually loudest along the left sternal border or between the left lower sternal border and the apex (Chap. 231, Fig. e8-2). The murmur is produced by both dynamic left ventricular outflow tract obstruction and MR, and thus its configuration is a hybrid between ejection and regurgitant phenomena. The intensity of the murmur may vary from beat to beat, and following provocative maneuvers, but usually does not exceed grade 3. The

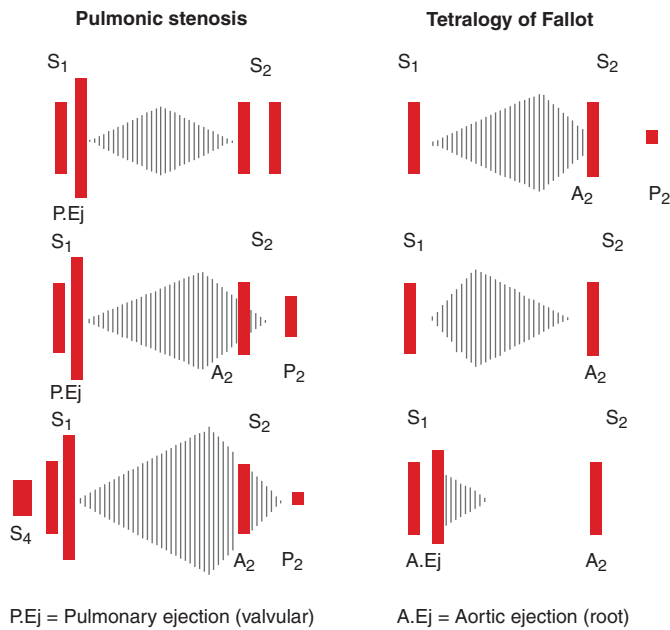


**FIGURE e8-3** A mid-systolic nonejection sound (C) occurs in mitral valve prolapse and is followed by a late systolic murmur that crescendos to the second heart sound ( $S_2$ ). Standing decreases venous return; the heart becomes smaller; C moves closer to the first heart sound ( $S_1$ ) and the mitral regurgitant murmur has an earlier onset. With prompt squatting, venous return increases; the heart becomes larger; C moves toward  $S_2$ , and the duration of the murmur shortens. (From JA Shaver, JJ Leonard, DF Leon, *Examination of the Heart, Part IV, Auscultation of the Heart*. Dallas, American Heart Association, 1990, p 13. Copyright, American Heart Association.)

murmur will classically increase in intensity with maneuvers that result in increasing degrees of outflow tract obstruction, such as a reduction in preload or afterload (Valsalva, standing, vasodilators) or to an augmentation of contractility (inotropic stimulation). Maneuvers that increase preload (squatting, passive leg raising, volume administration) or afterload (squatting, vasopressors) or that reduce contractility ( $\beta$ -adrenoreceptor blockers) decrease the intensity of the murmur. In rare patients, there may be reversed splitting of  $S_2$ . A sustained left ventricular apical impulse and an  $S_4$  may be appreciated. In contrast to AS, the carotid upstroke is rapid and of normal volume. Rarely, it is bisferiens or bifid in contour (see Fig. 220-2D) due to mid-systolic closure of the aortic valve. LVH is present on the ECG and the diagnosis is confirmed by TTE. Although the systolic murmur associated with MVP behaves similarly to that due to HOCM in response to the Valsalva maneuver and to standing/squatting (Fig. e8-3), these two lesions can be distinguished on the basis of their associated findings, such as the presence of LVH in HOCM or a non-ejection click in MVP.

The mid-systolic, crescendo-decrescendo murmur of congenital pulmonic stenosis (PS, Chap. 229), is best appreciated in the second and third left intercostal spaces (pulmonic area) (Figs. e8-2 and e8-4). The duration of the murmur lengthens and the intensity of  $P_2$  diminishes with increasing degrees of valvular stenosis (Fig. e8-1D). An early ejection sound, the intensity of which decreases with inspiration, is heard in younger patients. A parasternal lift and ECG evidence of right ventricular hypertrophy indicate severe pressure overload. If obtained, the chest x-ray may show poststenotic dilatation of the main pulmonary artery. TTE is recommended for complete characterization.

Significant left-to-right intracardiac shunting due to an ASD (Chap. 229) leads to an increase in pulmonary blood flow and a grade 2–3 mid-systolic murmur at the mid to upper left sternal border with fixed



**FIGURE e8-4 Left.** In valvular pulmonic stenosis with intact ventricular septum, right ventricular systolic ejection becomes progressively longer, with increasing obstruction to flow. As a result, the murmur becomes longer and louder, enveloping the aortic component of the second heart sound ( $A_2$ ). The pulmonic component ( $P_2$ ) occurs later, and splitting becomes wider but more difficult to hear because  $A_2$  is lost in the murmur and  $P_2$  becomes progressively fainter and lower pitched. As the pulmonic gradient increases, isometric contraction shortens until the pulmonary valvular ejection sound fuses with the first heart sound ( $S_1$ ). In severe pulmonic stenosis with concentric hypertrophy and decreasing right ventricular compliance, a fourth heart sound appears. **Right.** In tetralogy of Fallot with increasing obstruction at pulmonic infundibular area, an increasing amount of right ventricular blood is shunted across the silent ventricular septal defect and flow across the obstructed outflow tract decreases. Therefore, with increasing obstruction the murmur becomes shorter, earlier, and fainter.  $P_2$  is absent in severe tetralogy of Fallot. A large aortic root receives almost all cardiac output from both ventricular chambers, and the aorta dilates and is accompanied by a root ejection sound that does not vary with respiration. (From JA Shaver, JJ Leonard, DF Leon, *Examination of the Heart, Part IV, Auscultation of the Heart*. Dallas, American Heart Association, 1990, p 45. Copyright, American Heart Association.)

splitting of  $S_2$ . Ostium secundum ASDs are most common. Features suggestive of a primum ASD include the coexistence of MR due to a cleft anterior mitral valve leaflet and left axis deviation of the QRS complex on ECG. With sinus venosus ASDs, the left-to-right shunt is usually not large enough to result in a systolic murmur, though the ECG may show abnormalities of sinus node function. A grade 2 or 3 mid-systolic murmur may also be heard best at the upper left sternal border in patients with idiopathic dilatation of the pulmonary artery. A pulmonary ejection sound is present. TTE is indicated to evaluate a grade 2 or 3 mid-systolic murmur when there are other signs of cardiac disease.

An isolated grade 1 or 2 midsystolic murmur, heard in the absence of symptoms or signs of heart disease, is most often a benign finding for which no further evaluation, including TTE, is necessary. The most common example of a murmur of this type in an older adult patient is the crescendo-decrescendo murmur of aortic valve sclerosis, heard at the second right interspace (Fig. e8-2). Aortic sclerosis is defined as focal thickening and calcification of the aortic valve to a degree that does not interfere with leaflet opening. The carotid upstrokes are normal and electrocardiographic LVH is not present. A grade 1 or 2 mid-systolic murmur can often be heard at the left sternal border with pregnancy, hyperthyroidism, or anemia, physiologic states that are

associated with accelerated blood flow. *Still's murmur* refers to a benign grade 2, vibratory mid-systolic murmur at the lower left sternal border in normal children and adolescents (Fig. e8-2).

**Late Systolic Murmurs** A late systolic murmur that is best heard at the left ventricular apex is often due to MVP (Chap. 230). Often, this murmur is introduced by one or more nonejection clicks. The radiation of the murmur can help identify the specific mitral leaflet involved in the process of prolapse or flail. The term *flail* refers to the movement made by an unsupported portion of the leaflet after loss of its chordal attachment(s). With posterior leaflet prolapse or flail, the resultant jet of MR is directed anteriorly and medially, as a result of which the murmur radiates to the base of the heart and masquerades as AS. Anterior leaflet prolapse or flail results in a posteriorly directed MR jet that radiates to the axilla or left infrascapular region. Leaflet flail is associated with a murmur of grade 3 or 4 intensity that can be heard throughout the precordium in thin-chested patients. The presence of an  $S_3$  or a short, rumbling mid-diastolic murmur, signifies severe MR.

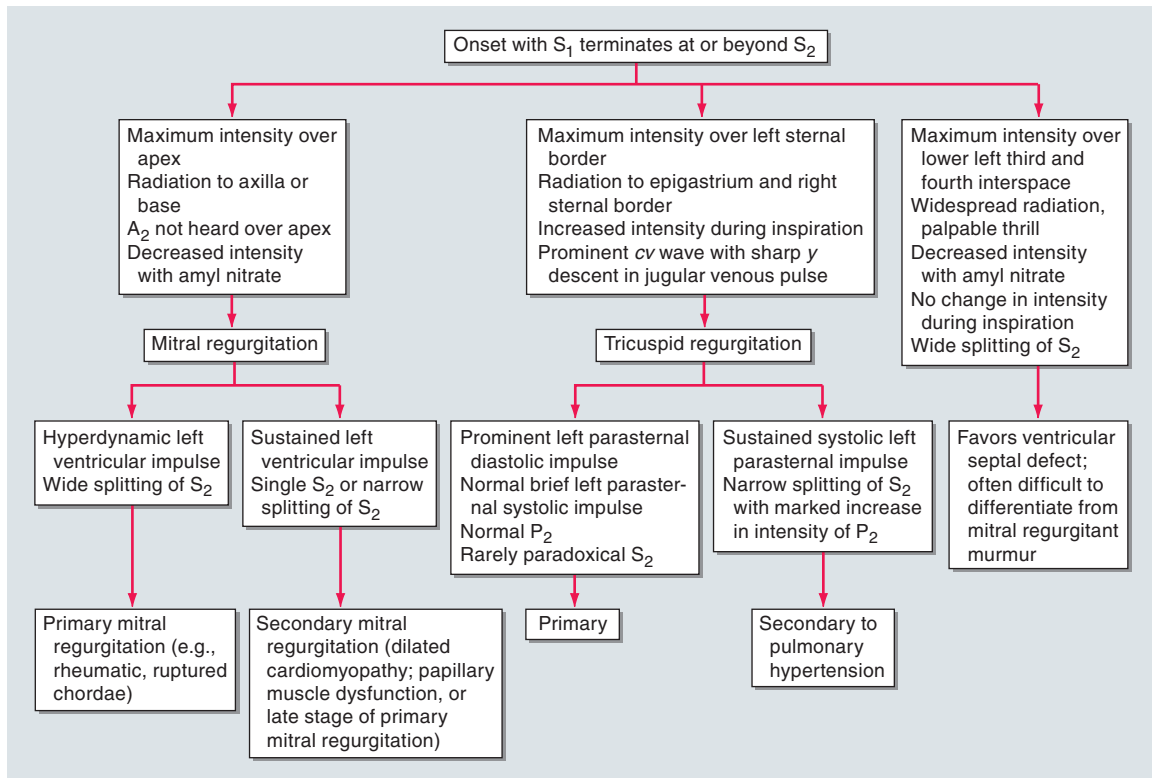
Bedside maneuvers that decrease left ventricular preload, such as standing, will cause the click and murmur of MVP to move closer to the first heart sound, as leaflet prolapse occurs earlier in systole. Standing also causes the murmur to become louder and longer. With squatting, left ventricular preload and afterload are increased abruptly, and the click and murmur move away from the first heart sound, as leaflet prolapse is delayed. The murmur becomes softer and shorter in duration (Fig. e8-3). As noted above, these responses to standing and squatting are similar to those observed in patients with HOCM.

A late, apical systolic murmur indicative of MR may be heard transiently in the setting of acute myocardial ischemia. It is due to apical tethering and malcoaptation of the leaflets in response to structural and functional changes of the ventricle and mitral annulus. The intensity of the murmur varies as a function of left ventricular afterload and will increase in the setting of hypertension. TTE is recommended for assessment of late systolic murmurs.

**Holosystolic Murmurs** (Figs. e8-1B and e8-5) Holosystolic murmurs begin with  $S_1$  and continue through systole to  $S_2$ . They are usually indicative of chronic mitral or tricuspid valve regurgitation or a VSD, and warrant TTE for further characterization. The holosystolic murmur of chronic MR is best heard at the left ventricular apex and radiates to the axilla (Fig. e8-2). It is usually high pitched and plateau in configuration because of the wide difference between left ventricular and left atrial pressure throughout systole. In contrast to acute MR, left atrial compliance is normal or even increased in chronic MR. As a result, there is only a small increase in left atrial pressure for any increase in regurgitant volume.

There are several conditions associated with chronic MR and an apical holosystolic murmur, including rheumatic scarring of the leaflets, mitral annular calcification, and severe left ventricular chamber enlargement. The circumference of the mitral annulus increases as the left ventricle enlarges and leads to failure of leaflet coaptation with central MR in patients with dilated cardiomyopathy (Chap. 231). The severity of the MR is worsened by any contribution from apical displacement of the papillary muscles and leaflet tethering. Because the mitral annulus is contiguous with the left atrial endocardium, gradual enlargement of the left atrium from chronic MR will result in further stretching of the annulus and more MR and thus, "MR begets MR." Chronic severe MR results in enlargement and leftward displacement of the left ventricular apex and, in some patients, a diastolic filling complex as described previously.

The holosystolic murmur of chronic TR is generally softer than that of MR, is loudest at the left lower sternal border, and usually increases in intensity with inspiration (Carvallo's sign). Associated signs include "c-v" waves in the jugular venous pulse, an enlarged and pulsatile liver, ascites, and peripheral edema. The abnormal jugular venous wave forms are the predominant finding and are very often seen in the absence of an audible murmur, despite Doppler echocardiographic verification of TR. Causes of primary TR include myxomatous disease



**FIGURE e8-5 Differential diagnosis of a holosystolic murmur.**  $S_1$ , first heart sound;  $S_2$ , second heart sound;  $A_2$ , aortic component of the second heart sound;  $P_2$ , pulmonic component of the second heart

sound. [From C Chatterjee, in K Chatterjee et al (eds): *Cardiology: An Illustrated Text/Reference*, Philadelphia, Lippincott, 1991, with permission.]

(prolapse), endocarditis, rheumatic disease, carcinoid, Ebstein's anomaly, and chordal detachment following the performance of right ventricular endomyocardial biopsy. TR is more commonly a passive process that results secondarily from chronic elevations of pulmonary artery and right ventricular pressures, leading to right ventricular enlargement, annular dilatation, papillary muscle displacement, and failure of leaflet coaptation.

The holosystolic murmur of a VSD is loudest at the mid- to lower left sternal border (Fig. e8-2) and radiates widely. A thrill is present at the site of maximal intensity in the majority of patients. There is no change in the intensity of the murmur with inspiration. The intensity of the murmur varies as a function of the anatomic size of the defect. Small, restrictive VSDs, as exemplified by the *maladie de Roger*, create a very loud murmur due to the significant and sustained systolic pressure gradient between the left and right ventricles. With large defects, the ventricular pressures tend to equalize, shunt flow is balanced, and a murmur is not appreciated. The distinction between post-MI ventricular septal rupture and MR has been reviewed previously.

## DIASTOLIC HEART MURMURS

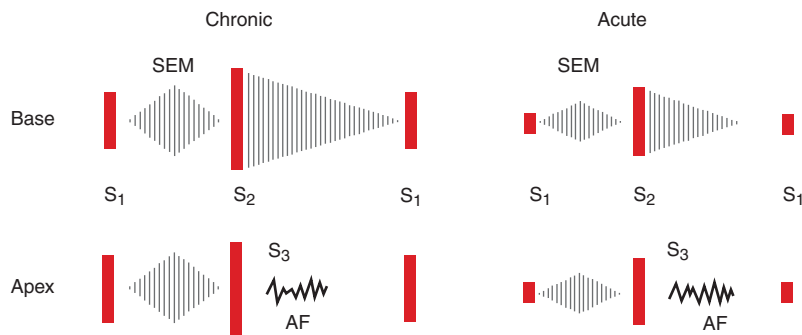
**Early Diastolic Murmurs** (Fig. e8-1E) Chronic AR results in a high-pitched, blowing, decrescendo, early to mid-diastolic murmur that begins following the aortic component of  $S_2$  ( $A_2$ ) and is best heard at the second right interspace (Fig. e8-6). The murmur may be soft and difficult to hear, unless auscultation is performed with the patient leaning forward at end-expiration. This maneuver brings the aortic root closer to the anterior chest wall. Radiation of the murmur may provide a clue as to the cause of the AR. With primary valve disease, such as that due to congenital bicuspid disease, prolapse, or endocarditis, the diastolic murmur tends to radiate along the left sternal border. When AR is caused by aortic root disease, the diastolic murmur may radiate along the right sternal border. Diseases of the aortic root cause dilatation or distortion of the aortic annulus and failure of leaflet coaptation. Causes include Marfan syndrome with aneurysm formation, annulo-aortic ectasia, ankylosing spondylitis, and aortic dissection.

Chronic, severe AR may also produce a lower pitched mid- to late, grade 1 or 2 diastolic murmur at the apex (Austin Flint murmur), which is thought to reflect turbulence at the mitral inflow area from the admixture of regurgitant (aortic) and forward (mitral) blood flow (Fig. e8-1G). This lower pitched apical diastolic murmur can be distinguished from that due to MS by the absence of an opening snap and the response of the murmur to a vasodilator challenge. Lowering afterload with an agent such as amyl nitrate will decrease the duration and magnitude of the aortic–left ventricular diastolic pressure gradient, and thus the Austin Flint murmur of severe AR will become shorter and softer. The intensity of the diastolic murmur of mitral stenosis (Fig. e8-7) may either remain constant or increase with afterload reduction because of the reflex increase in cardiac output and mitral valve flow.

Although AS and AR may coexist, a grade 2 or 3 crescendo-decrescendo mid-systolic murmur is frequently heard at the base of the heart in patients with isolated severe AR, and is due to an increased volume and rate of systolic flow. Accurate bedside identification of coexistent AS can be difficult, unless the carotid pulse examination is abnormal or the mid-systolic murmur is of grade 4 or greater intensity. In the absence of heart failure, chronic severe AR is accompanied by several peripheral signs of significant diastolic run-off, including a wide pulse pressure, a water-hammer carotid upstroke (Corrigan's pulse), and Quincke's pulsations of the nail beds. The diastolic murmur of *acute severe AR* (Fig. e8-6) is notably shorter in duration and lower pitched than the murmur of chronic AR. It can be very difficult to appreciate in the presence of a rapid heart rate. These attributes reflect the abrupt rate of rise of diastolic pressure within the unprepared and noncompliant left ventricle, and the correspondingly rapid decline in the aortic–left ventricular diastolic pressure gradient. Left ventricular diastolic pressure may increase sufficiently to result in premature closure of the mitral valve and a soft first heart sound. Peripheral signs of significant diastolic run-off are absent.

Pulmonic regurgitation (PR) results in a decrescendo, early to mid-diastolic murmur (*Graham Steell murmur*) that begins after the pul-

## Aortic Regurgitation



**FIGURE e8-6 Contrast between the auscultatory findings in chronic and acute aortic regurgitation.** In chronic aortic regurgitation, a prominent systolic ejection murmur resulting from the large forward stroke volume is heard at the base and the apex and ends well before the second heart sound ( $S_2$ ). The aortic diastolic regurgitant murmur begins with  $S_2$  and continues in a decrescendo fashion, terminating before the first heart sound ( $S_1$ ). At the apex, the mid-diastolic component of Austin Flint murmur (AF) is introduced by a prominent third heart sound ( $S_3$ ). A pre-systolic component of the AF is also heard. In acute aortic regurgitation there is a significant decrease in the intensity of the systolic ejection murmur compared with that of chronic aortic regurgitation because of the decreased forward stroke volume.  $S_1$  is markedly decreased in intensity because of premature closure of the mitral valve, and at the apex the presystolic component of the AF murmur is absent. The early diastolic murmur at the base ends well before  $S_1$  because of equilibration of the left ventricle and aortic end-diastolic pressure. Significant tachycardia is usually present. (From JA Shaver: *Heart Dis Stroke* 2:100, 1994.)

monic component of  $S_2$  ( $P_2$ ), is best heard at the second left inter-space, and radiates along the left sternal border. The intensity of the murmur may increase with inspiration. PR is most commonly due to dilatation of the valve annulus from chronic elevation of the pulmonary artery pressure. Signs of pulmonary hypertension, including a right ventricular lift and a loud, single or narrowly split  $S_2$ , are present. These features also help distinguish PR from AR as the cause of a decrescendo diastolic murmur heard along the left sternal border. PR in the absence of pulmonary hypertension can occur with endocarditis or a congenitally deformed valve. It is usually present following repair of tetralogy of Fallot in childhood. When pulmonary hypertension is not present, the diastolic murmur is softer and lower pitched than the classic Graham Steell murmur, and the examiner can be misled as to the severity of the PR.

TTE is indicated for the further evaluation of the patient with an early to mid-diastolic murmur. Longitudinal assessment of the severity of the valve lesion and ventricular size and systolic function help guide the decision for surgical management. TTE can also provide anatomic information regarding the root and proximal ascending aorta, though computed tomographic or magnetic resonance angiography may be indicated for more precise characterization (Chap. 222).

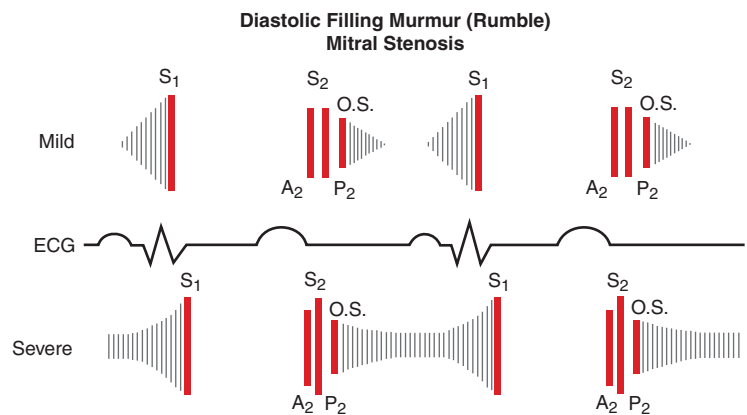
**Mid-Diastolic Murmurs** (Figs. e8-1G and e8-1H) Mid-diastolic murmurs result from obstruction and/or augmented flow at the level of the mitral or tricuspid valve. Rheumatic fever is the most common cause of MS (Fig. e8-7). In younger patients with pliable valves,  $S_1$  is loud and the murmur begins after an opening snap, which is a high-pitched sound that occurs shortly after  $S_2$ . The distance between the pulmonic component of the second heart sound ( $P_2$ ) and the opening snap is inversely related to the magnitude of the left atrial to left ventricular pressure gradient. The murmur of MS is low pitched and thus is best heard with the bell of the stethoscope. It is loudest at the left ventricular apex and often only appreciated when the patient is turned in the left lateral decubitus position. It is usually of grade 1 or 2 intensity, but may be absent when the cardiac output is severely reduced despite significant obstruction. The intensity

of the murmur increases during maneuvers that increase cardiac output and mitral valve flow, such as exercise. The duration of the murmur reflects the length of time over which left atrial pressure exceeds left ventricular pressure. An increase in the intensity of the murmur just before  $S_1$ , a phenomenon known as *pre-systolic accentuation* (Figs. e8-1A, e8-7), occurs in patients in sinus rhythm and is due to a late increase in transmural flow with atrial contraction. Pre-systolic accentuation does not occur in patients with atrial fibrillation.

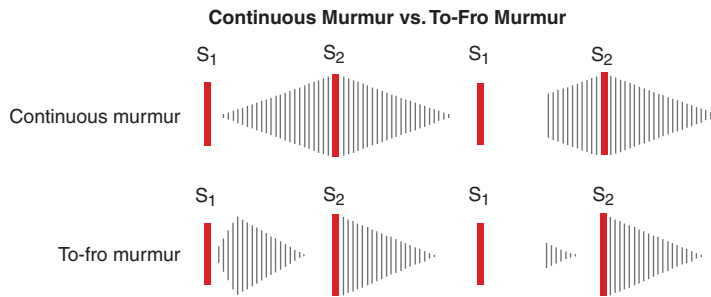
The mid-diastolic murmur associated with tricuspid stenosis is best heard at the lower left sternal border and increases in intensity with inspiration. A prolonged  $\gamma$  descent may be visible in the jugular venous wave form. This murmur is very difficult to hear and often obscured by left-sided acoustical events.

There are several other causes of mid-diastolic murmurs. Large left atrial myxomas may prolapse across the mitral valve and cause variable degrees of obstruction to left ventricular inflow (Chap. 233). The murmur associated with an atrial myxoma may change in duration and intensity with changes in body position. An opening snap is not present and there is no pre-systolic accentuation. Augmented mitral diastolic flow can occur with isolated severe MR or with a large left-to-right shunt at the ventricular or great vessel level and produce a soft, rapid filling sound ( $S_3$ ) followed by a short, low-pitched mid-diastolic apical murmur. The Austin Flint murmur of severe, chronic AR has already been described.

A short mid-diastolic murmur is rarely heard during an episode of acute rheumatic fever (Carey-Coombs murmur) and is due to enhanced flow through an edematous mitral valve. An opening snap is not present in the acute phase and the murmur dissipates with resolution of the acute attack. Complete heart block with dyssynchronous atrial and ventricular activation may be associated with intermittent mid- to-late diastolic murmurs if atrial contraction occurs when the mitral valve is partially closed. Mid-diastolic murmurs indicative of increased tricuspid valve flow can occur with severe, isolated TR and with large ASDs and significant left-to-right shunting. Other signs



**FIGURE e8-7 Diastolic filling murmur (rumble) in mitral stenosis.** In mild mitral stenosis, the diastolic gradient across the valve is limited to the two phases of rapid ventricular filling in early diastole and pre-systole. The rumble may occur during either or both periods. As the stenotic process becomes severe, a large pressure gradient exists across the valve during the entire diastolic filling period, and the rumble persists throughout diastole. As the left atrial pressure becomes greater, the interval between  $A_2$  and the opening snap shortens. In severe mitral stenosis, secondary pulmonary hypertension develops and results in a loud  $P_2$  and the splitting interval usually narrows. ECG, electrocardiogram. (From JA Shaver, JJ Leonard, DF Leon, *Examination of the Heart, Part IV, Auscultation of the Heart*. Dallas, American Heart Association, 1990, p 55. Copyright, American Heart Association.)



**FIGURE e8-8 Comparison of the continuous murmur and the to-fro murmur.** During abnormal communication between high-pressure and low-pressure systems, a large pressure gradient exists throughout the cardiac cycle, producing a continuous murmur. A classic example is patent ductus arteriosus. At times, this type of murmur can be confused with a to-fro murmur, which is a combination of systolic ejection murmur and a murmur of semilunar valve incompetence. A classic example of a to-fro murmur is aortic stenosis and regurgitation. A continuous murmur crescendos to around the second heart sound ( $S_2$ ), whereas a to-fro murmur has two components. The mid-systolic ejection component decrescendos and disappears as it approaches  $S_2$ . (From JA Shaver, JJ Leonard, DF Leon, *Examination of the Heart, Part IV, Auscultation of the Heart*. Dallas, American Heart Association, 1990, p 55. Copyright, American Heart Association.)

of an ASD are present (Chap. 229), including fixed-splitting of  $S_2$  and a mid-systolic murmur at the mid- to upper left sternal border. TTE is indicated for evaluation of the patient with a mid- to late diastolic murmur. Findings specific to the diseases discussed above will help guide management.

### CONTINUOUS MURMURS

(Figs. e8-1H and e8-8) Continuous murmurs begin in systole, peak near the second heart sound, and continue into all or part of diastole. Their presence throughout the cardiac cycle implies a pressure gradient between two chambers or vessels during both systole and diastole. The continuous murmur associated with a patent ductus arteriosus is best heard at the upper left sternal border. Large, uncorrected shunts may lead to pulmonary hypertension, attenuation or obliteration of the diastolic component of the murmur, reversal of shunt flow, and differential cyanosis of the lower extremities. A ruptured sinus of Valsalva aneurysm creates a continuous murmur of abrupt onset at the upper right sternal border. Rupture typically occurs into a right heart chamber, and the murmur is indicative of a continuous pressure difference between the aorta and either the right ventricle or right atrium. A continuous murmur may also be audible along the left sternal border with a coronary arteriovenous fistula and at the site of an arteriovenous fistula used for hemodialysis access. Enhanced flow through enlarged intercostal collateral arteries in patients with aortic coarctation may produce a continuous murmur along the course of one or more ribs. A cervical bruit with both systolic and diastolic components (a to-fro murmur, Fig. e8-8) usually indicates a high-grade carotid artery stenosis.

Not all continuous murmurs are pathologic. A continuous venous hum can be heard in healthy children and young adults, especially during pregnancy. It is best appreciated in the right supraclavicular fossa and can be obliterated by pressure over the right internal jugular vein or by having the patient turn his/her head toward the examiner. The continuous mammary souffle of pregnancy is created by enhanced arterial flow through engorged breasts and usually appears during the late third trimester or early puerperium. The murmur is louder in systole. Firm pressure with the diaphragm of the stethoscope can eliminate the diastolic portion of the murmur.

### DYNAMIC AUSCULTATION

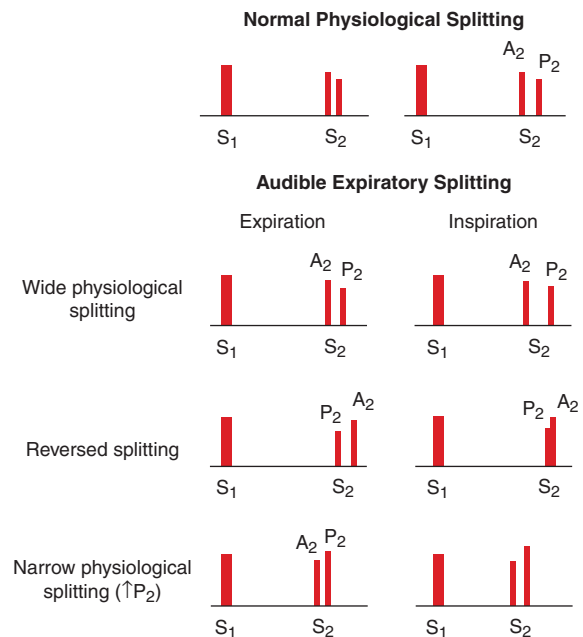
(Tables e8-2 and 220-1) Careful attention to the behavior of heart murmurs during simple maneuvers that alter cardiac hemodynamics can provide important clues as to their cause and significance.

### TABLE e8-2 DYNAMIC AUSCULTATION: BEDSIDE MANEUVERS THAT CAN BE USED TO CHANGE THE INTENSITY OF CARDIAC MURMURS (SEE TEXT)

1. Respiration
2. Isometric exercise (handgrip)
3. Transient arterial occlusion
4. Pharmacologic manipulation of preload and/or afterload
5. Valsalva maneuver
6. Rapid standing/squatting
7. Post-premature beat

**Respiration** Auscultation should be performed during quiet respiration or with a modest increase in inspiratory effort, as more forceful movement of the chest tends to obscure the heart sounds. Left-sided murmurs may be best heard at end-expiration, when lung volumes are minimized and the heart and great vessels are brought closer to the chest wall. This phenomenon is characteristic of the murmur of AR. Murmurs of right-sided origin, such as tricuspid or pulmonic regurgitation, increase in intensity during inspiration. The intensity of left-sided murmurs either remains constant or decreases with inspiration.

Bedside assessment should also account for the behavior of  $S_2$  with respiration and the dynamic relationship between the aortic and pulmonic components (Fig. e8-9). Reversed splitting can be a feature of severe AS, HOCM, left bundle branch block, right ventricular apical pacing, or acute myocardial ischemia. Fixed splitting of  $S_2$  in the presence of a grade 2 or 3 mid-systolic murmur at the mid- or upper left sternal border indicates an ASD. Physiologic but wide splitting during the respiratory cycle implies either premature aortic



**FIGURE e8-9 Top.** Normal physiologic splitting. During expiration, the aortic ( $A_2$ ) and pulmonic ( $P_2$ ) components of the second heart sound are separated by  $<30$  ms and are appreciated as a single sound. During inspiration, the splitting interval widens, and  $A_2$  and  $P_2$  are clearly separated into two distinct sounds. **Bottom.** Audible expiratory splitting. Wide physiologic splitting is caused by a delay in  $P_2$ . Reversed splitting is caused by a delay in  $A_2$ , resulting in paradoxical movement; i.e., with inspiration  $P_2$  moves towards  $A_2$ , and the splitting interval narrows. Narrow physiologic splitting occurs in pulmonary hypertension, and both  $A_2$  and  $P_2$  are heard during expiration at a narrow splitting interval because of the increased intensity and high-frequency composition of  $P_2$ . (From JA Shaver, JJ Leonard, DF Leon, *Examination of the Heart, Part IV, Auscultation of the Heart*. Dallas, American Heart Association, 1990, p 17. Copyright, American Heart Association.)

e50 valve closure, as can occur with severe MR, or delayed pulmonic valve closure due to PS or right bundle branch block.

**Alterations of Systemic Vascular Resistance** Murmurs can change characteristics following maneuvers that alter systemic vascular resistance and left ventricular afterload. The systolic murmurs of MR and VSD become louder during sustained handgrip, simultaneous inflation of blood pressure cuffs on both upper extremities to pressures 20–40 mmHg above systolic pressure for 20 s, or infusion of a vasopressor agent. The murmurs associated with AS or HOCM will either become softer or remain unchanged with these maneuvers. The diastolic murmur of AR becomes louder in response to interventions that raise systemic vascular resistance.

Opposite changes in systolic and diastolic murmurs may occur with the use of pharmacologic agents that lower systemic vascular resistance. Inhaled amyl nitrite is now rarely used for this purpose but can help to distinguish the murmur of AS or HOCM from that of either MR or VSD. The former two murmurs increase in intensity, whereas the latter two become softer after exposure to amyl nitrite. As noted previously, the Austin Flint murmur of severe AR becomes softer, but the mid-diastolic rumble of MS becomes louder, in response to the abrupt lowering of systemic vascular resistance with amyl nitrite.

**Changes in Venous Return** The Valsalva maneuver results in an increase in intrathoracic pressure, followed by a decrease in venous return, ventricular filling, and cardiac output. The majority of murmurs decrease in intensity during the strain phase of the maneuver. Two notable exceptions are the murmurs associated with MVP and obstructive HOCM, both of which become louder during the Valsalva maneuver. The murmur of MVP may also become longer as leaflet prolapse occurs earlier in systole at smaller ventricular volumes. These murmurs behave in a similar and parallel fashion with standing. Both the click and the murmur of MVP move closer in timing to S<sub>1</sub> on rapid standing (Fig. e8-3). The increase in the intensity of the murmur of HOCM is predicated on the augmentation of the dynamic left ventricular outflow tract gradient that occurs with reduced ventricular filling. Squatting results in abrupt increases in both venous return and left ventricular afterload, changes that predictably cause a decrease in the intensity and duration of the murmurs associated with MVP and HOCM. The click and murmur of MVP move away from S<sub>1</sub> with squatting.

**Post-Premature Ventricular Contraction** A change in the intensity of a systolic murmur in the first beat after a premature beat, or in the beat after a long cycle length in patients with atrial fibrillation, can help distinguish AS from MR, particularly in an older patient in whom the murmur of AS is well transmitted to the apex. Systolic murmurs due to left ventricular outflow obstruction, including that due to AS, increase in intensity in the beat following a premature beat because of the combined effects of enhanced left ventricular filling and post-extrasystolic potentiation of contractile function. Forward flow accelerates, causing an increase in the gradient and a louder murmur. The intensity of the murmur of MR does not change in the post-premature beat as there is relatively little further increase in mitral valve flow or change in the left ventricular to left atrial gradient.

### THE CLINICAL CONTEXT

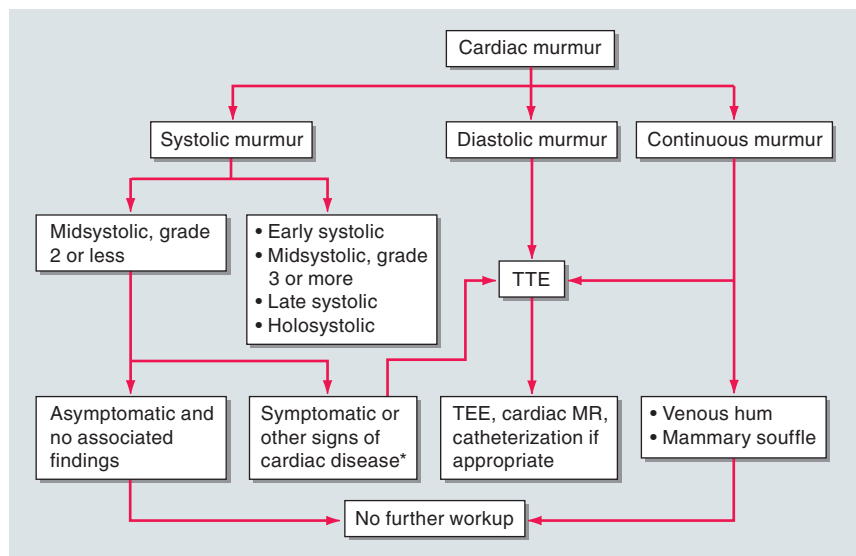
Additional clues as to the etiology and importance of a heart murmur can be gleaned from the history and other physical examination findings. Symptoms suggestive of cardiovascular, neurologic, or pulmonary disease should help focus the differential diagnosis, as should findings relevant to the jugular venous pressure and wave forms, the arterial pulses, other heart sounds, the lungs, abdomen, skin, and extremities. In many instances, laboratory studies, an ECG, and/or a chest x-ray may have been ob-

tained earlier and may contain valuable information. A patient with suspected infective endocarditis, for example, may have a murmur in the setting of fever, chills, anorexia, fatigue, dyspnea, splenomegaly, petechiae, and positive blood cultures. A new systolic murmur in a patient with a marked fall in blood pressure after a recent MI suggests myocardial rupture. On the other hand, an isolated grade 1 or 2 mid-systolic murmur at the left sternal border in a healthy, active, and asymptomatic young adult is most likely a benign finding for which no further evaluation is indicated. The context in which the murmur is appreciated often dictates the need for further testing.

### ECHOCARDIOGRAPHY

(See Fig. e8-10, Chaps. 220 and 222) Echocardiography with color flow and spectral Doppler is a valuable tool for the assessment of cardiac murmurs. Information regarding valve structure and function, chamber size, wall thickness, ventricular function, estimated pulmonary artery pressures, intracardiac shunt flow, pulmonary and hepatic vein flow, and aortic flow can be readily ascertained. It is important to note that Doppler signals of trace or mild valvular regurgitation of no clinical consequence can be detected with structurally normal tricuspid, pulmonic, and mitral valves. Such signals are not likely to generate enough turbulence to create a murmur.

Echocardiography is indicated for the evaluation of patients with early, late, or holosystolic murmurs, and for patients with grade 3 or louder mid-systolic murmurs. Patients with grade 1 or 2 mid-systolic murmurs, but other symptoms or signs of cardiovascular disease, including those from ECG or chest x-ray, should also undergo echocardiography. Echocardiography is indicated for the evaluation of any patient with a diastolic murmur and for patients with continuous murmurs not due to a venous hum or mammary souffle. Echocardiography should also be considered when there is a clinical need to verify normal cardiac structure and function in a patient whose symptoms and signs are likely noncardiac in origin. The performance of serial echocardiography to follow the course of asymptomatic individuals with valvular heart disease is a central feature of their longitudinal assessment and provides valuable information that may impact on decisions regarding the timing of surgery. Routine echocardiography is *not* recommended for asymptomatic patients with a grade 1 or 2 mid-systolic murmur without other signs of heart disease. For this category of patients, referral to a cardiovascular specialist should be considered if doubt exists regarding the significance of the murmur after the initial examination.



**FIGURE e8-10 Strategy for evaluating heart murmurs.** \*If an electrocardiogram or chest x-ray has been obtained and is abnormal, echocardiography is indicated. TTE, transthoracic echocardiography; TEE, transesophageal echocardiography; MR, magnetic resonance. (Adapted from Bonow et al.)



The selective use of echocardiography outlined above has not been subjected to rigorous cost-effective analysis. At least one study has suggested that initial referral of pediatric patients with heart murmurs to a specialist results in modest cost savings. For some clinicians, handheld or miniaturized cardiac ultrasound devices have replaced the stethoscope. Although several reports attest to the improved sensitivity of such devices for the detection of valvular heart disease, accuracy is highly operator dependent and incremental cost considerations have not been adequately addressed. The use of electronic or digital stethoscopes with spectral display capabilities has also been proposed as a method to improve the characterization of heart murmurs and the teaching of cardiac auscultation.

#### OTHER CARDIAC TESTING

(Chap. 222, Fig. e8-10) In relatively few patients, clinical assessment and TTE do not adequately characterize the origin and significance of a heart murmur. Transesophageal echocardiography (TEE) can be considered for further evaluation, especially when the TTE windows are limited by body size, chest configuration, or intrathoracic pathology. TEE offers enhanced sensitivity for the detection of a wide range of structural cardiac disorders. Electrocardiographically gated cardiac magnetic resonance (CMR) imaging, although limited in its ability to display valvular morphology, can provide quantitative information regarding valvular function, stenosis severity, regurgitant fraction, shunt flow, chamber and great vessel size, ventricular function, and myocardial perfusion. CMR has greater capability than cardiac computed tomography (CCT) in this regard and has largely supplanted the need for cardiac catheterization and invasive hemodynamic assessment when there is a discrepancy between the clinical and echocardiographic findings. Coronary angiography is performed routinely in most adult patients prior to valve surgery, especially when there is a suspicion of coronary artery disease predicated on symptoms, risk factors, and/or age.

#### INTEGRATED APPROACH

The accurate identification of a heart murmur begins with a systematic approach to cardiac auscultation. Characterization of its major at-

tributes, as reviewed above, allows the examiner to construct a preliminary differential diagnosis, which is then refined by integration of information available from the history, associated cardiac findings, the general physical examination, and the clinical context. The need for and urgency of further testing follow sequentially. Correlation of the findings on auscultation with the noninvasive data provides an educational feedback loop and an opportunity for improving physical examination skills. Cost constraints mandate that noninvasive imaging be justified on the basis of its incremental contribution to diagnosis, treatment, and outcome. Additional study is required to assess the cost-effective application of newer imaging technology.

#### FURTHER READINGS

- BARRETT MJ et al: Mastering cardiac murmurs: The power of repetition. *Chest* 126(2):470, 2004
- BONOW RO et al: ACC/AHA 2006 Guidelines for the management of patients with valvular heart disease: A report of the American College of Cardiology/American Heart Association Task Force on Practice Guidelines (Committee on Management of Patients with Valvular Heart Disease). American College of Cardiology Web Site. Available at <http://www.acc.org/clinical/guidelines/valvular/index.pdf>
- CHOUNDHRY NK, ETCHELLS EE: Does this patient have aortic regurgitation? *JAMA* 281:2231, 1999
- ETCHELLS E et al: Does this patient have an abnormal systolic heart murmur? *JAMA* 277(7):564, 1997
- FANG J, O'GARA P: The history and physical examination, in *Braunwald's Heart Disease. A Textbook of Cardiovascular Medicine*, 8th ed, P Libby et al (eds). Philadelphia, Saunders Elsevier, 2008
- MURGO JP: Systolic ejection murmurs in the era of modern cardiology. What do we really know? *J Am Coll Cardiol* 32(6):1596, 1998
- TAVEL ME: Cardiac auscultation: A glorious past—and it does have a future! *Circulation* 113:1255, 2006
- VUKANOVIC-CRILEY JM et al: Competency in cardiac examination skills in medical students, trainees, physicians and faculty: A multicenter study. *Arch Intern Med* 166(6):610, 2006

