

Peter Habermeyer · Petra Magosch · Sven Lichtenberg

Classifications and Scores of the Shoulder

Peter Habermeyer · Petra Magosch · Sven Lichtenberg

Classifications and Scores of the Shoulder

 Springer

Professor Dr. Peter Habermeyer

Dr. Petra Magosch

Dr. Sven Lichtenberg

ATOS Praxisklinik Heidelberg

Bismarckstraße 9–15

69115 Heidelberg

Germany

ISBN-10 3-540-24350-X Springer Berlin Heidelberg New York

ISBN-13 978-3-540-24350-2 Springer Berlin Heidelberg New York

Library of Congress Control Number: 2005938553

This work is subject to copyright. All rights are reserved, whether the whole or part of the material is concerned, specifically the rights of translation, reprinting, reuse of illustrations, recitation, broadcasting, reproduction on microfilm or in any other way, and storage in data banks. Duplication of this publication or parts thereof is permitted only under the provisions of the German Copyright Law of September 9, 1965, in its current version, and permission for use must always be obtained from Springer-Verlag. Violations are liable for prosecution under the German Copyright Law.

Springer is a part of Springer Science+Business Media

springer.com

© Springer Berlin · Heidelberg 2006

Printed in Germany

The use of general descriptive names, registered names, trademarks, etc. in this publication does not imply, even in the absence of a specific statement, that such names are exempt from the relevant protective laws and regulations and therefore free for general use.

Editor: Gabriele M. Schröder, Heidelberg, Germany

Desk Editor: Irmela Bohn, Heidelberg, Germany

Production: LE-TeX Jelonek, Schmidt & Vöckler GbR, Leipzig, Germany

Cover: Frido Steinen-Broo, eStudio Calamar, Spain

Typesetting: K + V Fotosatz GmbH, Beerfelden, Germany

Printed on acid-free paper

24/3100 YL/Wa 5 4 3 2 1 0

Preface

Upon opening this reference book you might be surprised to see that enough classifications and scores concerning the shoulder joint exist to fill an entire compendium – and not even all of them are included. This multitude alone illustrates why this book needed to be published. The intention of the editors is to provide all those who are scientifically and clinically engaged with the shoulder joint with a collection of original research and an easy way to find desired information.

Classifications are categories that serve as a basis for establishing the degree of severity and thus a prognosis. Treatment options and procedures can then be planned. The task of scores is to evaluate the pursued therapy and measure the outcome. Together with evidence-based medicine, classifications and scores are measurable and reproducible tools that help validate the quality of our medical work.

With regards to the content, we strictly followed the original articles and original illustrations and did not add our own rating, interpretation or evaluation. Only illustrations of bad quality were revised. The classifications are topographically arranged. When important, we also added classifications outside the border areas, i.e. in the field of radiology. The criteria for inclusion in this compendium were publications of explorative or representative studies and their clinical relevance.

We thank all authors for giving their permission to publish the classifications and scores and are very pleased about their positive consent. We appreciate any suggestions, ideas and criticism and ask for understanding from all those whose classifications could not be included in this first edition.

We express our thanks to Springer and especially to Ms. Gabriele Schröder and Ms. Irmela Bohn for their support of our project and the layout of the manuscript.

We hope this compendium will be of great use and lead to further studies.

Heidelberg, April 2006

On behalf of the editors:

Prof. Dr. med. habil. Peter Habermeyer

Contents

- 1 Acromion/Spina Scapulae 1**
 - 1.1 The morphology of the acromion according to Bigliani 1**
 - 1.2 Classification of the acromial morphology on sagittal oblique MRI according to Epstein 2**
 - 1.3 Types of os acromiale according to Liberson 4**
 - 1.4 Types of scapular notch according to Rengachary et al. 5**

- 2 Subacromial space 7**
 - 2.1 Stages of outlet impingement according to Neer 7**
 - 2.2 Stages of impingement in athletes according to Jobe 8**

- 3 Classifications of calcifying tendinitis of rotator cuff 9**
 - 3.1 Stages of calcifying tendinitis according to Uhthoff 9**
 - 3.2 Radiologic staging of calcifying tendinitis of the shoulder joint according to Gärtner and Heyer 11**
 - 3.3 Radiological classification of calcific deposit according to Bosworth 12**
 - 3.4 Classification of radiological morphology of calcifying tendinitis of the rotator cuff according to Molé et al. 12**

- 4 Classifications of frozen shoulder 13**
 - 4.1 Classification of frozen shoulder according to Lundberg 13**
 - 4.2 Stages of frozen shoulder according to Reeves 13**
 - 4.3 Arthroscopic stages of adhesive capsulitis according to Neviaser 14**

- 5 Classifications of rotator cuff 17**
 - 5.1 Classifications of rotator cuff tears according to Patte 17**
 - 5.2 Topography of rotator cuff tear in the sagittal plane according to Habermeyer 19**

- 5.3 Arthroscopic classification of partial-thickness rotator cuff tears according to Ellman 20
- 5.4 Arthroscopic classification of rotator cuff lesions according to Snyder (the Southern California Orthopedic Institute (SCOI) rotator cuff classification system) 22
- 5.5 Classification of complete rotator cuff tears according to Cofield 23
- 5.6 Classification of complete rotator cuff tears according to Bateman 23
- 5.7 Classification of the extent of rotator cuff tears according to Patte 24
- 5.8 Patterns of full-thickness rotator cuff tears according to Ellman and Gartsman 26
- 5.9 Classification of subscapularis tendon tears according to Fox and Romeo 28
- 5.10 Classification of tendon retraction in the frontal plane according to Patte 29
- 5.11 Classification of supraspinatus muscle atrophy in MRI according to Thomazeau 29
- 5.12 Classification of supraspinatus muscle atrophy in MRI according to Zanetti 31
- 5.13 Classification of fatty muscle degeneration in cuff ruptures using CT-scan according to Goutallier et al. [49] 33

- 6 **Classifications of pathology of long head of the biceps tendon** 35
 - 6.1 Variants of the origin of the long head of the biceps from the scapula and glenoid labrum according to Vangsness et al. 35
 - 6.2 Classification of SLAP-Lesions (superior labrum, anterior to posterior lesion) according to Snyder 36
 - 6.3 Classification of SLAP lesion according to Maffet et al. 38
 - 6.4 Subtypes of SLAP II lesions according to Morgan 39
 - 6.5 Topographic classification of LHB-lesions 40
 - 6.6 Classification of biceps tendon disorders according to Yamaguchi and Bindra 41

-
- 6.7 Histological changes of the long head of the biceps tendon according to Murthi et al. 42
 - 6.8 Classification of subluxation of the long head of the biceps tendon according to Walch 42
 - 6.9 Classification of dislocation of the long head of the biceps tendon according to Walch 43
 - 6.10 Classification of “hidden” rotator interval lesions according to Bennett 45
 - 6.11 Classification of pulley lesions according to Habermeyer et al. 46
- 7 Classifications of instability 49**
- 7.1 Classification of scapular dyskinesis according to Kibler and McMullen 49
 - 7.2 Types of variable topographical relationship of the glenohumeral ligaments to the synovial recesses (types of arrangement of the synovial recesses) according to DePalma 50
 - 7.3 Variations of glenohumeral ligaments according to Gohlke et al. 53
 - 7.4 Anatomical variations of the glenohumeral ligaments according to Morgan et al. 56
 - 7.5 Classification of instability according to Silliman and Hawkins 57
 - 7.6 Grading of glenohumeral translation according to Hawkins et al. 58
 - 7.7 Classification of recurrent instability according to Neer and Foster 59
 - 7.8 Classification of shoulder instability according to Matsen et al. 60
 - 7.9 Classification of shoulder instability according to Gerber et al. 61
 - 7.10 Classification of shoulder instability according to Bayley et al. 71
 - 7.11 Types of lesions of anterior inferior shoulder instability according to Habermeyer 73

- 7.12 Classification of posterior shoulder instability according to Ramsey and Klimkiewicz 76
- 7.13 Classification of glenoid rim lesions according to Bigliani et al. 79
- 7.14 Arthroscopic classification of Hill-Sachs lesions according to Calandra et al. 79
- 7.15 Classification of significant Hill-Sachs lesions according to Burkhart and De Beer 80
- 7.16 Stages of evolution of lesions of the labrum-ligament complex in posttraumatic anterior shoulder instability according to Gleyze and Habermeyer 82
- 7.17 Classification shoulder injury/dysfunction (impingement and instability) in the overhand or throwing athlete according to Kvitne et al. and Jobe et al. 84
- 7.18 Arthroscopic classification of labro-ligamentous lesions associated with traumatic anterior chronic instability according to Boileau et al. 87

- 8 **Acromioclavicular joint** 91
 - 8.1 State of AC-joint space and SC-joint space according to De Palma 91
 - 8.2 Classification of AC-joint dislocation according to Tossy et al. 93
 - 8.3 Classification of AC-joint injuries according to Allman 94
 - 8.4 Classification of AC-joint injury according to Rockwood et al. 96

- 9 **Sternoclavicular joint** 103
 - 9.1 Classification of SC-joint injury according to Allman 103

- 10 **Classifications of fractures of the clavicle** 105
 - 10.1 Classification of fractures of the clavicle according to Allman 105
 - 10.2 Classification of fractures of the clavicle according to Neer 106
 - 10.3 Classification of fractures of the clavicle according to Jäger and Breitner 109

-
- 10.4 Classification of clavicular fractures according to Craig 111
 - 10.5 Classification of fractures of the clavicle in adult according to Robinson 114
 - 10.6 Classification of nonunion of clavicular fractures according to Neer 117
 - 10.7 Classification of epiphyseal fractures of the proximal end of the clavicle according to Rockwood and Wirth 117

 - 11 **Classifications of proximal humeral fractures** 119
 - 11.1 Classification of proximal humeral fractures according to Neer 119
 - 11.2 AO-Classification of proximal humeral fractures 131
 - 11.3 Classification of proximal humeral fractures according to Habermeyer 138
 - 11.4 Surgical classification of sequelae of proximal humerus fracture according to Boileau et al. 140
 - 11.5 Classification of periprosthetic humeral fractures according to Wright and Cofield 142

 - 12 **Classifications of scapular fractures** 143
 - 12.1 Classification of scapula fractures according to Euler and Rüedi 143
 - 12.2 Classification of scapular fractures according to DeCloux and Lemerle 146
 - 12.3 Classification of scapular fractures according to Zdravkovic and Damholt 146
 - 12.4 Classification of intraarticular scapular fractures according to Ideberg et al. 147
 - 12.5 Classification of fractures of the glenoid cavity according to Goss 148
 - 12.6 Classification of glenoid neck fractures according to Goss 150
 - 12.7 Types of traumatic ring/strut disruption of the superior shoulder suspensory complex according to Goss 151

 - 13 **Classifications of osteoarthritis of the shoulder** 155
 - 13.1 Grading of chondromalacia according to Outerbridge 155

- 13.2** Classification of glenoid morphology in primary glenohumeral osteoarthritis according to Walch et al. 155
- 13.3** Assessment of humeral head subluxation according to Walch et al. 157
- 13.4** Classification of vertical glenoid morphology according to Habermeyer 157
- 13.5** Classification of osteoarthritis with massive rotator cuff tears according to Favard et al. 159
- 13.6** Classification of cuff tear arthropathy according to Seebauer et al. 160
- 13.7** Classification of cuff tear arthropathy according to Hamada et al. 161
- 13.8** Classification of glenoid erosion in glenohumeral osteoarthritis with massive rupture of the cuff according to Sirveaux et al. 162
- 13.9** Radiographic classification of dislocation arthropathy of the shoulder according to Samilson and Prieto 163

- 14** **Classifications of necrosis of the humeral head** 165
- 14.1** Classification of osteonecrosis of bone according to Cruess 165
- 14.2** Classification of avascular necrosis of the humeral head according to Neer 167
- 14.3** Classification of the extent of osteonecrosis of the humeral head according to Hattrup and Cofield 169

- 15** **Classifications for rheumatoid arthritis** 171
- 15.1** Variations in involvement in rheumatoid arthritis 171
- 15.2** Staging of glenoid wear in rheumatoid arthritis according to Lévigne and Franceschi 173
- 15.3** Staging of humeral head wear in rheumatoid arthritis according to Lévigne and Franceschi 173
- 15.4** Radiological classification of rheumatoid arthritis according to Lévigne and Franceschi 174
- 15.5** Radiologic classification of rheumatoid arthritis according to Larsen, Dale, Eek 176

-
- 16 Classification of septic arthritis** 179
 - 16.1** Stages of joint infection according to Gächter and Stutz et al. 179
 - 16.2** Proposed classification system of septic arthritis according to Tan et al. 179

 - 17 Classification of neoplasms** 183
 - 17.1** The system for the surgical staging of musculoskeletal sarcoma according to Enneking et al. 183

 - 18 Classifications in shoulder arthroplasty** 191
 - 18.1** Radiographic assessment of radiolucent lines of the humeral component according to Sperling et al. 191
 - 18.2** Radiographic assessment of radiolucent lines of the glenoid component according to Sperling et al. 192
 - 18.3** Radiographic assessment of radiolucent lines of the cemented glenoid component according to Molé et al. 193
 - 18.4** Radiographic assessment of radiolucent lines of the glenoid component according to Franklin et al. 194
 - 18.5** Radiographic assessment of radiolucent lines of the cemented glenoid component according to Wilde et al. 194
 - 18.6** Classification of bone defects of the scapular notch for inverse shoulder arthroplasty according to Sirveaux 195
 - 18.7** Classification of glenoid bone deficiencies after glenoid component removal according to Antuna et al. 195
 - 18.8** Classification of heterotopic bone formation following total shoulder arthroplasty according to Kjaersgaard-Andersen et al. 196

 - 19 Scores** 199
 - 19.1** Constant-Murley Score 199
 - 19.1.1** Normative age- and sex-specific Constant Score according to Gerber et al. 202
 - 19.1.2** Normative age- and gender-related Constant Score according to Katolik et al. 204

- 19.1.3** Valuation of the Constant Score according to Boehm 204
- 19.2** Questionnaire based on the Constant-Murley Score for patient self-evaluation of shoulder function according to Boehm 205
- 19.3** UCLA shoulder rating 213
- 19.4** DASH (Disabilities of the Arm, Shoulder and Hand) Questionnaires 214
 - 19.4.1** The DASH Questionnaire 220
 - 19.4.2** The Quick DASH Questionnaire 220
 - 19.4.3** Scoring the DASH 220
- 19.5** The ASES (American Shoulder and Elbow Surgeons) Score 222
- 19.6** Simple shoulder test 228
- 19.7** Short form 36 (SF-36) 233
- 19.8** VAS 248
- 19.9** Shoulder pain and disability index (SPADI) 249
- 19.10** Self-administered questionnaire for assessment of symptoms and function of the shoulder according to L'Insalata et al. 252
- 19.11** "Oxford" questionnaire on the perceptions of patients about shoulder surgery 259
- 19.12** Oxford shoulder instability questionnaire 262
- 19.13** Rowe Score 265
- 19.14** The modified Rowe Score according to Jobe et al. 266
- 19.15** The Western Ontario shoulder instability index (WOSI) 267
- 19.16** The Walch-Duplay Score for instability of the shoulder 270
- 19.17** The Western Ontario rotator cuff index (WORC) 270
- 19.18** The rotator cuff quality-of-life measure (RC-QOL) 274
- 19.19** The Western Ontario osteoarthritis of the shoulder index (WOOS) 278

References 283

Sachverzeichnis 293



Special note

The following footnotes apply to the entire text:

- * Validated only by an explorative study
- ** Validated by an explorative and a representative study

1.1 The morphology of the acromion according to Bigliani [1, 9, 11]*

One hundred and forty shoulders in 71 cadavers (52% male, 48% female) were studied to determine the shape of the acromion and its relationship to full-thickness tears in the rotator cuff. The average age of the cadavers was 74.4 years (range, 51–97 years).

The overall incidence of full-thickness rotator cuff tears in this elderly population was 34%. In this series 24% of rotator cuffs had full-thickness rotator cuff tears.

Lateral radiographs were performed in the longitudinal axis so that the anterior slope of the acromion could be measured.

Three distinct types of acromions were identified (Fig. 1 a–c):

- **Type I: flat (17.1%)**
Angle of anterior slope: 13.1°
Full-thickness rotator cuff tears: 3.0%
- **Type II: curved (42.9%)**
Angle of anterior slope: 29.9°
Full-thickness rotator cuff tears: 24.2%
- **Type III: hooked (39.3%)**
Angle of anterior slope: 26.9°
Full-thickness rotator cuff tears: 69.8%

In addition, anterior acromial spur formations were noted in 14.2% of the series overall, but 70% were present in patients with rotator cuff tears. It is important to distinguish between spurs, which are probably acquired, and variations in the native architecture of the acromion.

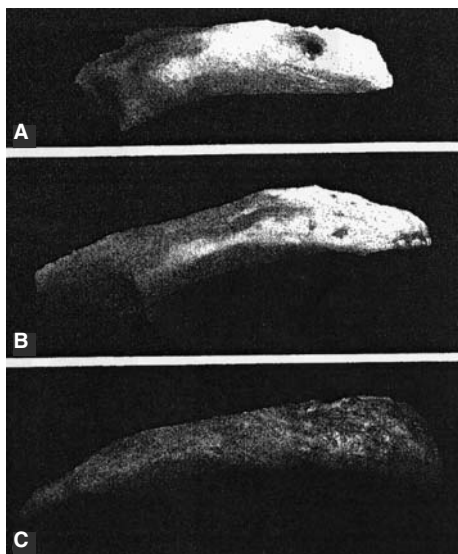


Fig. 1. A Type-I acromion: flat.
B Type-II acromion: curved.
C Type-III acromion: hooked

1.2 Classification of the acromial morphology on sagittal oblique MRI according to Epstein [36]*

Acromion shape was classified as (Fig. 2):

- Type 1: flat
- Type 2: smoothly curved
- Type 3: hooked

Sagittal oblique T2-weighted or fast spin-echo images were obtained at a 90° angle to the long axis of the supraspinatus tendon as determined with an axial localizing image.

The acromions were classified according to their appearance on the image obtained just lateral to the acromioclavicular joint. This image consistently demonstrated the greatest longitudinal length of the acromion, and was at or just beyond the tip of the coracoid. Occasionally, it was difficult to differentiate between type 2 and type 3 acromions. If the apex of the curve or hook was within the middle one-third of the acromion, it was considered a type 2 acromion. If the apex of the curve

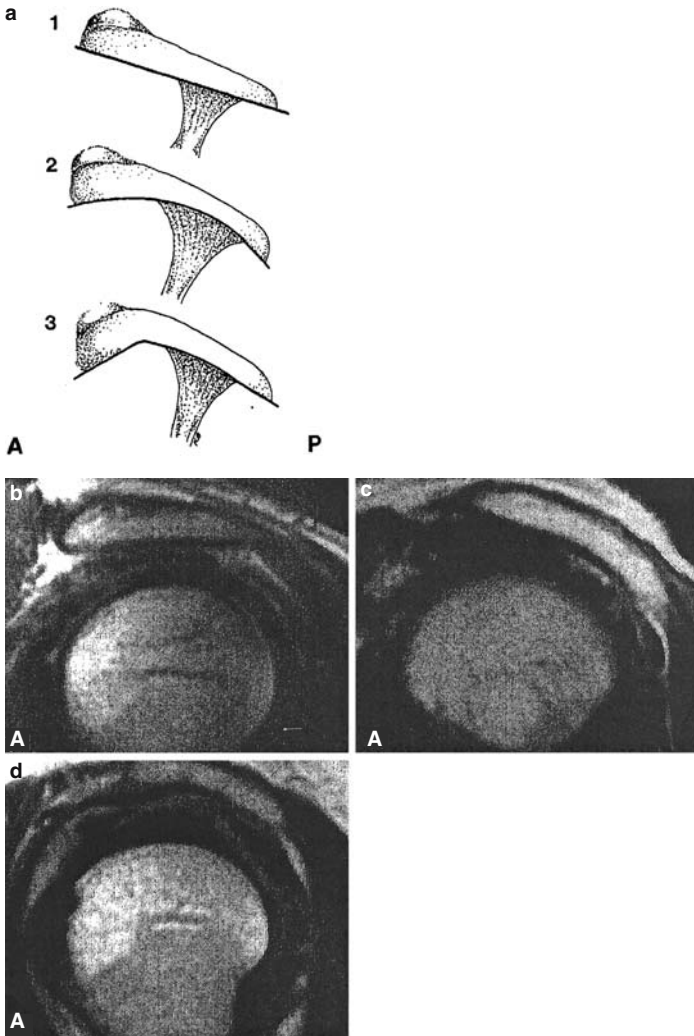


Fig. 2. a Classification of acromial shape in MRI. Illustration depicts the three acromial shapes: flat (type 1); smoothly curved (type 2); and hooked (type 3). b Sagittal oblique MRI demonstrates a flat (type-1) acromion. c Sagittal oblique MRI demonstrates a smoothly curved (type-2) acromion. d Sagittal oblique MRI demonstrates a hooked (type-3) acromion. A anterior, P posterior. (From [36])

or hook was in the anterior one-third of the acromion, it was classified as a type 3 acromion.

1.3 Types of os acromiale according to Liberson [77, 90]*

Liberson [77] reviewed the roentgenograms of 1800 shoulder girdles, chosen at random, and found 21 typical and 4 atypical cases of os acromiale, for an incidence of os acromiale of 1.4%. The lesion is bilateral in 62% of patients.

Definition of os acromiale: when there is a failure of union of any one of the ossifications centres to its neighbour, the resulting separate bone is an os acromiale.

Four different types of unfused acromia were described (Fig. 3):

- The most common nonunion is between the meso-acromion and the meta-acromion (typical os acromiale)
- Nonunion between the pre-acromion and meso-acromion (atypical)
- Nonunion between pre-acromion and meso-acromion as well as meso-acromion and meta-acromion (atypical)
- Nonunion between pre-acromion and meso-acromion, and pre-acromion and meso-acromion as well as meta-acromion and basi-acromion (atypical)

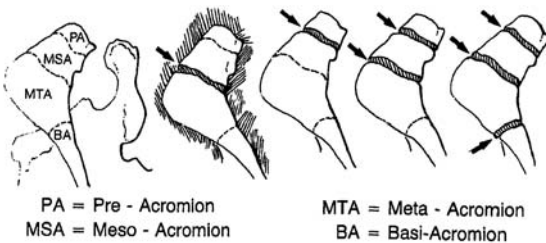


Fig. 3. Types of os acromiale according to Liberson [77, 90]

1.4 Types of scapular notch according to Rengachary et al. [110]*

Rengachary et al. [110] observed six basic types of suprascapular notch in 211 cadaveric adult scapulae (Fig. 4):

- **Type I (no notch):** The entire superior border of the scapula showed a wide depression from the medial superior angle of the scapula to the base of the coracoid process.
Relative frequency 8%.
- **Type II:** This type showed a wide, **blunted “v”-shaped notch** occupying nearly a third of the superior border of the scapula. The widest point in the notch was along the superior border of the scapula.
Relative frequency 31%.
- **Type III:** The notch was symmetrical and **“U”-shaped** with nearly parallel lateral margins.
Relative frequency 48%.

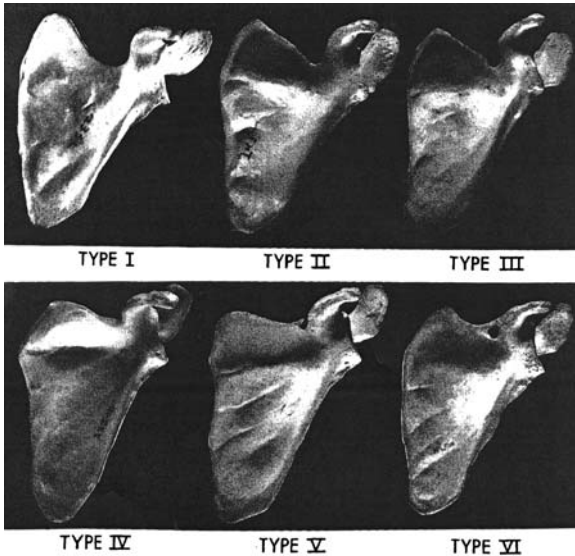


Fig. 4. Types of scapular notch

- **Type IV:** The notch was very **small** and “**v**”-**shaped**. Frequently a shallow groove representing the bony impression by the suprascapular nerve was visible adjacent to the notch.
Relative frequency 3%.
- **Type V:** This type was very similar to Type III (**U-shaped**), with **partial ossification of the medial part of the ligament** resulting in a notch with the minimal diameter along the superior border of the scapula.
Relative frequency 6%.
- **Type VI:** The **ligament was completely ossified**, resulting in a **bony foramen** of variable size located just inferomedial to the base of the coracoid process.
Relative frequency 4%.

Although the majority of the scapulae were easily classified into the six types defined above, occasional transitional types did occur. In addition, there were many *minor variations* within a given type.

Transitions tended to occur more frequently between Types II, III and IV.

2.1 Stages of outlet impingement according to Neer [97] *

Stage I: edema and hemorrhage

- Characteristically caused by overuse with the arm above the horizontal
- Typical age: < 25 years
- Differential diagnosis: subluxation, AC-arthritis
- Clinical course: reversible
- Treatment: conservative

Stage II: fibrosis and tendinitis

- Typical age: 25–40 years
- Differential diagnosis: frozen shoulder, calcifying tendinitis
- Clinical course: recurrent pain with activity
- Treatment: consider bursectomy; CA ligament division

Stage III: bone spurs and tendon rupture

- Typical age: > 40 years
- Differential diagnosis: cervical radiculitis; neoplasm
- Clinical course: progressive disability
- Treatment: anterior acromioplasty, rotator cuff repair

2.2 Stages of impingement in athletes according to Jobe [65]

- **Stage 1:**
Tendinitis, usually of the supraspinatus or the long head of the biceps
- **Stage 2:**
Fibre dissociation in the tendon
- **Stage 3:**
Rotator cuff tear less than 1 cm
- **Stage 4:**
Rotator cuff tear 1 cm and more

3.1 Stages of calcifying tendinitis according to Uthoff [130]*

The authors discriminate between degenerative calcification and calcifying tendinitis. The incidence of calcification increases with age in cases of degenerative calcification, whereas it peaks during the fifth decade in cases of calcifying tendinitis. Moreover, degenerative diseases never exhibit a potential for self-healing. Furthermore, the histologic and ultrastructural features of degenerative calcification and calcifying tendinitis are quite different.

The authors proposed that the evolution of the disease can be divided into three distinct stages (Fig. 5):

1. Precalcific stage:

The site of predilection for calcification undergoes fibrocartilaginous transformation. This metaplasia of tendocytes into chondrocytes is accompanied by metachromasia, indicative of the elaboration of proteoglycan.

2. Calcific stage:

The calcific stage is subdivided into

– *The formative phase*

During the formative phase, calcium crystals are deposited primarily in matrix vesicles, which coalesce to form large foci of calcification.

If the patient undergoes surgery during this stage, the deposit appears chalklike and must be scooped out. The fibrocartilaginous septa between the foci of calcification are generally devoid of vascular channels. They do not consistently stain positively for type II collagen, which is known to be a component of fibrocartilage. These fibrocartilaginous septa are gradually eroded by enlarging deposits.

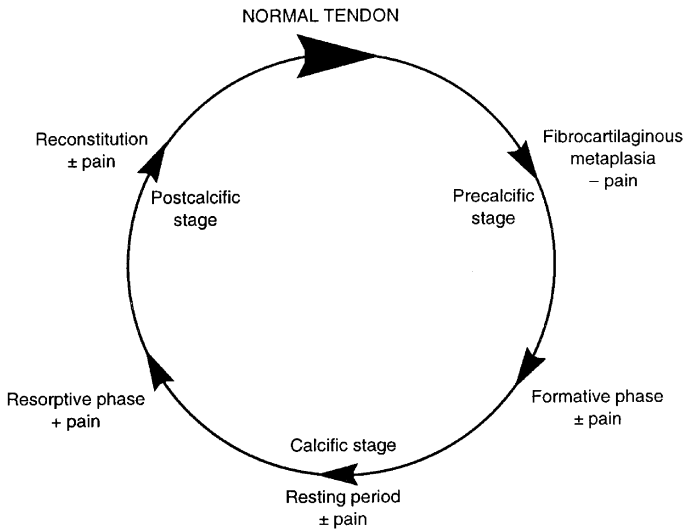


Fig. 5. The progressive stages of calcifying tendinitis

Pain is chronic or even absent.

Radiologically, the deposit is dense, well defined, and homogenous.

– *The resting phase*

During the resting phase, fibrocollagenous tissue borders the foci of calcification. The presence of this tissue indicates that deposition of calcium at that site is terminated.

– *The resorptive phase*

During the resorptive phase, after a variable period of inactivity of the disease process, spontaneous resorption of calcium is heralded by the appearance of thin-walled vascular channels at the periphery of the deposit. Soon thereafter, the deposit is surrounded by macrophages and multinucleated giant cells that phagocytose and remove the calcium. If an operation is performed during this stage, the calcific deposit contains a thick, creamy or toothpaste-like material that is often under pressure.

Characterized by acute pain.

Radiologically, the deposit is fluffy, cloudlike, ill-defined, and irregular in density.

Rupture of the calcific deposit into the bursa can occur only during the resorptive phase, because of the toothpaste-like or creamy consistency. Radiographs show a crescentic radiodensity overlying the deposit.

3. Postcalcific stage:

Simultaneously with the resorption of calcium, granulation tissue containing young fibroblasts and new vascular channels begins to remodel the space occupied by calcium. These sites stain positively for type III collagen. As the scar matures, fibroblasts and collagen eventually align along the longitudinal axis of the tendon. During this remodelling process, type III collagen is replaced by type I collagen.

It is important to note that not all foci of calcification in a given patient are in the same phase of evolution. In general, however, one phase predominates. The morphologic aspect of an individual deposit can vary from fibrocartilagenous tissue to foreign body-like granulomatous tissue.

3.2 Radiologic staging of calcifying tendinitis of the shoulder joint according to Gärtner and Heyer [43]* (Fig. 6)

Type I

- The calcific deposit is clearly circumscribed and has a dense appearance
- Formative phase

Type II: hybrid type

- Clearly circumscribed and translucent, cloudy and dense
- Assessment of stage is possible by performing a second X-ray examination after 6 to 12 weeks

Type III

- Cloudy and translucent appearance without clear circumscription
- Resorptive phase

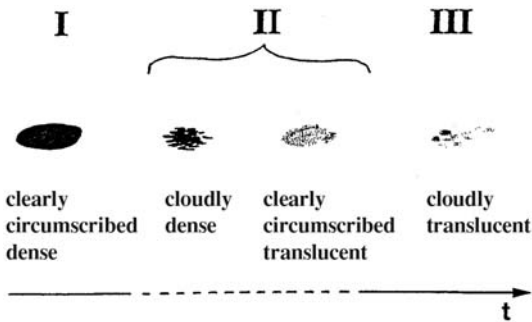


Fig. 6. Radiological appearance of calcific deposits of spontaneous process of calcifying tendinitis

3.3 Radiological classification of calcific deposit according to Bosworth [16]*

- **Large:** deposits 1.5 cm or longer in their greatest profile dimension
- **Medium:** all others except:
- **Tiny:** those barely perceptible on fluoroscopic examination

3.4. Classification of radiological morphology of calcifying tendinitis of the rotator cuff according to Molé et al. [85]

- **Type A** calcification: dense, homogeneous, clear contours
- **Type B** calcification: dense, separated (split), clear contours
- **Type C** calcification: inhomogeneous, serrated contours
- **Type D** calcification: dystrophic calcification of the insertion (dense, small sized, in continuity with tuberosity)

4.1 Classification of frozen shoulder according to Lundberg [81]

A) Primary frozen shoulder

Primary frozen shoulders were defined as follows:

- a) The total elevation in the shoulder joint restricted to 135° or less.
- b) The restriction of motion localized to the humero-scapular joint.
- c) No findings in the case history or in the clinical or radiological examination which could explain the decrease of the range of motion; by the latter criterion cases with post-traumatic conditions, rheumatoid arthritis, osteoarthritis, hemiplegia and other more obvious changes, were excluded.

B) Secondary frozen shoulder

The range of motion was similarly decreased but following a traumatic lesion. The associated injuries were soft tissue injury to the shoulder region, intra- and juxtaarticular fractures and other fractures of the upper limb.

4.2 Stages of frozen shoulder according to Reeves [109]

Three consecutive stages:

■ Stage 1: pain

Duration: 10 to 36 weeks

No difference between men and women

No difference between affected dominant and nondominant shoulder

No correlation with age

In the early stages there is a full range of movement under an anaesthetic

■ Stage 2: stiffness

Duration: 4 to 12 months

Without improvement of movement

■ Stage 3: recovery

Duration: 5 months to 2 years 2 months

Spontaneous recovery of movement

First a gradual regaining of external rotation; then a gradual return of abduction and internal rotation

The short recovery period was associated with a short previous painful period, and a long recovery period was often associated with a prolongation of the painful period.

The stiffness stage was usually related to the duration of the recovery stage: the longer the stiffness stage is, the longer is the recovery stage.

4.3 Arthroscopic stages of adhesive capsulitis according to Neviaser [103]

Adhesive capsulitis is a specific entity consisting of four identifiable stages by arthroscopy.

- In **stage 1**, patients usually present with signs and symptoms of the impingement syndrome. Their motion usually is restricted very little if at all, and that restriction fools the physician into believing this loss of motion and increased pain are due to a rotator cuff tendinitis (the impingement sign). The usual treatment for the impingement syndrome fails, often to the point that decompression of the acromial arch is contemplated. If the decompression is carried out, the postoperative course will be severely drawn out, with the capsular structures undergoing all the stages of adhesive capsulitis superimposed upon a postoperative course of an acromial arc decompression. Arthroscopy prior to decompression surgery would show an erythematous fibrinous pannus over the synovium best seen in and around the dependent fold.
- In **stage 2**, the synovium is red, angry, and thickened, and one can actually visualize adhesions growing across the dependent fold onto

the humeral head. There is complete loss of the normal interval between the humeral head and glenoid as well as the space between the humeral head and biceps tendon. The most impressive finding on physical examination is the severe loss of motion in all planes with pain in all ranges of motion.

- In **stage 3**, there is only a pink synovitis that is not as abundant as in stage 2, but the dependent fold is now noted to be at least half its original size. The humeral head remains solidly pressed against the glenoid and bicipital tendon, even with traction.
- In **stage 4**, no more synovitis is present; however, the dependent fold is severely contracted and motion is at its worst. The humeral head remains compressed against the glenoid and the biceps tendon as in stage 2 and 3.

5.1 Classifications of rotator cuff tears according to Patte [107]

- 1) Extent of the tear (see Sect. 5.6)
- 2) Topography of the tear in the sagittal plane
- 3) Topography of the tear in the frontal plane
- 4) Trophic quality of the muscle of the torn tendon
- 5) State of the long head of the biceps

Topography of rotator cuff tear in sagittal plane according to Patte [107] (Fig. 7)

- **Segment 1:** subscapularis tear
- **Segment 2:** coracohumeral ligament tear
- **Segment 3:** isolated supraspinatus tear
- **Segment 4:** tear of entire supraspinatus and one-half of infraspinatus
- **Segment 5:** tear of supraspinatus and infraspinatus
- **Segment 6:** tear of subscapularis, supraspinatus, and infraspinatus

This assessment is necessary for anatomic-clinical correlations and for the proper choice of surgical approach and technique. Anteriorly situated defects are more painful, whereas posterior lesions interfere more with function. In a sagittal section viewed from the subscapularis to the infraspinatus, several segments can be distinguished.

Segment 1. Isolated subscapularis tears are seldom exclusively involved in degenerative tears. These tears in general are due to traumatic avulsions often associated with a medial dislocation of the LHB.

Segment 2. Isolate coracohumeral ligament tears are traumatic in nature and do not contribute to the pathology of the cuff.

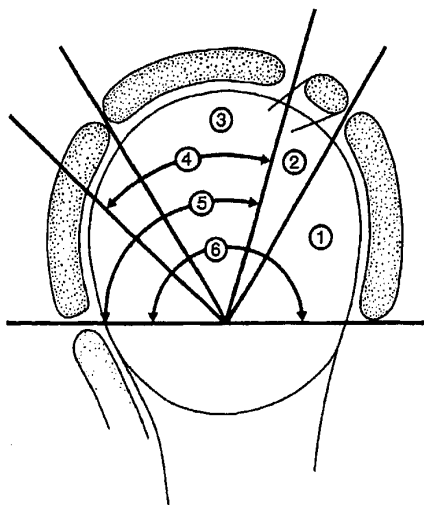


Fig. 7. Topography of tears in the sagittal plane. Location and extent of tears determine their division into six segments: anterosuperior lesions (segments 1–3), superior lesions (segments 2 and 3), posteriosuperior lesions (segments 4 and 5), and total-cuff lesions (segment 6)

Segment 3. Isolated supraspinatus tears include only the supraspinatus, but other segments can be involved simultaneously. When associated with a tear of Segment 2, a Segment 3 tear constitutes a superior defect. If Segment 1 is also involved, then the lesion is an anterosuperior defect.

Segments 4 and 5. Segment 4 (supraspinatus and the upper one-half of the infraspinatus) and Segment 5 (supraspinatus and the entire infraspinatus) tears merit special attention, given the inherent difficulties of repair.

Segment 6. Total-cuff tears including the subscapularis, supraspinatus, and infraspinatus. Secondary OA was most common among these patients.

5.2 Topography of rotator cuff tear in the sagittal plane according to Habermeyer [51, 53] (Fig. 8)

- **Sector A:** lesions localized anteriorly
Sector A contains the subscapularis tendon, rotator interval and the long head of the biceps tendon
- **Sector B:** lesions localized central superiorly
Sector B circumscribes the at the apex located central area with the supraspinatus tendon
- **Sector C:** lesions localized posteriorly
Sector C localized the posteriorly located lesions of the infraspinatus and teres minor tendon

The extension of the line of spina scapulae separates sector B from sector C.

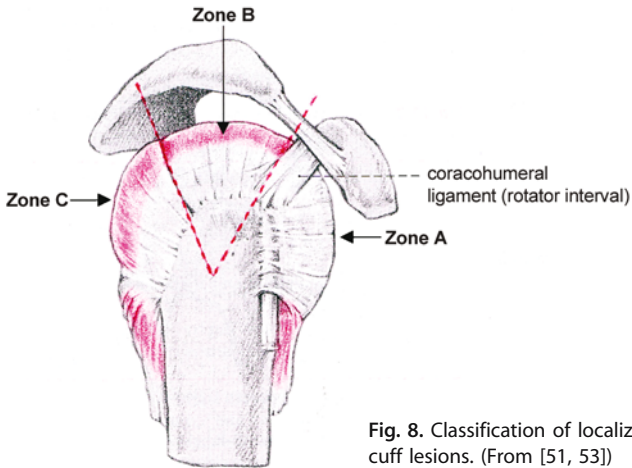


Fig. 8. Classification of localization of rotator cuff lesions. (From [51, 53])

5.3 Arthroscopic classification of partial-thickness rotator cuff tears according to Ellman [32]

The author stated that any tear, whether partial or complete, should be classified as Stage III (impingement according to Neer [97]). The following subclassification of Stage III is proposed to include both partial- and full-thickness rotator cuff tears (Table 1).

The *classification of partial-thickness tears* (Fig. 9 [34]) indicates which surface is involved and grades the severity of the tear according to depth. The normal cuff is considered to be 10–12-mm thick.

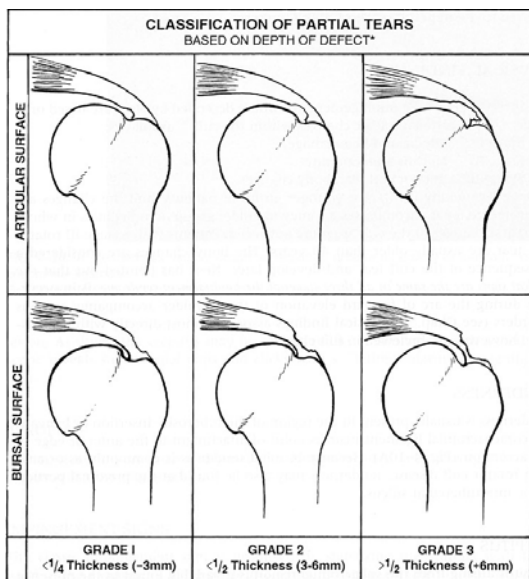
- A **Grade 1** partial tear (less than 3-mm deep) is relatively minor, but definite disruption of the tendinous fibres can be identified. Superficial fraying of the articular capsule does not constitute a cuff tear.
- **Grade 2** lesions (3–6-mm deep) extend well into the substance of the cuff but do not exceed one-half of the thickness of the tendon.
- **Grade 3** lesions are more than 6 mm in depth and are significant disruptions of more than one-half the substance of the cuff; continuity appears tenuous.

A small arthroscopic probe with a 3-mm bent arm or a suction shaver of known diameter can be used to measure the tear. In addition to depth, the base of the defect and its width should be measured. This information clearly defines the extent of the tear.

Table 1. Subclassification of stage-III rotator cuff tears

Location	Grade	Area of defect
<i>Partial-thickness tear (P)^a</i>		
A. Articular surface	1: <3 mm deep	Base of tear × maximum retraction = mm ²
B. Bursal surface	2: 3–6 mm deep	
C. Interstitial	3: >6 mm deep	
<i>Full-thickness tear (F)</i>		
A. Supraspinatus	1: Small, <2 cm	Base of tear × maximum retraction = cm ²
B. Infraspinatus	2: Large, 2–4 cm	
C. Teres minor	3: Massive, >5 cm	
D. Subscapularis	4: Cuff arthropathy	

^a Torn muscle(s)



*Indicate **AREA OF DEFECT**: Base of tear \times maximum retraction = mm²

Fig. 9. Ellman classification of partial-thickness rotator cuff tears

Full-thickness tears are described in the traditional fashion with minor variations. Designated grades can be substituted for the adjectives *small* and *large*. A **fourth grade** is added to include cuff arthropathy. As defined by Neer, this includes a massive tear articular irregularity with collapse of the humeral head, chronic synovitis and capsular laxity. Estimates of the total area of defect measured in square millimeters or centimeters are obtained by multiplying the length of the base of the tear by the distance of maximum retraction. Use of the classification defines the location and extent of rotator cuff lesions and facilitates comparison of findings among various studies.

5.4 Arthroscopic classification of rotator cuff lesions according to Snyder (the Southern California Orthopedic Institute (SCOI) rotator cuff classification system) [121]

The Southern California Orthopedic Institute rotator cuff classification system is a simple, descriptive scheme that uses letters and numbers to designate the pathologic conditions of the tendon. The capital letter indicates the side of the cuff where the tear is located: A for articular-side partial tears, B for bursal-side partial injuries, and C for complete-thickness or trans-tendon damage. The degree of tendon damage is classified using a numeric designation of 0 to 4.

Location of tears

- A Articular surface
- B Bursal surface
- C Complete tear, connecting A and B sides

Severity of tear (A and B partial tears)

- 0 Normal cuff, with smooth coverings of synovium and bursa
- I Minimal, superficial bursal or synovial *irritation* or slight capsular fraying in a small, localized area; usually <1 cm
- II Actually *fraying* and failure of some rotator cuff fibres in addition to synovial, bursal, or capsular injury; usually <2 cm
- III More severe rotator cuff injury, including fraying and *fragmentation* of tendon fibres, often involving the whole surface of a cuff tendon (most often the supraspinatus); usually <3 cm
- IV Very severe partial rotator cuff tear that usually contains, in addition to fraying and fragmentation of tendon tissue, a sizable *flap* tear and often encompasses more than a single tendon

(A partial articular supraspinatus tendon avulsion (*PASTA*) is an A-III or A-IV tear.)

Classification of complete (C) rotator cuff tears

- CI A small, complete tear, such as a puncture wound
- CII A moderate tear (usually <2 cm) that still encompasses only one of the rotator cuff tendons with no retraction of the torn ends
- CIII A large, complete tear involving an entire tendon with minimal retraction of the torn edge; usually 3 to 4 cm
- CIV A massive rotator cuff tear involving two or more rotator cuff tendons, frequently with associated retraction and scarring of the remaining tendon ends and often L-shaped tear. The CIV classification can also be modified with the term *irreparable*, indicating that there is no possibility of direct repair

5.5 Classification of complete rotator cuff tears according to Cofield [21]

- Small tears represented fissuring or an isolated avulsion of the supraspinatus
- Medium tears were less than 3 cm in the longest diameter
- Large tears were 3 to 5 cm in diameter
- Massive tears were greater than 5 cm in diameter

5.6 Classification of complete rotator cuff tears according to Bateman [7]

- **Grade 1:** cuff tears of 1 cm or less measured in the longest diameter after debriding of the avascular edges
- **Grade 2:** cuff tears of 1 to 3 cm in diameter after debridement of the avascular edges
- **Grade 3:** cuff tears of 5 cm or less
- **Grade 4:** global cuff tears with little or no cuff left

5.7 Classification of the extent of rotator cuff tears according to Patte [107]

The extent of the lesion is measured in centimetres at the level of the bony insertion. The tears are divided into three groups: *small*, *intermediate*, and *large*. A fourth group, characterized by secondary osteoarthritic (OA) changes in the humeral head (which is usually subluxed), deserves a separate analysis of results.

- **Group I:** partial tears or full-substance tears measuring less than 1 cm in sagittal diameter at bony detachment
 - a. Deep, partial tears
 - b. Superficial tears
 - c. Small, full-substance tears
- **Group II:** full-substance tears of entire supraspinatus
- **Group III:** full-substance tears involving more than one tendon
- **Group IV:** massive tears with secondary OA

Group I: this group includes partial tears and full-substance tears measuring less than 1 cm. The cuff remains watertight in the presence of incomplete tears. However, full-substance tears that do not involve the entire width of a given tendon are of no apparent mechanical consequence. The essential symptom is pain, which may cause loss of function. Lesions of Group I rarely exhibit an operative indication. Physiotherapy aiming to eliminate subacromial impingement usually results in satisfactory pain relief. Surgical repair, when indicated, is easily achieved either by suturing or by reattachment to bone. The necrotic tissue must be resected before repair.

The following three types of lesions are recognized:

- 1) The most commonly observed lesion during surgery is the *distally situated deep tear*, characterized by a detachment at the fibrocartilaginous zone. Trauma preceded 62% of these lesions. When partial tears at the articular side occur at a certain distance from the bony insertion (at the critical zone), they can be diagnosed by arthrography. They are the consequence of degeneration secondary to inadequate vascular supply. These partial tears must be followed closely, since their healing potential is low.

- 2) *Partial superficial tears*, which cannot be detected by arthrography, are diagnosed either by bursoscopy or at the time of surgery. These tears occur less frequently than some surgical statistics tend to indicate. Because of an adequate blood supply, their prognosis is good.
- 3) The third type is the *full-substance tear* of the supraspinatus that measures less than 1 cm in diameter at the bony insertion and thus does not involve the entire width of the tendon.

Group II: this group includes full-substance tears, which are usually limited to the supraspinatus. The sagittal diameter, measured at the bony insertion, is approximately 2 cm. The fascicles of the coracohumeral ligament inserting into the greater tuberosity are included in the tear. The infraspinatus is intact, although an intrasubstance tear secondary to interstitial necrosis developing in the posterior aspect is usually present.

Group III: in this group, defects are large and involve not only the supraspinatus but sometimes the subscapularis and usually the infraspinatus. The sagittal extent of the tear (4 cm or more), combined with a defect in the frontal plane, explains the nearly total absence of the cuff, especially when the necrotic part of the proximal stump is considered part of the defect. As a result, the humeral head migrates cranially and frontally, gradually impinging against the coracoacromial arch. These defects are serious and demand early surgical treatment.

Group IV: lesions in this group are characterized not only by massive tears but also by secondary OA of the humeral head. An acromioclavicular arthrosis develops, as does glenohumeral OA accompanied by narrowing of the joint at the superior glenoid pole and droplike osteophyte formation inferiorly. These lesions often limit the possibility of repair, and an arthroplasty thus becomes necessary.

5.8 Patterns of full-thickness rotator cuff tears according to Ellman and Gartsman [33]

The progressive failure of cuff fibre insertion produces several types of commonly encountered defects. One the tendon separates from its insertion, the torn margin is retracted by the unopposed pull of the torn muscle and its neighbours. An understanding of these patterns of tear facilitates reconstruction.

- **Crescent tear:** tear involves supraspinatus tendon (Fig. 10a).

Medial retraction presents a crescent-shaped defect beginning near the long head of the biceps tendon and arching medially and posteriorly for 2 to 3 cm.

- **Triangular defect:**

Reverse L: Supraspinatus tear extends medially through rotator cuff interval in line with long head of biceps tendon (Fig. 10b)

A moderate-sized triangular defect is most commonly produced when a supraspinatus tear extends medially along its anterior border in a line with the long head of the biceps tendon. This limb of the tear is located through the relatively thin fibrocapsular area between the subscapularis and supraspinatus tendon. The long head of the biceps tendon travels below the interval, whereas the coracohumeral ligament joins this interval from above as it courses toward its insertion. The torn surfaces outline a reverse L. The cuff margin retracted medially and posteriorly forms the hypotenuse of the triangular defect.

L-shaped tear: Supraspinatus tear has extend through junction with infraspinatus, thereby producing an anteromedial displacement (Fig. 10c).

A less commonly observed variation involves a tear of the supraspinatus with extension of the tear medially between the junction of the supra- and the infraspinatus fibres. In this L-shaped tear, the torn end of the infraspinatus has retracted medially and somewhat anteriorly. The pattern of retraction must be appreciated to identify the retracted edge and return it to its origin. Larger L-shaped tears are created as increasing portions of the infraspinatus become involved.

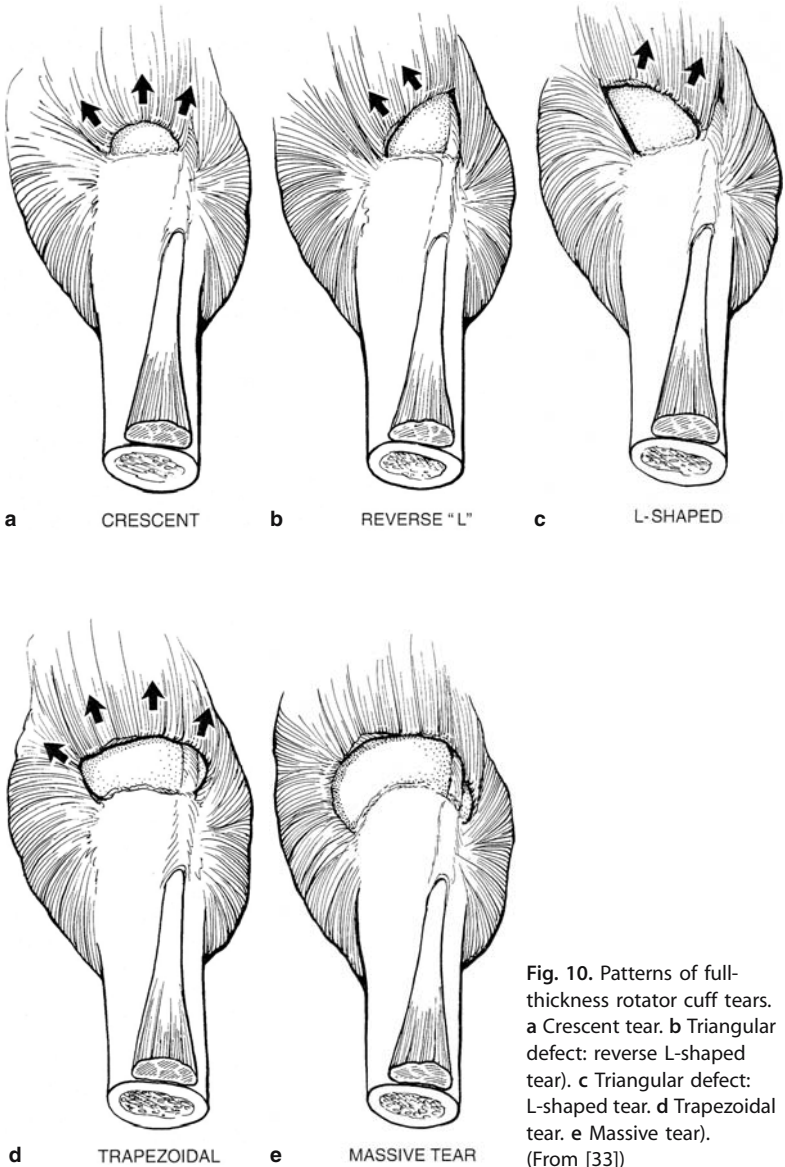


Fig. 10. Patterns of full-thickness rotator cuff tears. a Crescent tear. b Triangular defect: reverse L-shaped tear. c Triangular defect: L-shaped tear. d Trapezoidal tear. e Massive tear. (From [33])

- **Trapezoidal tear:** This tear results when both supraspinatus and infraspinatus are torn. As more of the infraspinatus insertion fails, the trapezoid enlarges (Fig. 10 d).

The trapezoidal tear generally develops when both the supraspinatus and the infraspinatus are torn and the tear extends anteriorly along the rotator interval and posteriorly into the interval between the infraspinatus and teres minor. The torn edges of the supra- and infraspinatus may be retracted medially to the level of the glenoid. In some instances, portions of the tendon and its musculotendinous junction may be literally ground away between the undersurface of the acromion and the humeral head as the head rises superiorly during overhead elevation of the arm. A pebbled and irregular appearance of the humeral head suggests the lengthy presence of the cuff defect. On the other hand, a relatively smooth, glistening dome suggests that the extensive two-muscle tear may be more recent in origin and more likely repairable.

- **Massive tear:** When three muscles are involved, the tear is usually massive. Two-muscle tears should be retracted at least 5 cm to be designated massive (Fig. 10 e).

The long head of the biceps is often displaced in these circumstances.

5.9 Classification of subscapularis tendon tears according to Fox and Romeo [39]

- **Type I:** partial thickness tear
- **Type II:** complete tear of upper 25% of tendon
- **Type III:** complete tear of upper 50% of tendon
- **Type IV:** complete rupture of tendon

5.10 Classification of tendon retraction in the frontal plane according to Patte [107] (Fig. 11)

- Stage 1: proximal stump close to the bony insertion
- Stage 2: proximal stump at level of humeral head
- Stage 3: proximal stump at level of glenoid

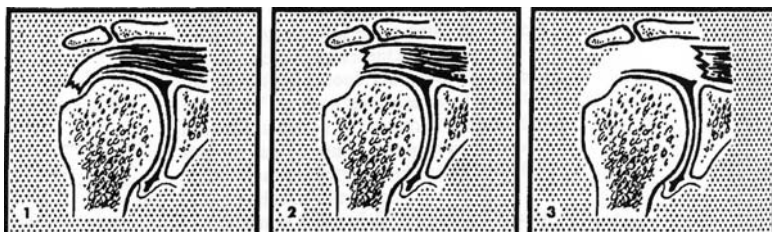

Fig. 11. Topography of tears in the frontal plane, in which three stages are easily recognized. In stage 1 the stump shows little retraction, in stage 2, it lies at the level of the humeral head, and in stage 3 it is seen at the level of the glenoid

5.11 Classification of supraspinatus muscle atrophy in MRI according to Thomazeau [128]*

All MRI images were obtained with a 1 Tesla unit. The quantitative analysis was then performed on the spin-echo T1-weighted oblique-sagittal images (TR: 480 ms, TE: 12 ms, FOV: 250×250, matrix: 380×512).

To evaluate the atrophy of the supraspinatus muscle, the occupation ratio (R) of the supraspinatus fossa by the muscle belly is calculated. This analysis was based on the ratio between the surface of the muscle S1 and the surface delineated by the limits of the fossa S2 (Fig. 12). The selected oblique-sagittal image was digitalized in order to use a calculation program. The limits of the surfaces were drawn by hand, and the ratio, $R = S1/S2$ was automatically calculated. The final result was a mean of these values expressed from 0 (empty fossa) to 1 (full fossa).

The measurement was taken at the level, where the scapula is cut through the medial border of the spine, just above the spinoglenoid notch. Moreover, the clavicle partially closes the anterosuperior part of the fossa.

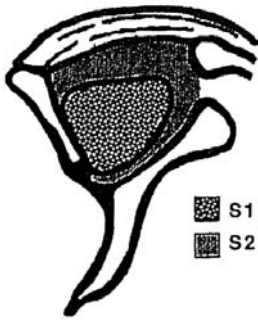

Fig. 12. Calculation of the occupation ratio R on the oblique-sagittal view. $S1$ Surface of the supraspinatus muscle; $S2$ surface of the entire supraspinatus fossa

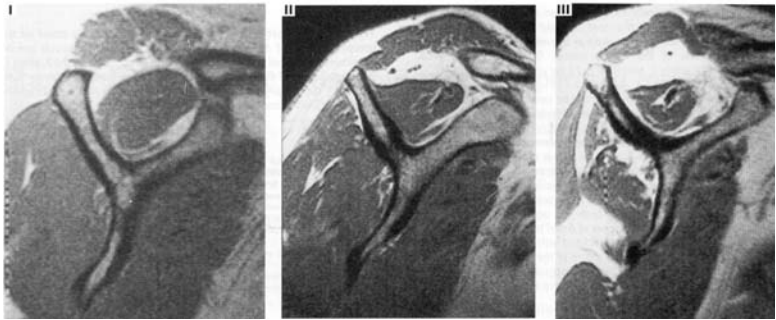


Fig. 13. Three grades of supraspinatus atrophy in MRI

The authors propose a classification of the supraspinatus belly atrophy based on the occupation ratio to the supraspinatus fossa (Fig. 13). In the case of a ratio between 1.00 and 0.60 (**stage I**), the muscle can be considered as *normal or slightly atrophied*. Values between 0.60 and 0.40 (**stage II**) suggest *moderate atrophy*. Values below 0.40 (**stage III**) indicate *serious or severe atrophy* (Table 2).

Table 2. Occupation ratio of the supraspinatus fossa related to grade of supraspinatus tendinopathy

Stage		Occupation ratio
I	Normal or slightly atrophied	1.00–0.60
II	Moderate atrophy	0.60–0.40
III	Serious or severe atrophy	<0.40

5.12 Classification of supraspinatus muscle atrophy in MRI according to Zanetti [142]*

Magnetic resonance imaging was performed on a 1.0-Tesla scanner. A sequence of parasagittal T1-weighted turbo spin-echo MRI images (repetition time [TR]/echo time [TE]: 700/12 ms) parallel to the glenohumeral joint space was obtained.

For quantitative assessment, areas and SIs of the rotator cuff muscle and the area of the fossa supraspinata were measured at the most lateral image on which the scapular spine is in contact with the rest of the scapula (Fig. 14 a).

Tangent Sign: Qualitative assessment of atrophy of the supraspinatus muscle: For quick qualitative evaluation of atrophy of the supraspinatus muscle a morphologic sign was introduced. A line (tangent) was drawn through the superior borders of the scapular spine and the superior margin of the coracoid (Fig. 14 d). The tangent sign was defined as abnormal (**positive**) (Fig. 14 e,f) when the supraspinatus muscle did not cross the tangent. The tangent sign is a qualitative sign of muscle atrophy with a high predictive value. Obviously, its use is limited to the supraspinatus muscle, which is not adequate for all types of tears.

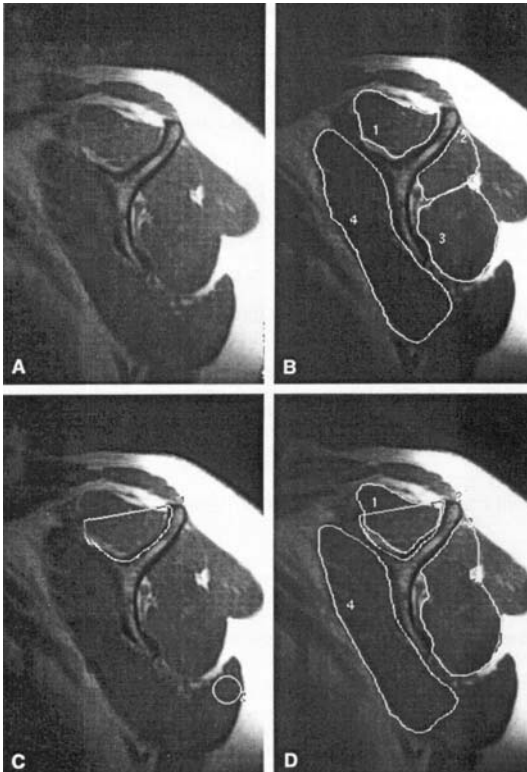


Fig. 14A–F. **A** The most lateral image on which the scapular spine is in contact with the rest of the scapula was chosen as reference section. **B** Areas and mean signal intensities were obtained using regions of interest determined by the contours of the supraspinatus (1), infraspinatus (2); teres minor (3), and subscapularis muscle (4). **C** Measurement of the area of the supraspinatus (1) and the mean signal intensity of the teres major muscle (2). **D** Because the border between the infraspinatus and teres minor muscles cannot reproducibly be measured, these two measurements were combined for the purpose of the investigation. This figure demonstrates all measurements used in this investigation for quantification of the rotator cuff: supraspinatus muscle (1); supraspinatus fossa (2); combined measurement of the infraspinatus and teres minor muscles (3); and subscapularis muscle (4). Note normal (negative) tangent sign: the normal supraspinatus muscle reaches above the line drawn through the superior borders of the coracoid and scapular spine

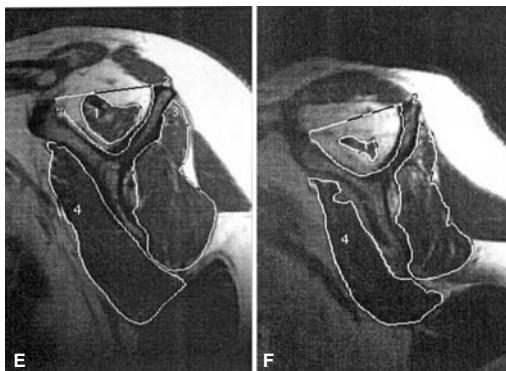


Fig. 14. E A borderline abnormal (positive) tangent sign. F Positive tangent sign

5.13 Classification of fatty muscle degeneration in cuff ruptures using CT-scan according to Goutallier et al. [49] (Fig. 15)*

The areas of muscular hypodensity observed seem to correspond to fat tissue, which does not necessarily mean that there is a muscular atrophy, and CT scan patterns are said to be without specific diagnostic value.

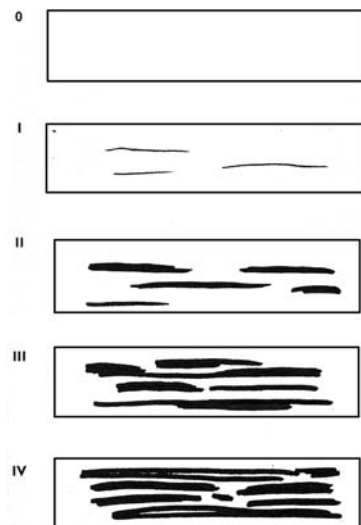


Fig. 15. Classification of muscles according to their degree of fatty infiltration

Measurement of shoulder cuff muscle areas or volumes cannot be reliably or easily performed, particularly with a CT scan, but the assessment of fatty muscular infiltration remains a good tool in clinical practice.

- **Stage 0:** corresponds to a completely normal muscle, without any fatty streak
- **Stage 1:** the muscle contains some fatty streaks
- **Stage 2:** the fatty infiltration is important, but there is still more muscle than fat
- **Stage 3:** there is as much fat as muscle
- **Stage 4:** more fat than muscle is present

6.1 Variants of the origin of the long head of the biceps from the scapula and glenoid labrum according to Vangsness et al. [131]*

One hundred fresh-frozen shoulders were studied. Each specimen was dissected to expose the intact shoulder capsule. The authors then photographed the tendon attachment to the supraglenoid tubercle, recording the percentage of fibres arising from the tubercle, the anterior labrum, and the posterior labrum.

Four types of attachment could be distinguished:

- **Type I:** All of the labral part of the attachment was to the posterior labrum, with none to the anterior labrum (Fig. 16 a)
- **Type II:** Most was to the posterior labrum, but with a small contribution to the anterior labrum (Fig. 16 b)
- **Type III:** Equal contributions to anterior and posterior labrum (Fig. 16 c)
- **Type IV:** Most attached to the anterior labrum, with a small contribution to the posterior labrum (Fig. 16 d)

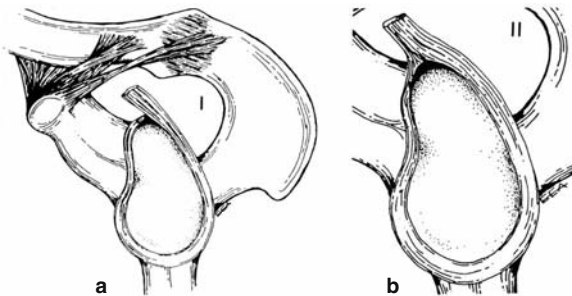


Fig. 16 a–d. **a** Type I. The labral attachment is entirely posterior, with no contribution to the anterior labrum. **b** Type II. Most of the labral contribution is posterior

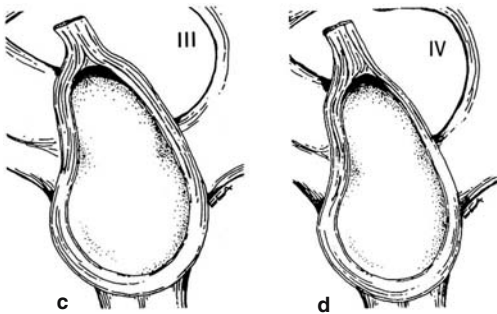


Fig. 16. c Type III. There are equal contributions to both the anterior and the posterior parts of the labrum. d Type IV. Most of the labral contribution is anterior, with a small contribution to the posterior labrum

6.2 Classification of SLAP-Lesions (superior labrum, anterior to posterior lesion) according to Snyder [122, 123]*

A SLAP lesion is defined as an injury of the superior labrum from anterior to posterior in relation to the biceps tendon anchor.

- **Type 1:** fraying and fragmentation of the free edge of the superior labrum.
 - 21% of SLAP lesions.
 - This is often a relatively minor problem that is commonly encountered during routine arthroscopy in middle-aged and older patients (Fig. 17 a).
- **Type 2:** the biceps anchor is significantly detached from the superior glenoid tubercle.
 - Usually associated with fraying of the edge of the labrum.
 - The middle glenohumeral ligament may be rendered unstable when it has a high attachment of the superior labrum and must be evaluated for security.
 - 55% of SLAP lesions (Fig. 17 b).

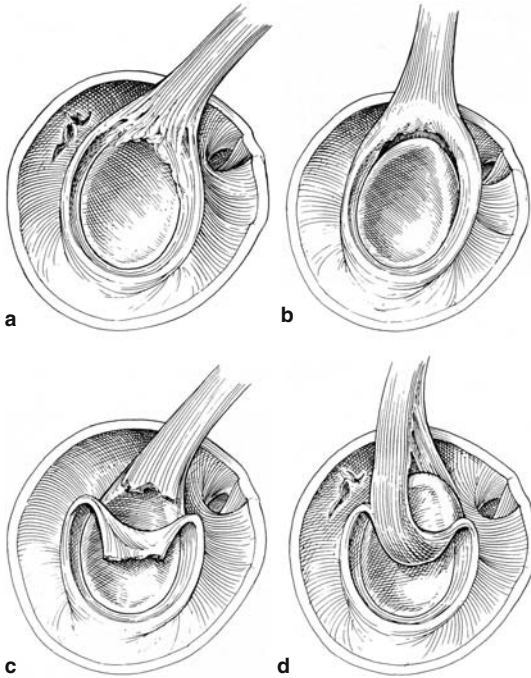


Fig. 17. a Type-1 superior labrum, anterior to posterior (SLAP) Lesion. b Type-2 SLAP Lesion. c Type-3 SLAP Lesion. d Type-4 SLAP Lesion

- **Type 3:** bucket-handle tear of a meniscoid superior labrum with an otherwise normal biceps tendon attachment.
 - The fragment of labrum is usually mobile like a bucket-handle tear of a meniscus in the knee, but it may be split in two, leaving a stub of labral tissue on either end.
 - Rarely, the middle glenohumeral ligament may be confluent with the free fragment of labrum and consequently rendered unstable.
 - 9% of SLAP lesions (Fig. 17 c).
- **Type 4:** type 3 lesion with the tear extending into the biceps tendon.
 - The tendon split may be minimal or quite significant.
 - 10% of SLAP lesions (Fig. 17 d).

Combined or complex SLAP lesions: Most often, these are type 3 or 4 lesions combined with a significantly detached biceps anchor, or type 2 lesion. When this is encountered, it has to be classified as a complex SLAP type 2 and 3 or type 2 and 4 lesion.

6.3 Classification of SLAP lesion according to Maffet et al. [82]*

The authors performed a diagnostic arthroscopy in 63 patients. Of these, 62% had lesions that fit within the classifications system of Snyder [122, 123]. Thirty-eight percent in this study had significant biceps tendon-superior labrum injury that did not fit into the classification system proposed by Snyder [122, 123]. The authors defined three additional types of SLAP lesions:

- **Type I-IV:** are equivalent to Snyder's classification
- **Type V:** an anterior-inferior Bankart lesion continues superiorly to include separation of the biceps tendon (Fig. 18 a)
- **Type VI:** an unstable flap tear of the labrum is present in addition to biceps tendon separation (Fig. 18 b)
- **Type VII:** the superior labrum-biceps tendon separation extends anteriorly beneath the middle glenohumeral ligament (Fig. 18 c)

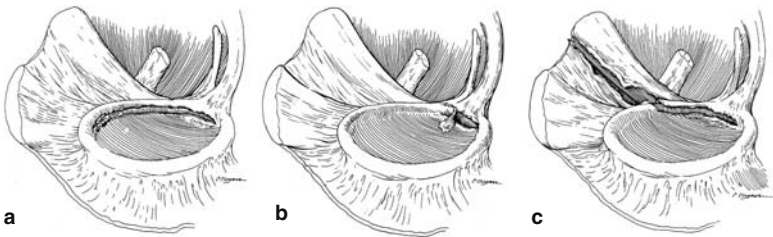


Fig. 18. a Type-V SLAP lesion (Maffet). b Type-VI lesion (Maffet). c Type-VII lesion (Maffet)

6.4 Subtypes of SLAP II lesions according to Morgan [88]*

The type II SLAP lesion as originally described by Snyder [122, 123] involved a detachment of the biceps anchor and the adjacent labrum from bone with an anterosuperior location.

The authors have observed three types of type II SLAP lesions by anatomic location:

- **Anterior SLAP lesion:** anterosuperior type II SLAP lesion (Fig. 19a)
- **Posterior SLAP lesion:** posterolateral type II SLAP lesion (Fig. 19b)
- **Combined SLAP lesion:** combined anterior and posterior type II SLAP lesion (Fig. 19c)

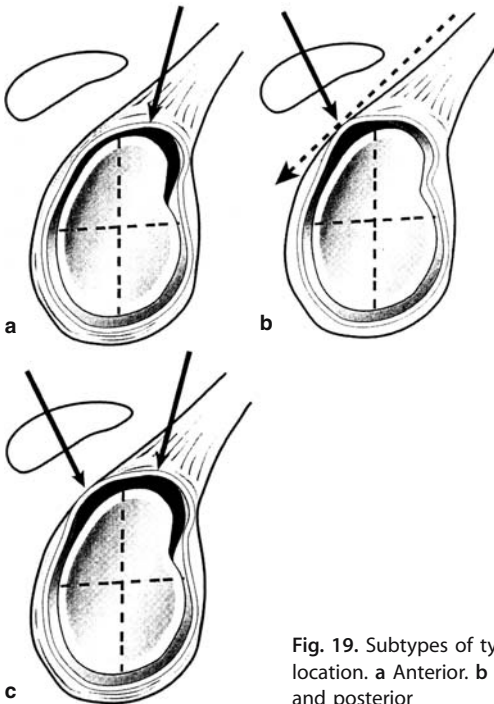


Fig. 19. Subtypes of type-II SLAP lesions by anatomic location. a Anterior. b Posterior. c Combined anterior and posterior

6.5 Topographic classification of LHB-lesions [58] (Table 3)

- **Zone 1:** origin
- **Zone 2:** intraarticular course
- **Zone 3:** bicipital groove
- **Zone 4:** lesions below the bicipital groove

Table 3. Topographical classification of LHB lesions

Lesion	Zone	Pathology
Lesions of the origin of the LHB	I	SLAP lesions I–IV Andrews lesions
Supratubercular lesions	II	Isolated tendinosis/tendinitis (Partial) tears of LHB (Partial) tears of LHB in Rotator cuff lesions Supratubercular instability (Walch I)
Sulcus associated lesions	III	Subluxation/dislocation out of the bicipital groove (Walch II) without lesions of postero-superior rotator cuff but where applicable accompanied with a lesion of the subscapularis tendon (and capsule)
Lesions below the bicipital groove	IV	Peripheral of proximal LHB (e.g., at tendon–muscle transition zone)

6.6 Classification of biceps tendon disorders according to Yamaguchi and Bindra [140]

The various disorders of the long head of the biceps tendon were classified into inflammatory, unstable, or traumatic, on the basis of the original initiating event. It must be stressed that the distinction is not always clear; the degenerated and inflamed tendon is more prone to trauma and, conversely, repeated trauma may result in changes in the tendon indistinguishable from those of inflammation. Nevertheless, this classification can help with the organization of the pathogenesis of these disorders and formulation of protocols for appropriate management.

I. Inflammatory

1. Biceps tendinitis concurrent with rotator cuff disease
2. Primary bicipital tendinitis

II. Instability

1. Subluxation
 - Type I: superior subluxation
 - Type II: unstable at proximal portion of groove
 - Type III: subluxation following melanin or nonunion of lesser tuberosity
2. Dislocation
 - Type I: extraarticular, combined with partial tear of subscapularis
 - Type II: intraarticular, combined with full-thickness tear of subscapularis

III. Traumatic

1. Traumatic rupture
 - Type I: partial
 - Type II: complete
2. Superior labral tears (SLAP lesion)
 - Type I: significant fraying
 - Type II: complete detachment of biceps tendon and superior labrum from glenoid
 - Type III: “bucket-handle” tear of superior labrum
 - Type IV: central superior labrum tear with extension into the biceps

6.7 Histological changes of the long head of the biceps tendon according to Murthi et al. [92]*

- Normal
- Chronic inflammation
- Fibrosis
- Mucinous degeneration
- Vascular congestion
- Dystrophic calcification
- Acute inflammation

6.8 Classification of subluxation of the long head of the biceps tendon according to Walch [54]*

Habermeyer and Walch define subluxation of the long biceps tendon as a partial and/or transient incomplete loss of contact between the tendon and its bony groove. Three different types of biceps tendon subluxation were recognized:

■ Superior subluxation (type I):

The circular sling of the superior glenohumeral and coracohumeral ligaments (i.e., rotator interval sling) is partially or completely torn, resulting in loss of restraint of the long head of the biceps tendon above the entrance to the groove. The subscapularis tendon, which attaches to the lesser tubercle just below the superior glenohumeral ligament, is largely intact; otherwise a true dislocation is present. The lesion above the entrance to the groove is sometimes marked by an accompanying partial lesion of the supraspinatus tendon on the articular side, directly at the lateral groove entrance, where it forms the roof for the biceps tendon. The pathologic substrate of the type I subluxation is discontinuity in the tendo-ligamentous rotator interval sling surrounding the long biceps tendon (i.e., lesions of the coracohumeral and superior glenohumeral ligament and a partial rupture of the supraspinatus and/or subscapularis tendon above the entrance to the groove).

■ **Subluxation at the groove (type II):**

The lesion responsible for the subluxation is located below the entrance to the bony groove. With this type of lesion, the tendon slips over the medial rim of the bony groove and “rides” on the border of the lesser tuberosity. The causal lesion is a detachment of the outermost fibres of the subscapularis tendon. Tearing of the superficial (outer) portions that line the floor of the groove and help anchor the long biceps tendon allows the tendon to displace to a medially subluxated position. The principal criterion for a type II biceps tendon subluxation is a partial rupture of the outer, superficial tendinous portions of the subscapularis muscle, allowing the biceps tendon to ride over the bone of the lesser tuberosity. The type II lesion may be confined to the superior half of the groove or may involve its entire length.

■ **Malunion and nonunion of the lesser tuberosity (type III):**

A fracture-dislocation of the lesser tuberosity can progress to a malunion or nonunion that compromises the medial bony restraint of the long biceps tendon, allowing the tendon to subluxate. The patient complains of painful internal rotation of the humerus.

6.9 Classification of dislocation of the long head of the biceps tendon according to Walch [54]*

Habermeyer and Walch [54] have proposed a classification based upon the pathomorphologic features of the biceps tendon dislocation.

■ **Type I**

- **Extraarticular dislocation combined with a partial tear of the subscapularis tendon**

In this type the long biceps tendon is completely dislocated to a point over the lesser tuberosity. The deeper portions of the subscapularis tendon still insert into the lesser tuberosity, separating the biceps tendon from the joint space. Invariably there is a rupture of the common attachment of the superior glenohumeral ligament and coracohumeral ligament. The biceps tendon, then, is displaced over the anterior wall of the groove and slips or glides medially over the torn fibres of the subscapularis tendon. The clavipectoral fascia covers this

lesion externally, and this might give the impression that the supscapularis tendon is intact over its full-thickness. It has been shown, however, that the outer attachment of the supscapularis tendon is always torn. This type of dislocation corresponds in its evolution to a type II subluxation but represents a more advanced stage.

Besides the superficial lesion of the subscapularis tendon, there is frequently an associated tear of the rotator cuff. Only systematic exploration of the rotator cuff interval can ensure that the dislocation of the long biceps tendon is missed.

– **Extraarticular dislocation with an intact subscapularis tendon**

Dislocation of the long biceps tendon over a completely intact subscapularis tendon is very rare. In a series of 70 patients with subluxation and dislocations of the long biceps tendon, only 2 patients (3%) were found to manifest this condition.

■ **Type II**

– **Intraarticular dislocation of the long biceps tendon combined with a complete tear of the subscapularis tendon**

The biceps tendon is widened and flattened as a result of its contact with the lesser tuberosity. It is shown as a diversity of substance lesion, ranging from erosion to prerupture. The subscapularis tendon is torn from its attachment on the lesser tuberosity, and the long biceps tendon is interposed into the joint space and displaced inferomedially. On the articular side, the biceps tendon is apposed to the glenoid labrum. Entrapment of the tendon in the anterior joint space occurs with each internal rotational movement of the humerus. Usually the proximal two-thirds of the subscapularis tendon is ruptured; rarely is the distal, purely muscular insertion of the subscapularis tendon torn as well. We credit Gerber [144] with drawing attention to the problem of an isolated rupture of the subscapularis tendon and its consequences.

The intraarticular dislocation is often associated with extensive tearing of the rotator cuff. Approximately half of these dislocations have a traumatic etiology.

6.10 Classification of "hidden" rotator interval lesions according to Bennett [8]*

Various lesions of the rotator interval are illustrated in Fig. 20. These include subscapularis tear or intraarticular subscapularis (IASS) without involvement of the SGHL/MCHL complex, Fig. 20a; tears of the SGHL/MCHL complex without subscapularis (IASS) involvement, Fig. 20b; and subscapularis (IASS) tears with involvement of the SGHL/MCHL com-

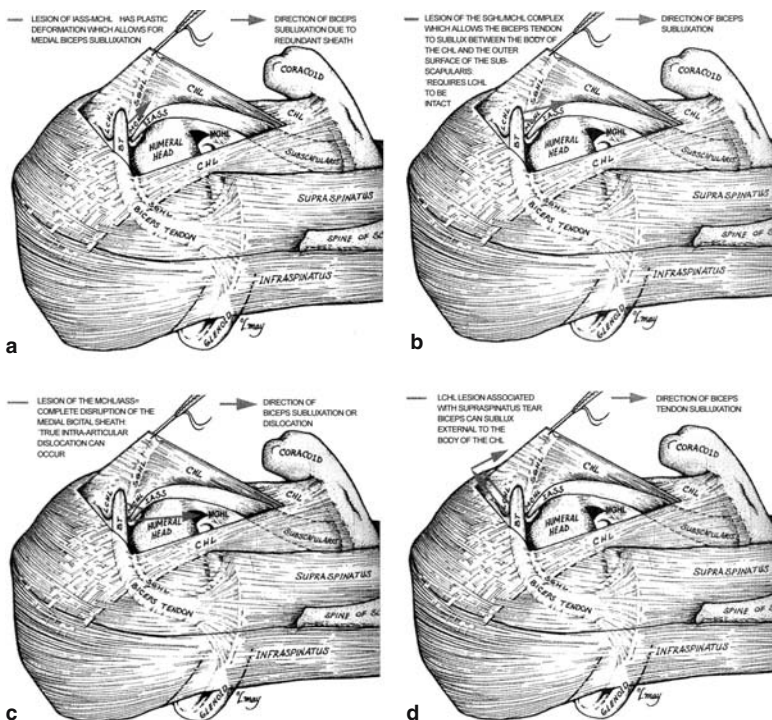


Fig. 20. Arthroscopic classification of "hidden" rotator interval lesions. The various lesions found in rotator interval. Arrows indicate potential direction and area of abnormal biceps motion. a Intraarticular subscapularis (IASS) lesion. b Middle coracohumeral ligament lesion (MCHL). c MCHL/IASS lesion. d Lower coracohumeral ligament lesion. (From Bennett [8])

plex, Fig. 20c. While the lateral wall of the bicipital sheath is not truly in the rotator interval a lesion of the LCHL is also illustrated, Fig. 20d.

6.11 Classification of pulley lesions according to Habermeyer et al. [52]*

- **Group 1:** isolated lesion of the superior glenohumeral ligament (Fig. 21 a)
- **Group 2:** lesion of the superior glenohumeral ligament and partial articular-side lesion of the supraspinatus tendon (Fig. 21 b)

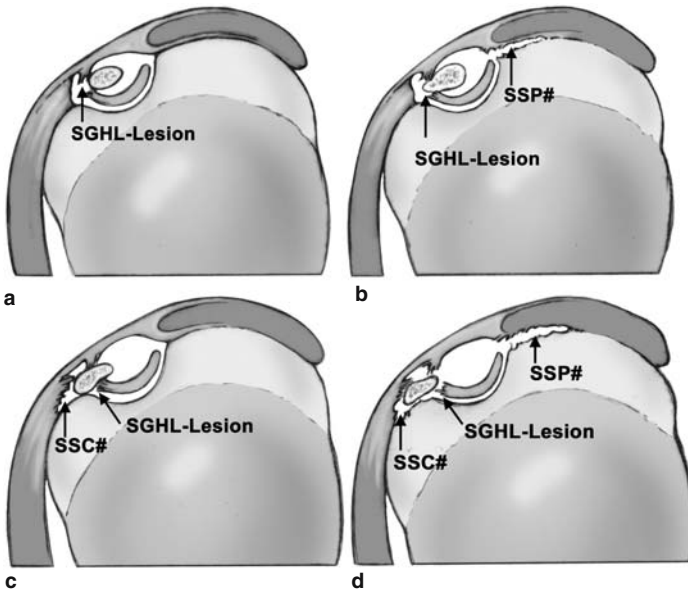


Fig. 21. Classification of Pulley lesions. (From Habermeyer et al. [52]). a Group 1: (SGHL) lesion only. b Group 2: SGHL lesion and partial articular-side supraspinatus tendon tear (SSP#). c Group 3: SGHL lesion and partial articular-side subscapularis tendon tear (SSC#). d Group 4: SGHL lesion with partial articular-side supraspinatus (SSP#) and subscapularis tendon tear (SSC#)

- **Group 3:** combination of a lesion of the superior glenohumeral ligament and a deep surface tear of the subscapularis tendon (Fig. 21 c)
- **Group 4:** combination of a lesion of the superior glenohumeral ligament and a deep surface tear of the supraspinatus and the subscapularis tendon (Fig. 21 d)

7.1 Classification of scapular dyskinesia according to Kibler and McMullen [68]

Scapular dyskinesia is defined as observable alterations in the position of the scapula and the patterns of scapular motion in relation to the thoracic cage. Several factors may create these abnormal patterns and positions.

Three-dimensional biomechanical analysis of possible scapular motions shows that the scapula moves around three axes of motion simultaneously. Patterns of abnormal motion in scapular dyskinesia are best observed by first determining the position of the scapula with the patient's arms at rest at the side, then by observing the scapular motion as the arms are elevated and lowered in the scapular plane. These dyskinesic patterns fall into three categories, which correspond to the three planes of motion on the ellipsoid thorax. This system can help identify the type of abnormal scapular motion and thus the rehabilitation required by muscle strengthening and restoration of flexibility.

- **Type I** is characterized by prominence of the inferior medial scapular border. This motion is primarily abnormal rotation around a transverse axis (Fig. 22 a).
- **Type II** is characterized by prominence of the entire medial scapular border and represents abnormal rotation around a vertical axis (Fig. 22 b).
- **Type III** is characterized by superior translation of the entire scapula and prominence of the superior medial scapular border (Fig. 22 c).

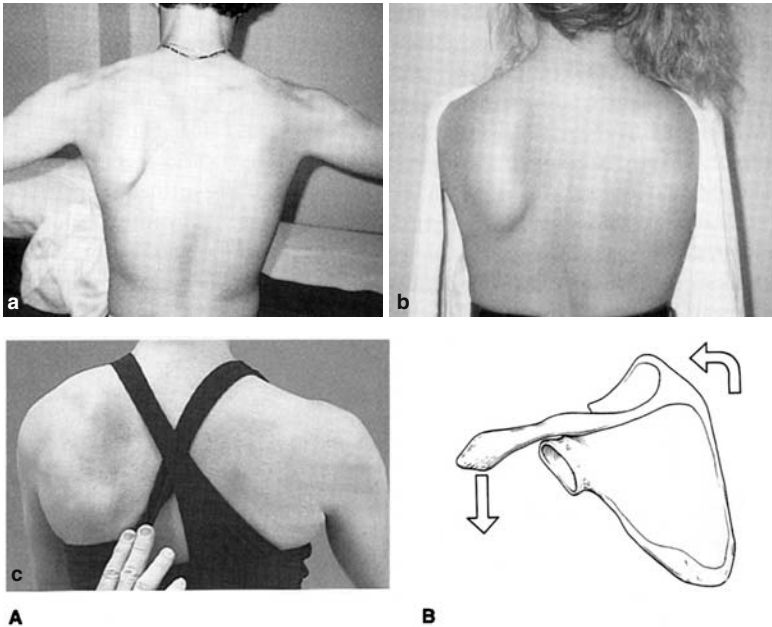


Fig. 22. Classification of scapula dyskinesis. **a** Type-I dyskinesis, with inferior medial border prominence (left scapula). **b** Type-II dyskinesis, with prominence of the entire medial border (left scapula). **c** Type-II dyskinesis (A) with prominence of the superior medial border (left scapula). Scapular superior translation on the thorax (B). (From [68])

7.2 Types of variable topographical relationship of the glenohumeral ligaments to the synovial recesses (types of arrangement of the synovial recesses) according to DePalma [29]*

On the basis of a cadaver study of 108 shoulders, the variable topographical relationship of the glenohumeral ligaments to the synovial recesses (Fig. 23a) gave rise to six distinct variations designs as Types I to VI.

There are developmental types for they were present also in infant shoulders. However, because of progressive soft-tissue changes the different types may lose their distinguishing features.

The size of both the superior and inferior subscapularis recess, regardless of the type in which they are found, demonstrated extreme variability. They may be very small or very large. With advancing age there is a tendency for the recesses to become smaller and in some instances obliterated by increased thickness of the capsular tissue.

■ **Type I:**

- characterized by one synovial recess above the middle glenohumeral ligament (Fig. 23 b)
- was observed in 30.2% of the specimens

■ **Type II:**

- one synovial recess below the middle glenohumeral ligament (Fig. 23 c)
- was observed in 2.04% of the specimens

■ **Type III:**

- two synovial recesses. A superior subscapular recess above the middle glenohumeral ligament, and an inferior subscapular recess below the middle glenohumeral ligament (Fig. 23 d)
- was observed in 40.6% of the specimens

■ **Type IV:**

- one large synovial recess above the inferior glenohumeral ligament; the middle glenohumeral ligament is absent (Fig. 23 e)
- was observed in 9.03% of the specimens

■ **Type V:**

- the middle ligament exists as two small synovial folds (Fig. 23 f)
- was observed in 5.1% of the specimens

■ **Type VI:**

- a complete absence of any synovial recesses (Fig. 23 g)
- was observed in 11.4% of the specimens

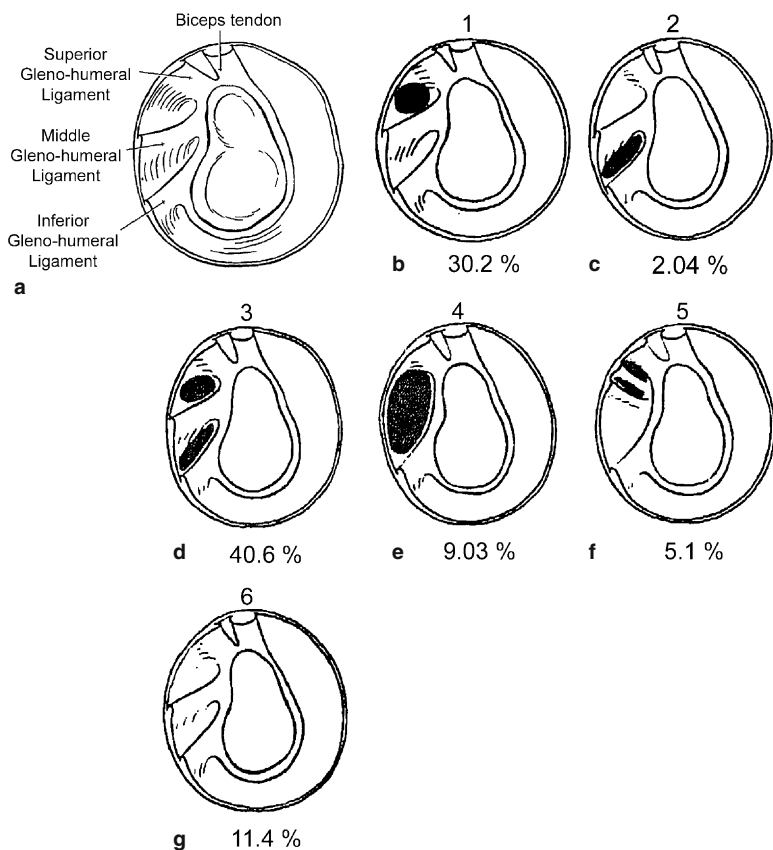


Fig. 23. Types of arrangement of the synovial recesses. a Anatomy of glenohumeral ligaments. b Type I. c Type II. d Type III. e Type IV. f Type V. g Type VI

7.3 Variations of glenohumeral ligaments according to Gohlke et al. [46]*

Gohlke et al. [46] studied the macroscopic anatomy and the architecture of collagen fibre bundles in the joint capsule of 43 cadaver shoulders.

They identified five variations of the middle glenohumeral ligament (MGHL) and three variations of the inferior glenohumeral ligament (IGHL).

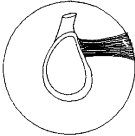
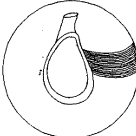
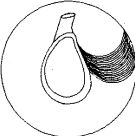
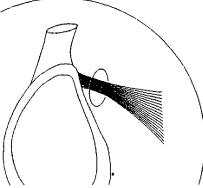
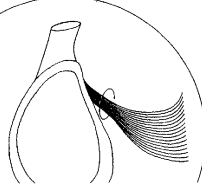
Middle glenohumeral ligament

The MGHL was visible in all capsules – although with greatly differing expression – and a wide range of patterns. These differences did not only apply to the insertion at the glenoid (at the labrum: 86% and at the glenoid rim: 14%), but also to the orientation of the collagen fibre bundles. The fibre bundles were mainly radially orientated and with the overlying fibres of the fasciculus obliquus and the insertion of the ligamentous parts of the M. subscapularis formed the macroscopically recognizable ligament. The width of the MGHL varied between 4 and 25 mm (mean average 14.7 mm).

Variations of the middle glenohumeral ligament

In 67.4% the MGHL blended with the capsule in its whole length, whereas in 32.6% it was a small band (4 to 7 mm wide) originating near the cranial-most aspect of the labrum and widening into a fan shape toward the humeral insertion. This band formed a bridgelike structure for a length of 20 mm on average and crossed the tendon of the M. subscapularis, which to a large extent blended with the capsule. Only in two specimens did the fibre bundles radiate into the tendon of the M. subscapularis before the bony insertion (Fig. 24a):

- MGHL blended with the capsule
 - Straight
 - Slightly curved
 - Curved
- MGHL separated from the capsule
 - Separate/cordlike
 - Separate/curved

Variations:	straight: 37.2% (n=16)	slightly curved: 39.5% (n=17)	curved: 23.3% (n=10)
<i>blended with the capsule:</i> 67.4% (n=29)			
<i>separate</i> 32.6% (n=14)	separate/cordlike: 11.6% (n=5)		separate/curved: 21% (n=9)
			
Classification	(+): even visible 42% (n=18)	(++): distinct 49% (n=21)	(+++): clearly visible, ligamentous reinforcement within the capsule 9% (n=4)

a

Fig. 24 a, b. Variations of glenohumeral ligaments. a Variations of collagen-fibre bundles with predominantly radial orientation in MGHL. Examined by polarized light: The complete specimens were transilluminated with polarized light and examined under the stereo-zoom microscope. The interference colors that arose from the double refraction of the collagen fibres made identification of their orientation much easier. The character of ligamentous structures (i.e., evidence of collagen-fibre bundles running parallel to each other, as provided by examination under polarized light, was divided into four categories: 0 absent; barely visible; ++ distinct; +++ clearly visible, strong reinforcement. b Variations of collagen-fibre bundles (with predominantly radial orientation) of inferior glenohumeral ligament visible by polarized microscopy. (From [46])

Inferior glenohumeral ligament

The IGHL exhibited the most constant pattern of all reinforcing ligaments and could be identified as a broad structure with closely packed collagen fibre bundles.

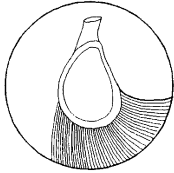
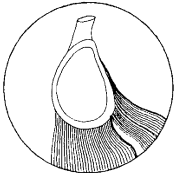
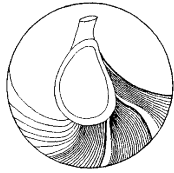
<i>Variations</i>			
	no division: 58 % (n=25)	two parts: 37.3 % (n=16)	three parts, posterior fiber bundles in a more circular orientation: 4.7 % (n=2)
<i>Classification</i>	(+): even visible 9 % (n=4)	(+ +): distinct 46,5% (n=20)	(+ + +): clearly visible ligamentous reinforcement 44,5% (n=19)

Fig. 24 b

Variations of inferior glenohumeral ligament

In 53.5% the origin lay near the cranial aspect of the labrum, which sometimes led to it being covered by MGHL. In these cases the fibres left the labrum at an acute angle and ran diagonally caudalward to the humeral insertion. In the 46.5% in which there was no overlapping, the course of the band was radial rather than diagonal. In three cases (7%) the distal fibre bundles of the IGHL ran posteriorly in a more circular orientation without extending in a radial fashion to the humerus. In this situation the IGHL originated near the cranial aspect of the labrum.

Posterior band of the IGHL

This ligamentous reinforcement was subject to the greatest variation. Only in 62.8% could we define the ligament; in all other cases it merged with surrounding fibrous structures. In 39.6% it was assessed as weak (+), in 23.2% as medium (++). There was no case of clearly (+++) defined posterior band (Fig. 24b).

- No division (most common type)
- Two parts: anterior bundles, in a higher gear than in patients with no division
- Three parts: posterior fibre bundles in a more circular orientation and floating transition into the posterior capsule

7.4 Anatomical variations of the glenohumeral ligaments according to Morgan et al. [87]*

The authors described four normal variations in the ligamentous tissues, as follows:

- **Type I:**
 - classic arrangement: all three ligaments were present and attached in the classic pattern to the labrum (Fig. 25 a)
 - was seen in 66%
- **Type II:**
 - there was confluence between the middle and inferior ligaments with an absent or poorly developed middle ligament (Fig. 25 b)
 - was present in 7%
- **Type III:**
 - normal-appearing superior ligament with a “cordlike” middle glenohumeral ligament and a classic inferior ligament with a well-defined superior band (Fig. 25 c)

The cordlike middle ligament was described as having an appearance like that of a rounded cord with a rolled upper and lower edge. There appeared to be an opening to the subscapularis recess above and below the middle ligament
 - was found in 19%
- **Type IV:**
 - these specimens failed to demonstrate any discernible anterior capsular ligaments (Fig. 25 d)
 - was found in 8%

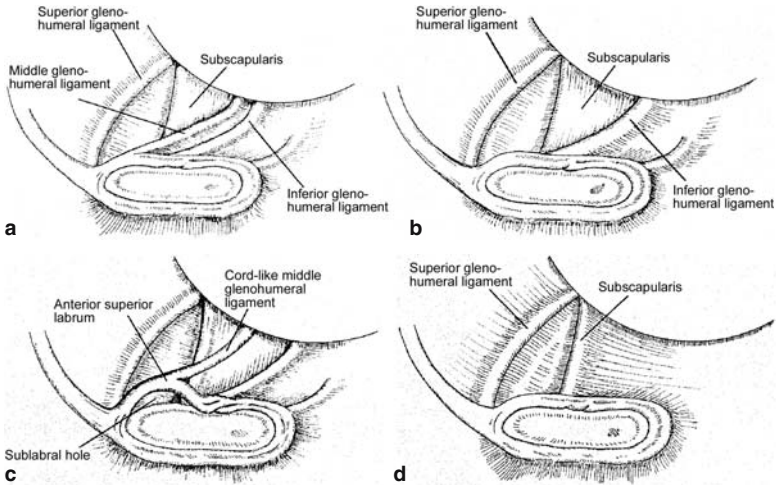


Fig. 25. Common variations in the glenohumeral ligaments. **a** Type I. The classic arrangement of the glenohumeral ligaments includes distinct superior, middle, and inferior glenohumeral ligaments, with a recess or reflection beneath each. No capsular foramen is present. **b** The type-II arrangement includes a confluent middle and inferior glenohumeral ligament pattern in which these two ligaments present as one ligament with no recess between them. No capsular foramen is present. **c** The type-III pattern is that in which the middle glenohumeral ligament appears as a cordlike structure with a high-riding glenoid attachment and a large capsular foramen beneath the cord, but a normal-appearing inferior glenohumeral ligament. **d** In the type-IV ligament, the anterior capsule appears as a confluent sheet with no ligamentous thickenings, reflections, or recesses. (From [87])

7.5 Classification of instability according to Silliman and Hawkins [119]

The current classification scheme is based on an algorithmic approach. Many factors, such as direction, degree, chronology, cause, frequency, and volition play a role in this scheme (Fig. 26).

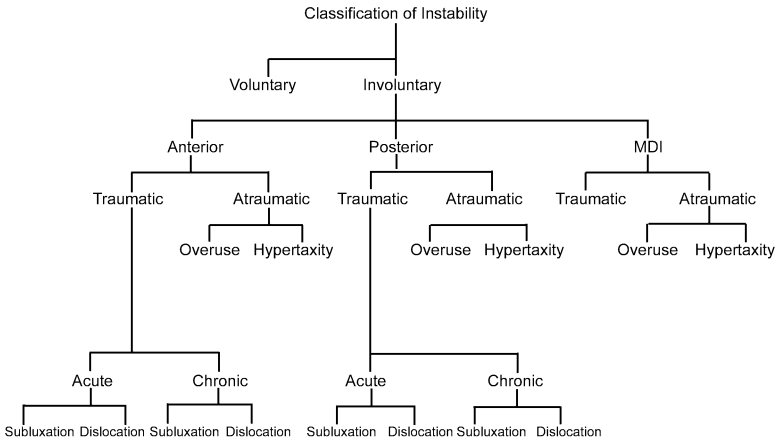


Fig. 26. Algorithm of classification of instability. (From [119])

7.6 Grading of glenohumeral translation according to Hawkins et al. [57, 119]*

Glenohumeral translation is assessed also with the patient supine. Here the arm is grasped in a position of approximately 20° abduction and forward flexion in the neutral rotation, the humeral head is loaded and then posterior and anterior stresses are applied.

In the relaxed or anesthetized patient, it is important to remember that most normal shoulder allow some translation of the humeral head in the glenoid fossa. Many shoulders can be translated posteriorly up to half the width of the glenoid fossa (i.e., the examiner can feel the humeral head right up to the glenoid face, but not over the glenoid rim).

A grading system has been applied and, under anaesthesia, normal shoulders have mild translation anteriorly and inferiorly. In most patients, especially if they are relaxed, there is good correlation of translation awake and under anaesthesia. Accurate determination in the painful shoulder may be possible only under anaesthesia.

Silliman and Hawkins [119] examined prospectively 29 anesthetized patients and classified the glenohumeral translation in the following grading system:

- **Grade I:** 0–25% movement (minimal movement)
- **Grade II:** 25–50% (feeling the humeral head ride upon the glenoid rim)
- **Grade III:** greater than 50% (feeling the humeral head side up and over the other side of the glenoid rim)

7.7 Classification of recurrent instability according to Neer and Foster [99, 100]*

In our patients with recurrent dislocations we see combinations of three etiologies in varying proportions: (1) inherent congenital laxity of the glenohumeral capsule, (2) trauma (a major injury), and (3) activities that repeatedly stress the joint capsule such as swimming, weight lifting, and gymnastics. Therefore, the classification of recurrent dislocations is as follows (Table 4):

- I. Atraumatic: no injury
- II. Traumatic: one major injury
- III. Acquired: repeated minor injuries

Table 4. Classification of recurrent dislocations

	Etiology	Pathology	Clinical
Atraumatic	Congenital laxity (no injury)	Generalized joint laxity Labrum intact; no bone changes X-rays negative (except for evidence of laxity)	No injury; patient always had been “loose jointed”; first dislocation ill-defined No labral tear or bone changes Self-reduced Often asymptomatic
Traumatic	One major injury (hard fall, wrestling)	No joint laxity Labrum detached or middle glenohumeral ligament torn X-rays: usually a traumatic humeral head defect and glenoid rim fragment	No prior shoulder symptoms Definite injury (e.g., hard fall, wrestling); swelling and pain from injury; possible nerve injury Requires help to reduce Unidirectional

Table 4 (continued)

	Etiology	Pathology	Clinical
Acquired	Repeated minor injuries (swimming, gymnastics, weightlifting, overhead work)	Possible finger laxity Increased glenohumeral joint volume (other joints spared) Labrum often intact, later may be detached May develop a humeral head defect X-rays: negative early, bone changes later	Minimal trauma at first dislocation (e.g., swinging a bat, lifting weight overhead, etc.) Less soreness Usually self-reduced Threat of multidirectional instability

7.8 Classification of shoulder instability according to [127] Matsen et al. [84]*

The authors find the most practical approach is to recognize two common types of glenohumeral instability.

On the basis of a retrospective clinical study the authors noted that most patients who have recurrent glenohumeral instability can be classified into one of two large groups.

The first group is characterized by a history of definite trauma, initiating a problem of unidirectional shoulder instability. The shoulders of these patients usually are found to have a rupture of the glenohumeral ligaments at the glenoid attachment, which often is referred to as a Bankart lesion. Finally, these shoulders frequently need surgery to achieve stability. To help remember this grouping, they use the acronym TUBS (for trauma, unidirectional, Bankart, and surgery), a Traumatic event gives rise to Unidirectional anterior instability with a Bankart lesion, and Surgery is usually required to regain stability. In these patients the shoulder is “torn loose”. The glenohumeral joint has lost the stabilizing effect of the anterior inferior glenohumeral ligament complex when the arm is in abduction, extension, and external rotation. It has also lost the fossa-deepening effect of the anterior glenoid labrum, which may also predispose the joint to instability. Diagnosis is based on the history of a traumatic event with the arm in abduction, external rotation, and extension, as well as the demonstration of instability or ap-

prehension or both when the arm is placed at the limit of abduction, extension, and external rotation (where the normal ligament shoulder become tight). Repair optimally consists of the secure reattachment of the labrum and the inferior glenohumeral ligament complex to the lip of the anterior inferior glenoid without any capsular tightening. This restores the capsuloligamentous constraint mechanism as well as the fossa-deepening effect of the labrum. Attaching the ligaments and labrum to the scapular neck fails to deepen the glenoid.

The patients in the second large group have no history of trauma – thus, they have atraumatic instability. These patients are much more prone to have multidirectional instability that is bilateral. Rehabilitation, especially strengthening of the rotator cuff, is the first line of treatment. If an operation is performed, laxity of the inferior part of the capsule must be managed with a capsular shift. The acronym that the authors use for this group is AMBRI (for atraumatic, multidirectional, bilateral, rehabilitation, and inferior). Two years later, Matsen and Harryman [84] described this second group as follows below.

The “torn loose” TUBS situation is in contrast to the “born loose” or AMBRII syndrome in which there is an Atraumatic onset of Multidirectional instability that is accompanied by Bilateral laxity. Rehabilitation helps restore glenohumeral stability by augmenting the concavity compression mechanism presented earlier. If operation is necessary a global capsulorrhaphy is performed, which tightens the Inferior capsule and the rotator Interval. This repair enhances glenohumeral stability by enhancing the limited joint volume mechanism.

7.9 Classification of shoulder instability according to Gerber et al. [44, 45, 118]*

Hyperlaxity can be combined with instability, however it is not a primarily disease, but it characterises an individual constitution. Therefore multidirectional instability should be distinguished from multidirectional hyperlaxity and should be considered into a classification of shoulder instability. This differentiation of laxity and instability lead to the following classification:

- 1) Chronic locked dislocation
- 2) Unidirectional instability without hyperlaxity

- 3) Unidirectional instability with hyperlaxity
- 4) Multidirectional instability without hyperlaxity
- 5) Multidirectional instability with multidirectional hyperlaxity
- 6) Uni- or multidirectional voluntary instability

This simple form of the classification has been helpful to determine diagnostic and therapeutic strategies and to establish a basis of communication with other orthopaedists. Description of static instabilities and recognition of osseous lesions to this classification may be an additional aid. A basis for this classification is that hyperlaxity (either generalized or of the shoulder) is an individual trait and not pathologic. However, hyperlaxity may be a factor of risk for having shoulder problems develop.

■ **Class A: static instabilities**

Static instabilities are defined by absence of classic symptoms of instability yet, the humeral head is displaced and fixed superior, anterior, or posterior relative to its normal position on the glenoid fossa. The diagnosis is radiological, not clinical. Static instability may remain asymptomatic for a long period. If treatment becomes necessary, the consequences are entirely different from those imposed by a diagnosis of dynamic instability. In addition, these static instabilities currently are difficult to treat successfully. Static instabilities can co-exist with dynamic instabilities (recurrent anterior instability in a massive cuff tear with superior humeral migration) and then require a decision as to which instability has priority in treatment. Usually the more disabling instability is dynamic and is best treated initially.

– **Class A1: static superior subluxation**

Static superior migration of the humeral head is present if the normal distance between the undersurface of the acromion and the most cranial aspect of the humeral head on an anteroposterior (AP) radiograph with the shoulder in neutral rotation is decreased. Seven millimetres is currently the value used to define static superior subluxation. The cause of cranial migration of the humeral head seems to be insufficiency of the infraspinatus in the presence of a supraspinatus tear. Isolated supraspinatus, isolated infraspinatus, or combination tears of the supraspinatus and subscapularis tendons do not cause static superior instability. Loss of the acromio humeral distance to less than 7 mm also is associated

with loss of strength of abduction and of external rotation. In addition, such static superior subluxation carries a poor prognosis for repair of the rotator cuff tear and some consider it to be a predictor of an irreparable tear. In the current authors' experience, superior static subluxation essentially is irreversible by conventional repair techniques.

– **Class A2: static anterior subluxation**

Static anterior subluxation is a fixed anterior position of the humeral head on the glenoid fossa and often is manifest clinically as moderate to severe shoulder pain, partly caused by impingement under the coracoid and coracoacromial arch and loss of anterior elevation. It usually is detected on computed tomography (CT) scans or MRI scan taken with the arm in neutral rotation but occasionally may be evident on axillary lateral radiographs. Static anterior subluxation usually is not associated with recurrent anterior shoulder instability.

The cause of static anterior subluxation is not well-established. To develop a static anterior subluxation without any previous operation, it seems that a combination of a subscapularis tear, a supraspinatus tear, and fatty degeneration of the infraspinatus muscle is necessary. An isolated tear of the subscapularis tendon and posterosuperior tears usually do not lead to anterior static subluxation.

Current treatment attempts include repair of the supraspinatus tendon plus pectoralis major transfer with the transferred tendon being rerouted behind the conjoined tendon or a Latarjetlike procedure to provide better anterior stability. In the current authors' experience to date (2002), static anterior subluxation has been irreversible with soft tissue procedure.

– **Class A3: static posterior subluxation**

Static posterior subluxation is a fixed posterior position of the humeral head on the glenoid fossa on CT or MRI scans with the arm in neutral rotation. This condition is most frequently but not always associated with congenital dysplasia of the glenoid or with degenerative glenohumeral joint disease. Static posterior subluxation may be associated with glenoid deformations such as classified by Walch and co-workers. This static subluxation may be

present without any rotator cuff deficiencies. To date, most authors have found static posterior subluxations to be irreversible.

– **Class A4: static inferior subluxation**

Inferior subluxation of the shoulder is characterized by straight inferior translation of the humerus relative to the glenoid fossa. This may occur from trauma, neurologic injury, septic arthritis, or inadequate restoration of humeral length after arthroplasty. Inferior subluxation after trauma and surgery, if not associated with permanent nerve injury, usually resolves within 6 weeks but always resolves within 2 years. Conversely, inferior subluxation caused by infection tends to result in joint surface destruction and only successful treatment of infection results in resolution of the inferior subluxation. Inferior subluxation caused by neurologic injury shortening of the humerus also remains symptomatic unless the primary problem can be resolved.

Subluxation must be distinguished from traumatic inferior dislocation, which occasionally is encountered as luxatio erecta. This entity is part of the dynamic instabilities that can momentarily be reduced and may recur.

■ **Class B: dynamic instabilities**

Dynamic instabilities are characterized by subjective loss of normal glenohumeral joint stability and momentaneous but restorable loss of joint congruency. Dynamic instabilities always are initiated by trauma. This may be repetitive microtrauma or one macrotraumatic event. Being able to passively displace the humeral head out the glenoid fossa during physical examination does not describe instability but is a semiquantitative assessment of hyperlaxity. Such translation testing may be a sign of instability if it is significantly different from the asymptomatic side or if it is associated with symptoms of apprehension.

Typical pathoanatomy is associated with each of the dynamic instabilities. All can be associated with major bony defects of the glenoid fossa but it often is difficult to assess the size and thereby the relevance of such lesions. If the superoinferior extension of a glenoid rim lesion is larger than half of the largest AP diameter of the glenoid, instability can be subclassified as with bony lesion, if this is not the case, it can be subclassified as without bony lesion.

– **Class B1: chronic, locked dislocation of the shoulder**

Chronic, locked shoulder instability invariably is caused by major trauma most frequently incurred in a motor vehicle accident, a fight, or during an epileptic seizure. Anterior or posterior dislocation may be associated with a fracture of the surgical neck region that must be recognized before treatment is initiated.

Characteristic lesions

The most important lesions (Class 1.1) of locked shoulder dislocation are the compression fractures of the humeral head and stable contact of this lesion with the articular surface of the glenoid, whereas the majority of the cartilage of the humeral head has no contact with the glenoid fossa. The posterolateral Malgaigne or Hill-Sachs compression fracture is found in anterior dislocation, whereas an antero-medial (McLaughlin) compression fracture is found in posterior dislocation. Capsular distension is usual; rotator cuff tears are rare. If the humeral head remains outside the glenoid fossa, a disuse atrophy of the humeral head develops. Although these lesions can be identified with radiographs, they are seen best on CT scans or arthrogram CT scans. Chronic locked dislocations may be reduced and can recur. The essential lesion seems to be the humeral head defect. As opposed the humeral head compression fracture associated with recurrent dislocation, the humeral head defect associated with chronic, locked dislocation often needs to be addressed during operative repair of long-standing lesions in patients who do not respond to conservative treatment. A large glenoid fossa lesion rarely is found.

– **Class B2: unidirectional instability without hyperlaxity**

Unidirectional instability without hyperlaxity may be the most frequent form of recurrent instability, accounting for 60% of the patients treated at the current authors' institution. Either there is a distinct injury with a frank dislocation requiring reduction by another person, or a painful subluxation followed by recurrent episodes of instability. On physical examination, the main finding is a positive apprehension test, either anterior or posterior. There is no sulcus sign and the results of the anterior and the posterior drawer tests are negative. For anterior instability, however, the hyperabduction test recently described by Gagey and Gagey is posi-

tive indicating incompetence of the inferior glenohumeral ligament complex.

Characteristic lesions

A traumatic lesion (Class 2.1) involving the inferior glenohumeral ligament complex can cause anterior instability without hyperlaxity. Lesions may be at the humeral insertion site, midsubstance, at the glenoid insertion site, involving the labrum and/or the anterior glenoid rim or rarely at the humeral and the glenoid insertion sites. In addition, the passage of the humeral head over the anterior glenoid rim causes a posterolateral humeral head defect that is diagnostic of anterior instability. The severity of the two lesions often are related as very large Hill-Sachs lesions often associated with small lesions of the anteroinferior capsulolabrum, whereas large capsulolabral lesions often are associated with small Hill-Sachs lesions. Posterior instabilities without hyperlaxity have posterior capsulolabral lesions (posterior Bankart) more frequently than previously recognized. These lesions, less severe than anterior capsulolabral lesions, also can be accompanied by an antero-medial humeral head compression fracture (McLaughlin lesion).

These instabilities usually can be treated with success by repair of the capsulolabral lesion. If this repair is correct technically, the results of arthroscopic procedures may be comparable with those of open repair. Finally, if a glenoid rim lesion is present and of the size defined above, either glenoid reconstruction using iliac bone or a bone block procedure may be necessary to restore stability.

— **Class B3: unidirectional instability with hyperlaxity**

Unidirectional instability with hyperlaxity accounts for approximately 30% of the patients with instability treated at the authors' institution. The injury is of variable severity. It includes dislocations requiring reduction, dislocations reduced by the patient, and painful subluxation followed by frequent and almost pain-free episodes of recurrence, generally self-treated. The position of discomfort occurs with the shoulder either in external rotation and abduction, or in anterior elevation. The physical examination shows either a positive anterior or a positive posterior apprehension test, but not both. There is a clear sulcus sign and the anterior and the

posterior drawer tests are positive. The drawer test in the direction of the instability may be associated with apprehension. In anterior instability the hyperabduction test is positive, and in posterior instability internal rotation of the 90° abducted arm usually is increased over the opposite asymptomatic side. If on physical examination the contralateral shoulder is hyperlax, the instability is classified as anterior or posterior with hyperlaxity.

Characteristic lesions

A traumatic lesion (Class 3.1) of the anteroinferior capsulolabrum also may cause anterior instability with hyperlaxity. This lesion may be similar to those without hyperlaxity. With inferior hyperlaxity, an opening in the rotator interval is expected and is addressed best during surgery. If external rotation is increased dramatically beyond normal, a dysplasia of the middle glenohumeral ligament is characteristic. It may be difficult to anatomically reinsert this structure during surgery. Typically, a small traumatic lesion of the anteroinferior labrum or a longitudinal fissure or other mild detachment is present. The capsular volume is large and the surgeon may be tempted to reef the capsule but should not. A Hill-Sachs lesion often is present, but may be small. Posterior instabilities with hyperlaxity have only minimal labral lesions. Most frequently, the lesions are barely recognizable. The patient may have subluxated the shoulder by a movement of anterior elevation and internal rotation, but he or she is unable to subluxate the shoulder in a different direction. The patient also complains exclusively of symptoms in this position. The sulcus sign is not very marked, but persists in internal rotation. This implies that the posteroinferior capsule is functionally incompetent and needs to be addressed surgically. The variant of the instability with a relevant glenoid fossa is rare.

– **Class B4: multidirectional instability without hyperlaxity**

Multidirectional instability without hyperlaxity is even rarer than multidirectional instability with hyperlaxity. Typically, the patient reports at least two significant injuries or instability episodes. The injuries almost invariably were of sufficient severity to warrant medical consultation. The patient is uncertain which position is the most uncomfortable. He or she is not comfortable with the

shoulder in external rotation and abduction, with the shoulder in anterior elevation and internal rotation. On physical examination, there is a positive anterior and a positive posterior apprehension test, and although one apprehension test may be more positive, both clearly are not normal. There is no sulcus; external rotation of the adducted arm is not beyond 70°. The drawer tests show small displacement and therefore are negative and may be associated with apprehension. If there is no hyperlaxity, but subjective instability and history and physical examination fail to positively identify the direction of instability, multidirectional instability without hyperlaxity must be ruled out.

Characteristic lesions

Multidirectional instability without hyperlaxity has typical lesions of anterior and posterior instability without hyperlaxity (Class 4.1). The bony and the capsulolabral lesions are present. The labrum may be avulsed anterior or posterior making open surgery difficult. Optimal treatment of this condition is complex and may require staged procedures of anterior and posterior repair. Surgery should attempt to restore the anatomy by reinserting the capsulolabral structures at their anatomic sites under as normal tension as possible.

– **Class B5: multidirectional instability with hyperlaxity**

Multidirectional instability with hyperlaxity is the classic syndrome initially described as multidirectional instability. Today, the majority of cases described as multidirectional instability likely are unidirectional instabilities with hyperlaxity, which is much more common than true subjective multidirectional instability. Although unidirectional instability with hyperlaxity accounts for approximately 30% of the cases of instability, true multidirectional instability with hyperlaxity accounts for less than 5%. The onset of symptoms may be associated with a significant trauma, but even a minor injury may produce multidirectional instability with hyperlaxity. Patients often are females who have had repetitive microtrauma in childhood or adolescence (gymnasts, swimmers). Most patients have signs of generalized hyperlaxity, which sometimes may be limited to both shoulders. This hyperlaxity may be severe and patients already may have had surgery for ankle inju-

ries, knee ligament lesions, or other joint instabilities. The symptoms may present as anterior, posterior, and often inferior. The patient has no control of the position of the humeral head relative to the glenoid as opposed to the voluntary type of instability, where the patient changes the relative position of humerus and glenoid at will. Subluxation may occur many times a day. The instability events are almost invariably subluxations, reduced by the patient, and frequently are not very painful. At physical examination, positive anterior, posterior, and inferior drawer tests show apprehension in at least two directions and external and internal rotations are usually increased dramatically beyond normal.

Characteristic lesions

Multidirectional instability with hyperlaxity typically has the lesions of anterior and posterior instability and the characteristics of hyperlaxity (Class 5.1). There are only minimal skeletal lesions, but the capsular lesions are present including widening of the rotator interval, a patulous capsule, and stretched ligaments. Conservative treatment often is successful. This may be attributed to the minimal structural lesions being well compensated for by rehabilitation of the shoulder muscles.

– **Class B6: unidirectional or multidirectional instability with voluntary reduction (voluntary instability)**

The form of instability, which was termed unidirectional or multidirectional with voluntary reduction, previously has been called voluntary and habitual, but these latter terms have caused confusion in recognizing this form of instability. There are children and adults whose shoulders start to dislocate anterior and/or posterior and/or inferior often without the patient noticing. However, early in the course of the disease the patient learns how to reduce the shoulder and will present to the physician with a manoeuvre of reduction that should not be misinterpreted as a manoeuvre of dislocation. With time, the patient learns how to position the shoulder so that it dislocates and wilfully reduces the shoulder. To the patient, this reduction manoeuvre often is the instability because the prior subluxation was not noticed. The capability of subluxating the shoulder may be shown but it is not associated with any psychological disturbance. The voluntary dislocations often

are bilateral and usually are pain-free. The reduction manoeuvre may be associated with pain and discomfort. Children who have learned to voluntarily reduce and dislocate their shoulders have an excellent prognosis if untreated for relief of pain, as in terms of function and psychological development. Adults often have been able to dislocate their shoulders during childhood.

Although excellent success may be possible with conservative treatment, the current authors have not had universally satisfactory outcomes. This especially has been the case with the posterior variant. Conversely, it has shown that patients with this form of voluntary instability can be treated successfully operatively.

■ **Class C: voluntary dislocations**

There are three types of individuals who can dislocate their shoulders at will. The first group is comprised of individuals who do not suffer but are surprised to realize that they can dislocate and relocate their shoulder at will. This condition should not be called instability because the individual has not lost control of the stability of his or her shoulder. In fact, the individual has more control over the shoulder than usual, because the position of the shoulder can be maintained whether the humeral head is in the glenoid fossa or outside. There is no need for treatment of these patients. If left untreated, these patients never develop degenerative changes of their joint; therefore, no treatment is the best option.

The second group is comprised of patients who suffer involuntary dynamic instability and subsequently learn to voluntarily subluxate (and reduce) their joint. They are treated best according to their dynamic instability as under B6.

A third very small but important to identify group of patients can dislocate their joint and use this to gain attention or to mask a major psychiatric problem. Typically, these are young females. Wilful instabilities should raise the suspicion of the variant, which is not an expression of shoulder instability, but of psychiatric illness. Accordingly, these patients should not be treated by an orthopaedic surgeon, but by a psychiatrist.

7.10 Classification of shoulder instability according to Bayley et al. [5, 6]*

The system of shoulder dislocation classification which the authors have developed at the Royal National Orthopaedic Hospital and used over the years is anchored by three basic or **polar groups**:

I Traumatic structural

II Atraumatic structural

III Habitual nonstructural (muscle patterning)

The system works well for posterior and anterior dislocations and also for subluxations, and complete dislocations. It can be expanded as follows:

I Traumatic structural

- a) Acute*
- b) Persistent*
- c) Recurrent*

II Atraumatic structural

- a) Recurrent*

III Habitual nonstructural

- a) Recurrent*
- b) Persistent*

The diagnosis of each type is made on the basis of a careful history and clinical examination followed by arthroscopy and, when necessary, functional electro-myography. I shall show examples of each type. The history takes account of the degree of trauma required to cause the first dislocation and whether the displacement was complete and requiring formal reduction or incomplete and spontaneously reducing. The clinical examination looks for signs of ligamentous laxity and specifically for evidence of abnormal muscle pattern recruitment. The presence or absence of articular surface damage is defined by arthroscopy and functional electromyographic studies look for evidence of abnormal muscle pattern recruitment in patients in whom clinical examination has been negative but suspicion of a nonstructural instability is high. The characteristics of each of the three polar groups are broadly as follows:

I Traumatic structural

- Significant trauma
- Often a Bankart's defect
- Usually unilateral
- No abnormal muscle patterning

II Atraumatic

- No trauma
- Structural damage to the articular surfaces
- Capsular dysfunction
- No abnormal muscle patterning
- Not uncommonly bilateral

III Habitual nonstructural (muscle patterning)

- No trauma
- No structural damage to the articular surfaces
- Capsular dysfunction
- Abnormal muscle patterning
- Often bilateral

Similarities between polar groups II and III will be self-evident. Furthermore, a careful doctor, when examining patients in clinic and investigating them by arthroscopy, will soon discover that there can be much overlap between groups. For example, some patients in polar groups III do give a history of injury of varying degrees of severity. Other patients will have a clear cut muscle patterning problem and will also demonstrate clear cut articular surface damage at arthroscopy. Appreciating these variations it becomes clear therefore that in addition to some patients fitting securely into the three polar groups, there are others that seem to have – and indeed do have – a dual pathology.

One could perhaps characterise this situation by drawing three overlapping circles. However this model tends to compress the interlocking parts of the circles and might compound rather than relieve confusion. The authors have preferred to use the model of a triangle since it better highlights the continuum of presentation which can occur in between the three polar groups. It is possible to fit patients into the three polar groups or somewhere along the lines which join them. We studied 223 shoulders with instability and defined the two sub groups on each of the three axes (Fig. 27).

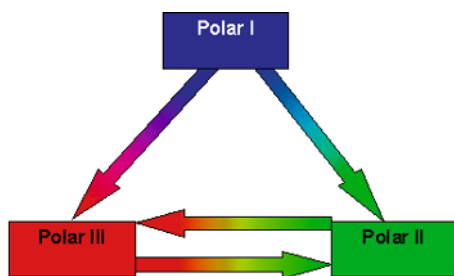


Fig. 27. Classification of shoulder instability. (From [5])

7.11 Types of lesions of anterior inferior shoulder instability according to Habermeyer [78] (Fig. 28)

■ Bankart line

- *Classic Bankart lesion*: failure in continuity at the transition zone between cartilage and labrum without detachment of periosteal ligament insertion.
- *Double labral lesion*: complete detachment of the labrum from the glenoid rim, the insertion of the inferior glenohumeral ligament at the limbus is intact. This means a double detachment of the labrum from the glenoid rim as well as the inferior glenohumeral ligament.
- *Bony Bankart lesion*: bony avulsion fracture of the glenoid rim combined with detachment of the labrum and the inferior glenohumeral ligament.

■ Perthes line

- *Classic Perthes lesion*: complete detachment of the labrum together with the inferior glenohumeral ligament from the glenoid rim, in which the inferior glenohumeral ligament is detached subperiosteal from the scapular neck (periosteal pouch).
- *ALPSA lesion* [104]: deperiostation of the labrum and the inferior glenohumeral ligament from the anterior scapular neck with the development of a scar formation at the base of the periosteal pouch.




Fig. 28. Types of lesions of anterior inferior shoulder instability. A Normal. B Bankart line. C Perthes line. D Capsular line. E GLAD lesion

- *Triple labral lesion*: combined lesion with avulsion of the labrum from the glenoid rim, avulsion of the labrum from the inferior glenohumeral ligament and deperiostation of the inferior glenohumeral ligament from the scapular neck.
 - *Extralabral ligament lesion*: avulsion of the inferior glenohumeral ligament from the glenoid rim, in which the labrum remains widely intact.
- **Capsular line**
- *Non-Bankart lesion*: This lesions corresponds to the described special form by Uththoff, in which the inferior glenohumeral ligament inserts at the medial scapular neck and not at the labrum. An anterior capsular pouch is developing. The labrum is often hypoplastic, rounded and flattened. It will be found in patients with habitual instability.
 - *Substantial defect of the inferior glenohumeral ligament*: intraligamentous defects, elongation and scarification of the inferior glenohumeral ligament developing into a capsular pouch, comparable with a hernia, often accompanied with synovitis. Substantial defects of the inferior glenohumeral ligament may be combined with labral lesions.
 - *Quattro labral lesions*: avulsion and wear of the complete labrum ligament complex with a widely loss of labral ligament structures.
 - *HAGL lesion* [137]: humeral avulsion of the inferior glenohumeral ligament, rarely but often combined with subscapularis tendon tears.
- **GLAD lesion** [105]: chondral lesion at the transition zone to the labrum without labral detachment. This lesion is caused by a direct trauma and causes chronic pain but no considerable instability.

7.12 Classification of posterior shoulder instability according to Ramsey and Klimkiewicz [108]

The authors describe an anatomically based classification of recurrent posterior subluxation, as opposed to the more traditional etiology-based methods of classification, facilitates treatment by defining the pathologic process that produces the instability. The salient features of this anatomic-based classification system are summarized:

- **Posterior dislocation**
 - Acute posterior dislocation
 - Chronic (locked) posterior dislocation
- **Recurrent posterior subluxation**
 - Volitional
 - Psychogenic
 - “Learned”
 - Dysplastic
 - Glenoid retroversion
 - Humeral head retroversion
 - Acquired
 - Soft tissue deficiency
 - Bony deficiency
 - Scapulothoracic dysfunction

Acute posterior dislocation

Acute posterior dislocations are rare, accounting for approximately 5% of all dislocations. Direct trauma to the front of the shoulder, a posteriorly directed force on an adducted arm, and indirect muscle forces (seizure or electrical shock, all can cause posterior dislocation.

Recurrent posterior subluxation

Volitional recurrent posterior subluxation

Voluntary recurrent posterior subluxation describes a group of patients with an underlying conscious or unconscious ability to subluxate their shoulder by using abnormal patterns of muscular activity. In this group of patients there is no initial anatomic pathology in the glenohumeral joint. Over time, stretching of the glenohumeral ligaments can occur

such that an involuntary component to the instability develops. Some of these patients have underlying psychiatric disorders as a cause for wilful and voluntary posterior subluxation. Rowe labelled these patients habitual dislocators. Habitual dislocators are distinguished from other patients with posterior subluxation, who may have learned how to reproduce their instability, by their wilful desire to subluxate their shoulders. Despite the best intentions of the treating physician, habitual dislocators will frustrate all treatment efforts (operative or nonoperative) because of their abnormal psychological need to subluxate their shoulder. The overwhelming process in this group of patients is psychological and treatment should be directed according their psychological needs. Surgical intervention in this group is contraindicated.

A second group of patients can voluntarily reproduce their instability, but they have no underlying psychological need to do so. This is a *learned* behaviour that over time may develop an involuntary component. It is this involuntary component that is bothersome to the patient and often initiates evaluation by a physician.

Electromyographic evaluation of patients who can voluntarily subluxate their shoulders demonstrate selective inhibition of certain muscle groups that results in an unbalanced force couple, leading to posterior subluxation. Activation of the deltoid and the pectoralis major without opposition from the posterior short rotators, resulting in the humeral head being pushed posteriorly, was identified in several patients. Conversely, Pande demonstrated unopposed activation of the posterior short rotators and posterior deltoid that in effect pulls the humeral head posteriorly.

Dysplastic recurrent posterior subluxation

Dysplastic bony architecture of the glenohumeral joint is another uncommon cause of recurrent posterior subluxation. Localized posterior glenoid hypoplasia, increased glenoid retroversion, and increased humeral head retrotorsion are potential causes of recurrent posterior subluxation.

Acquired recurrent posterior subluxation

The largest group of patients with recurrent posterior subluxation acquires posterior instability as a result of repetitive microtrauma or as a result of a single traumatic event. Traumatic events leading to both osse-

ous and soft-tissue abnormalities can result in subsequent posterior instability. Because the etiology of this instability is not as crucial to treatment as the underlying pathologic lesion that results in recurrent posterior subluxation, we define acquired recurrent posterior subluxation based upon the anatomic lesion. Lesions of the capsule, labrum, rotator cuff musculature, and glenoid can contribute to recurrent posterior subluxation. The most consistent deficiency relates to redundancy of the posterior capsule. Additionally, dysfunction of normal scapulothoracic mechanics can place the glenohumeral joint at risk for recurrent instability.

Unlike the anterior capsule the posterior capsule is thin. The posterior capsule and the buttress provided by the posterior glenoid labrum are the primary static stabilizers to unidirectional posterior translation. Dynamic posterior stability is conferred by the rotator cuff musculature. The most consistent finding in patients with recurrent posterior subluxation is a patulous posterior capsule. The posterior capsule either stretches over time or tears as a result of single event trauma and heals in an elongated position, thereby increasing capsular volume. Posterior labral tears have been described with recurrent posterior subluxation; however, they are generally degenerative tears, rather than the rare capsular and labrum avulsion (i.e., reverse Bankart lesion).

Acquired posterior subluxation is less commonly caused by *posterior glenoid rim deficiency*. Although it is uncommon, it does exist and should be investigated with imaging studies if suspected. The relation between the degree of posterior glenoid erosion and recurrent posterior subluxation has not been established. It seems reasonable to assume that a large posterior glenoid defect will compromise the buttress effect of the glenoid to posterior translation.

Dysfunction of scapulothoracic rhythm may compromise the stability of the glenohumeral joint. The serratus anterior muscle plays a key role in scapulothoracic rhythm. Paralysis of this muscle results in scapular winging and loss of power in elevation that potentially may influence glenohumeral stability.

In patients with scapular winging from paralysis of the serratus anterior, glenohumeral instability may result from altered scapulothoracic mechanics. In patients with glenohumeral instability and lesser degrees of scapulothoracic dysfunction, it is unclear whether instability is the result of altered scapulothoracic mechanics or the cause of it.

7.13 Classification of glenoid rim lesions according to Bigliani et al. [10] (Fig. 29)*

Type I: united fragment attached to separated labrum

Type II: malunited fragment detached from labrum

Type III A: anterior glenoid deficiency < 25%

Type III B: anterior glenoid deficiency > 25%

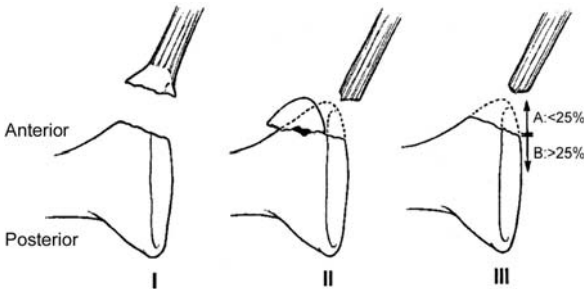


Fig. 29. Classification of glenoid rim lesions. (From [10])

7.14 Arthroscopic classification of Hill-Sachs lesions according to Calandra et al. [19]*

Calandra et al. [19] undertook a prospective study using arthroscopy to determine the intraarticular derangement caused by initial anterior shoulder dislocations in 32 patients.

They graded the Hill-Sachs lesions arthroscopically:

- **Grade I** is a defect in the articular surface down to, but not including, the subchondral bone.
- **Grade II** includes the subchondral bone.
- **Grade III** signifies a large defect in the subchondral bone.

7.15 Classification of significant Hill-Sachs lesions according to Burkhart and De Beer [18]

Dynamic arthroscopic examination of the shoulder as it went into abduction and external rotation revealed the geometric etiology of the symptoms: there was an articular-arc deficit on the humeral side with an engaging Hill-Sachs lesion (Fig. 30a). That is, with the arm in abduction of 90° , if the shoulder was externally rotated more than 30° , the Hill-Sachs lesion would engage the anterior corner of the glenoid, and the patient would sense that engagement as a popping or catching sensation.

The authors define an **engaging Hill-Sachs lesion** as one that presents the long axis of its defect parallel to the anterior glenoid with the shoulder in a functional position of abduction and external rotation, so that the Hill-Sachs lesion engages the corner of the glenoid (Fig. 30b). A **nonengaging Hill-Sachs lesion** is one that presents the long axis of its defect at a diagonal, nonparallel angle to the anterior glenoid with the shoulder in a functional position of abduction and external rotation (Fig. 30c), or one in which the “engagement point” occurs with the arm in a nonfunctional position of shoulder extension or of low shoulder abduction ($<70^\circ$ abduction). Because this first type of nonengaging Hill-Sachs lesion passes diagonally across the anterior glenoid with external rotation, there is continual contact of the articular surfaces and nonengagement of the Hill-Sachs lesion by the anterior glenoid. Such shoulders are reasonable candidates for arthroscopic Bankart repair because they do not have a functional articular-arc deficit.

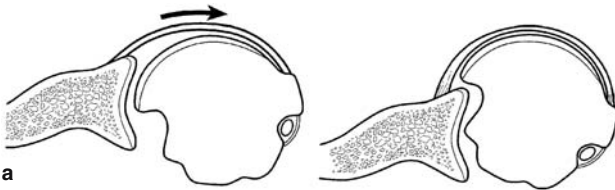


Fig. 30. Classification of significant Hill-Sachs lesion. **a** This large Hill-Sachs lesion involves a large portion of the humeral articular surface. In this case, even without a Bankart lesion, the Hill-Sachs lesion can engage the anterior corner of the glenoid, causing symptoms similar to subluxation. The authors call this an articular arc deficit

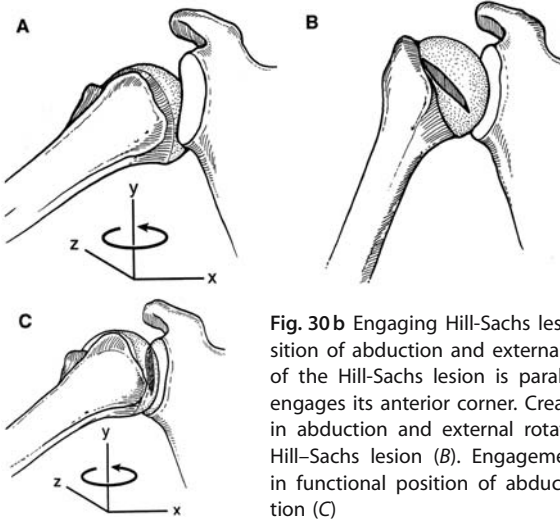


Fig. 30b Engaging Hill-Sachs lesion. In a functional position of abduction and external rotation, the long axis of the Hill-Sachs lesion is parallel to the glenoid and engages its anterior corner. Creation of lesion with arm in abduction and external rotation (A). Orientation of Hill-Sachs lesion (B). Engagement of Hill-Sachs lesion in functional position of abduction and external rotation (C)

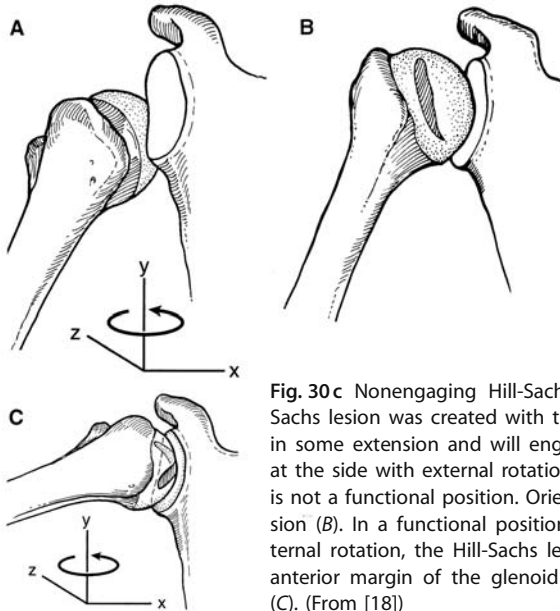


Fig. 30c Nonengaging Hill-Sachs lesion (A). This Hill-Sachs lesion was created with the arm at the side and in some extension and will engage only with the arm at the side with external rotation and extension, which is not a functional position. Orientation of Hill-Sachs lesion (B). In a functional position of abduction and external rotation, the Hill-Sachs lesion is diagonal to the anterior margin of the glenoid and does not engage (C). (From [18])

Obviously, for every Hill-Sachs lesion, there is a position of the shoulder at which the humeral bone defect will engage the anterior glenoid. The symptoms are greatest if the engagement occurs with the shoulder in a functional position, which typically involves a combination of flexion, abduction, and external rotation. However, the authors have found that many Hill-Sachs lesions engage only when the shoulder is in some degree of extension, which is a nonfunctional position for everything except throwing a baseball, or in abduction of less than 70° , which is also a nonfunctional position. Therefore, we define this second group of Hill-Sachs lesions as nonengaging.

The orientation of the Hill-Sachs lesion is determined solely by the position of the humeral head relative to the glenoid when it becomes indented by the glenoid. This can occur with the shoulder in any degree of abduction or with the arm at the side and is not necessarily the degree of abduction in which the shoulder dislocated. For example, the shoulder may dislocate with the arm at 90° of abduction, and then assume a position of 0° abduction after the dislocation. Hence, the Hill-Sachs lesion that becomes indented with the arm at the side with some extension of the shoulder will be located more vertically and superiorly than the lesion that indents with the shoulder abducted and externally rotated. This former lesion (the Hill-Sachs that becomes indented with the arm at the side) is generally a nonengaging lesion.

7.16 Stages of evolution of lesions of the labrum-ligament complex in posttraumatic anterior shoulder instability according to Gleyze and Habermeyer [50]*

Each stage is defined by the presence of a new lesion (Fig. 31).

- **Stage 1:** The first stage is marked by an isolated simple lesion at the labral attachment, that is, an isolated labral detachment with a present periosteal hinge (Bankart lesion). The first anterior hinge is the only structure to collapse in the first stage.
- **Stage 2:** The second stage is marked by the appearance of a double lesion on the IGHL attachment; it is a combined labral and IGHL detachment lesion. The IGHL detachment is deformed by a continuous

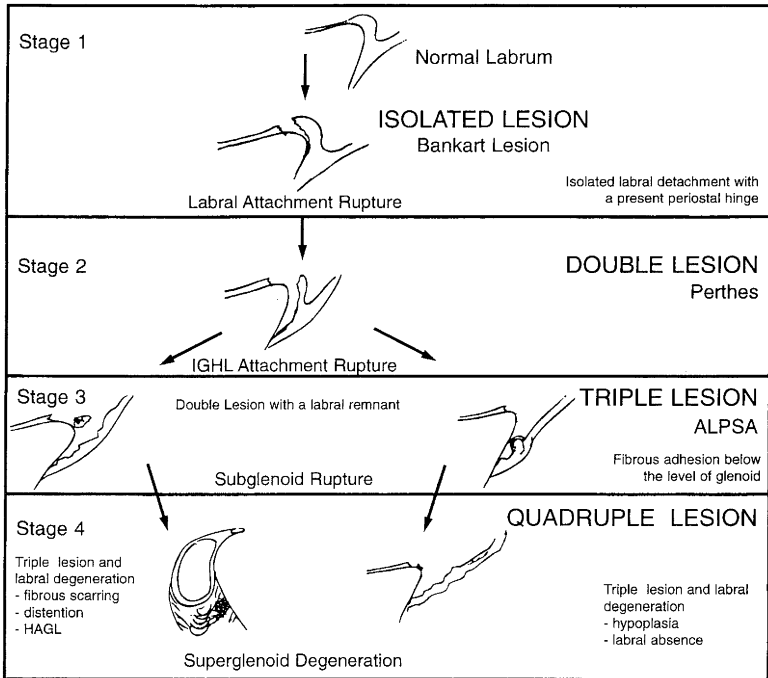


Fig. 31. Chronological classification of successive lesions into four stages

sublabral periosteal extension (Perthes lesion). This stage represents the disruption of the second anterior hinge.

- **Stage 3:** The third stage is marked by a triple lesion and progressive degenerative changes of the detached structures below the level of the glenoid. At the very sites where the two previous lesions might have healed, the formation of fibrous scarring occurs.
- **Stage 4:** The fourth stage is marked by a quadruple lesion. The degenerative process is extended above the level of the glenoid and progressive disappearance of the labrum-ligament complex begins.

7.17 Classification shoulder injury/dysfunction (impingement and instability) in the overhead or throwing athlete according to Kvitne et al. [73] and Jobe et al. [66]

Based on the information obtained through a detailed history, physical examination, and preliminary diagnostic arthroscopy, most throwing athletes with refractory anterior shoulder pain can be classified into one of four groups.

- **Group I**
 - Pure impingement
 - No instability
- **Group II**
 - Primary instability because of chronic labral and capsular microtrauma
 - Secondary impingement
 - A. Internal
 - B. Subacromial
- **Group III**
 - Primary instability because of generalized ligamentous hyperelasticity
 - Secondary impingement
 - A. Internal
 - B. Subacromial
- **Group IV**
 - Pure instability (traumatic)
 - No impingement

Group I

These overhead or throwing athletes are usually older and have shoulder pain associated with pure primary impingement, but they have no glenohumeral joint instability. Impingement testing elicits pain localized about the involved shoulder joint. Instability test are usually negative; however, on occasion, athletes with severe impingement have experienced pain with the apprehension manoeuvre. Because their shoulder is stable, however, the pain is not relieved with the relocation

manoeuvre. Examination under anaesthesia reveals a stable joint. Arthroscopic findings reveal normal anterior and inferior glenoid labrum and glenohumeral ligaments because there is no instability. The subacromial space often is obscured because of inflammation, fibrosis, and dense scarring of the subacromial bursa. In older athletes, usually those older than 35 years of age, the acromion process may have an inferior osteophyte that, together with the coracoacromial ligament, can be seen impinging upon the superior surface of the rotator cuff. There also have been recent cases of subacromial impingement where the only signs of irritation have involved isolated bursal adhesions within the retrocoracoid space or immediately behind the coracoacromial ligament, which may be prominent. When these findings are associated with an unstable glenohumeral joint, however, the patient is considered to have underlying instability as a primary problem and impingement as a secondary phenomenon (Groups IIB, IIIB).

Group II

As a result of repetitive throwing and chronic microtrauma to the capsule and glenoid labrum, these athletes have developed primary instability (subluxations) with either secondary subacromial impingement (Group IIB) or, more likely, secondary internal impingement (Group IIA) of the posterior superior glenoid rim along the undersurface of the rotator cuff. As expected, those athletes with subacromial impingement have pain localized anteriorly or superiorly with impingement testing. On the other hand, those patients with internal impingement experience pain posteriorly or superiorly with impingement testing. By virtue of their underlying primary instability, these athletes have the sensation of pain or discomfort (but not apprehension) with the apprehension manoeuvre. When the relocation manoeuvre is then added, however, their sensation of pain is relieved as the humeral head is reduced, thus relieving the secondary site of impingement.

Unfortunately, an examination under anaesthesia in these patients often is not very helpful, as their primary instability is so subtle that it often remains undetected. Arthroscopic findings are extremely helpful, as these athletes often demonstrate anterior glenoid labral damage, attenuation of the anterior band of the inferior glenohumeral ligament complex, and anterior translation (subluxations) of the humeral head.

Secondary changes associated with the underlying instability may also include undersurface rotator cuff fraying and posterosuperior labral damage in those patients with internal impingement (Group IIA). In those patients with secondary subacromial impingement (Group IIB), arthroscopic findings will include subacromial adhesions, fibrosis, scarring and perhaps wear changes along the coracoacromial ligament.

Group III

These athletes have generalized ligamentous hyperelasticity and, as a result, have developed primary glenohumeral joint instability with secondary impingement. Because of their generalized ligamentous laxity, these patients may demonstrate hyperextension of the elbow, knee, or metacarpal-phalangeal joint, as well as the ability to place the abducted thumb on the forearm. As with those patients in Group II, these athletes will have pain with impingement testing, and pain (but not apprehension) with the apprehension manoeuvre. When the relocation manoeuvre is performed, the pain associated with the apprehension manoeuvre is relieved as the humeral head is held in a reduced position. An examination under anaesthesia often demonstrates bilateral shoulder instability (quite often, these patients exhibit multidirectional instability, with anterior/inferior the most common direction of instability). Arthroscopic findings may include attenuation or hyperplasia of the anterior band of the inferior glenohumeral ligament complex, and attenuation of the anterior joint capsule, but without the associated anterior inferior glenoid labral damage. The humeral head is easily subluxated anteriorly with gentle manipulation, and these patients uniformly exhibit a positive drive-through sign. They also may exhibit undersurface cuff or superior labral fraying (Group IIIA), or adhesions of the subacromial or retrocoracoid soft tissues (Group IIIB) as secondary changes owing to the underlying instability.

Group IV

This last group of athletes has developed pure primary glenohumeral joint instability, but has no signs of impingement. These patients usually give a history of a single traumatic event that has produced an anterior glenohumeral joint subluxation or dislocation. Understandably, most athletes do not sustain this type of shoulder injury while throwing; how-

ever, such trauma may be sustained when an athlete slides forcefully into a base, or may be sustained during a collision with another player. These athletes usually do not have impingement findings. They exhibit pain, apprehension, or both with the apprehension manoeuvre and they experience relief of these symptoms with the relocation manoeuvre. Under anaesthesia, these athletes will have gross unidirectional glenohumeral joint instability (most often anterior). Characteristic arthroscopic findings include a normal rotator cuff, but with anterior glenoid labral damage (Bankart lesion), and a subluxable and dislocatable humeral head.

By classifying these athletes by their particular pathologic processes, a more rational treatment program can be instituted.

7.18 Arthroscopic classification of labro-ligamentous lesions associated with traumatic anterior chronic instability according to Boileau et al. [14]*

The aim of the prospective arthroscopic study of 100 patients was to list and classify the capsuloligamentous lesions associated with traumatic anterior chronic instability at three levels: the glenoid, the humeral and the mid substance of the IGHL.

According to the location (Fig. 32 a) and according to the importance of the detachment of the labrum around the glenoid, the authors distinguished:

Five types of labral lesions

- A “classic” Bankart lesion was present in half of cases (52%); the detachment of the labrum could be located in zone C (9%) or CD (13%) or BCD (30%) (Fig. 32 b).
- A Bankart lesion with detachment of the superior labrum and insertion of the long head of the biceps (SLAP lesion) in zone A were present in 26% of cases (superior extension). The exact location of labral detachment was ABCD (16%) or ABC (10%) (Fig. 32 c).
- A Bankart lesion with detachment of the posterior labrum (posterior extension) in zone E was seen in 8% of cases. The exact location of labral detachment was CDE (2%) or BCDE (6%) (Fig. 32 d).

- A *circumferential labral detachment*, with superior and posterior extension in all zones A, B, C, D, E and F, was present in 6% of the cases. The exact location of labral detachment was ABCDE (1%), ABCDEF (3%), ABCEF (2%) (Fig. 32 e).
- *Absence of Bankart lesion*: In 8% of the cases, no capsulo-ligamentary detachment on the glenoid side was found. In that case, there was either a thin capsule, a distension of capsular tears (Fig. 32 f).

Four types of ligamentous lesions

Were distinguished according to the possible extension of capsulo-ligamentous lesions (Fig. 32 g):

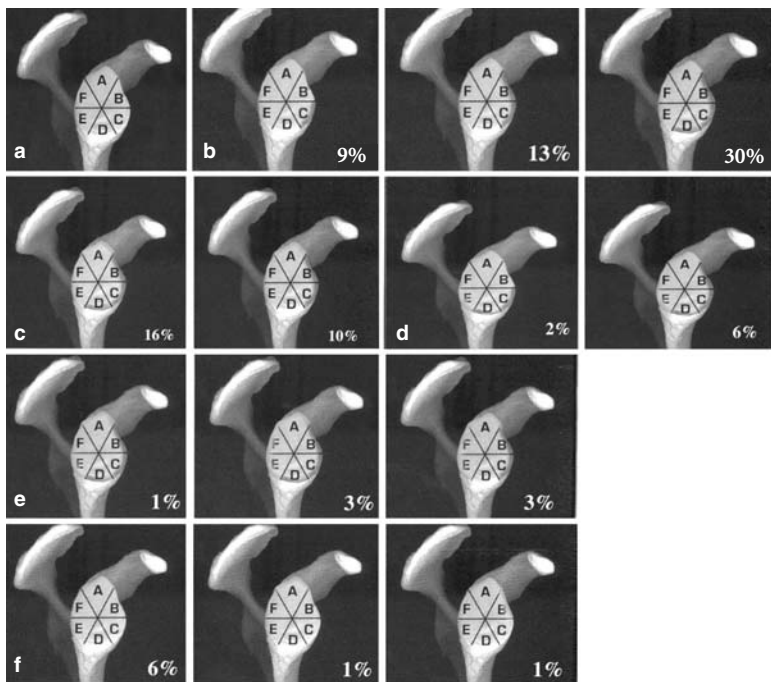


Fig. 32. a The six glenoid sectors (A–F). b Typical "Bankart" lesion. c Superior extension (associated SLAP lesion). d Posterior extension. e Circumferential extension (superior and posterior). f No Bankart lesion (absence of labral detachment)

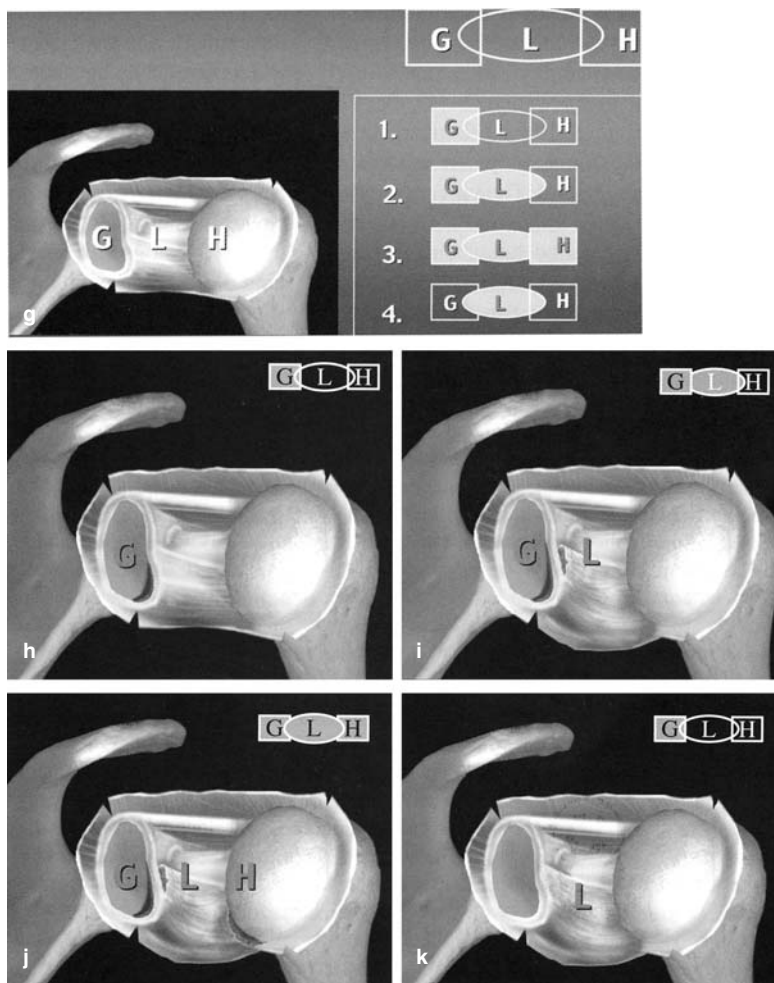


Fig. 32g Ligamentous lesions. **h** Simple lesion (IGHL deinserted from the glenoid). **i** Double lesion (IGHL deinserted from the glenoid+intraligamentous distension or tear). **j** Triple lesion (IGHL deinserted from the glenoid and the humerus+intraligamentous distension or tear). **k** intraligamentous lesion (intraligamentous distension or tear without glenohumeral distension)

- *Isolated detachment of IGHL from the glenoid*, without any ligamentous tears or distension, was the most frequent lesion. In that case, the lesion was labelled with the letter “G” (**Glenoid**). This pure labral lesion was considered to be a “**simple lesion**” (Fig. 32 h).
- *Detachment of the IGHL at the glenoid side associated with intraligamentous distension or tears*. In this case, the lesion was labelled with the letters “G+L” (**Glenoid + Ligament**). This combined labral and ligamentous lesion was considered to be a “**double lesion**” (Fig. 32 i).
- *Detachment of the IGHL at the glenoid side and at the humeral side, associated with intraligamentous distensions or tears*. In that case, the lesion labelled with the letters “G+L+H” (**glenoid + ligament + humerus**). This combined labral and ligamentous lesion **extended to the humeral side** was considered to be a “**triple lesion**” (Fig. 32 j).
- *Distension of the IGHL without any glenoid or humeral capsular detachment*. In this case, the lesion was labelled with the letter “L” (**ligament**). This pure labral lesion was considered to be a “**intragamentous lesion**” (Fig. 32 k).

All the lesions seen can thus be classified: a lesion labelled as BCD/GL, for example, corresponds to a detachment of the labrum in the antero-inferior part, with a ligamentary detachment at the glenoid and a ligamentary distension or tear, etc.

8.1 State of AC-joint space and SC-joint space according to De Palma [31, 28]*

Of significance was the observation that the lateral one third of the clavicles exhibits varying degrees of anterior torsion. This is readily noted if the clavicle is observed with the sternoclavicular and the acromioclavicular joints intact and if the sternum is placed in a vertical position (Fig. 33 a). Sixty-six such specimens obtained from cadavers were studied; the clavicles fell into one of three types, each of which exhibited specific features (Fig. 33 b):

- **Type 1:** in this group the clavicles show the greatest amount of anterior torsion of their lateral thirds. The acromial end is flat and thin and possesses a small articular surface. The plane of the acromioclavicular joint is directed downward and inward; the angle ranges from 10 to 22° , with the average angle being 16° . At the sternal end of the clavicle the plane of the sternoclavicular joint is not far from the vertical and is directed downward and outward. The angle ranges from 0 to 10° , with the average angle being 7.5° .
- **Type 2:** the anterior torsion of the lateral one third of the clavicles of this category is less than that noted in Type 1. Also, the acromial end is stouter and slightly more rounded. The plane of the acromioclavicular joint forms a greater angle with the vertical than that noted in Type 1; the average angle is 26.1° . Of interest is the configuration of the lateral curve of the clavicle, which describes an arc of a circle smaller than the circle of the arc of the lateral curve in Type 1. The angle of the plane of the sternoclavicular joint is slightly greater, with the average angle measuring 10.9° .
- **Type 3:** in this group the outer third of the clavicle has the least amount of anterior torsion. Its acromial end is stout and rounded, presenting almost a complete circular articular surface. The arc of

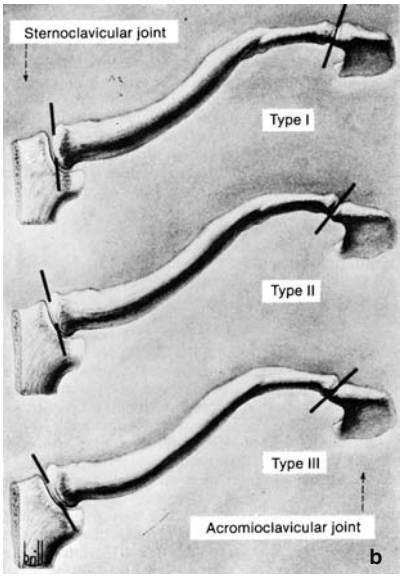
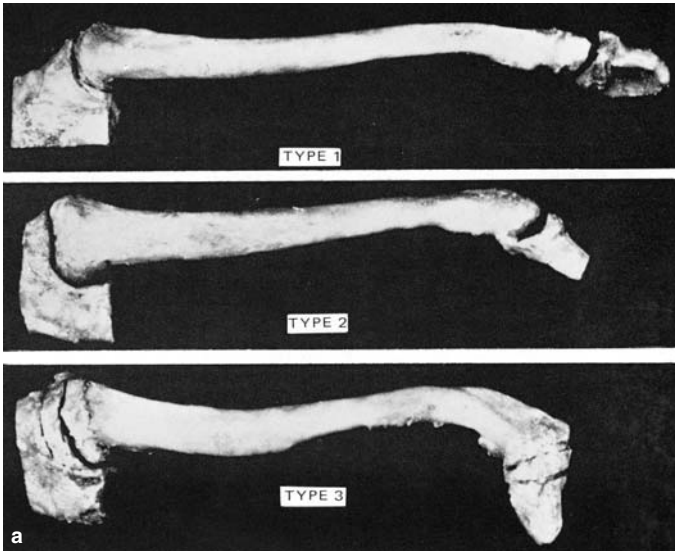


Fig. 33. a Degrees of anterior torsion of the outer third of the clavicle in the three types. b The degree of the anterior torsion of the clavicle determines the inclination of the articular surfaces of the sternal and acromial ends of the clavicles, permitting the joints to be grouped into one of three categories or types

the lateral curve is of a circle that is smaller than the circles of the arcs noted in Types 1 and 2. The plane of the acromioclavicular joint is not far from the horizontal, the average angle being 36.1° ; on the other hand, the plane of the sternoclavicular joint forms an average angle of 13.9° with the vertical.

It is clear that from type 1 to type 3 the angles of the planes of both the acromioclavicular and the sternoclavicular joints increase progressively, whereas the size of the circles of the arcs of the lateral curves diminishes. Of the 66 specimens studied 27 (41%) were type 1, 32 (48%) were type 2, and 7 (11%) were type 3. That these observations have significant clinical application was shown in a clinical study of the relationship between painful acromioclavicular joints due to degenerative changes and the three aforementioned types of clavicles; it was found that the great majority of the patients possessed clavicles classified as type 1. It appears that in type 1 the plane of the joint is such that during motion more shearing forces act on the articular surfaces of the other two types of clavicles. Moreover, the articular surfaces of the joints in type 1 are smaller than those of the other two types, which may be another factor that predisposes the articular cartilage to degenerative alterations.

8.2 Classification of AC-joint dislocation according to Tossy et al. [129]*

The goal of the authors was to offer a simple classification of acute acromioclavicular injuries in order that they be separated into the surgical and the nonsurgical cases. The injury is simply graded according to the extent of anatomic disruption. The classification is based on the experience with 49 cases within 10 years.

The injury is classified into three grades based on the degree of injury to the ligaments. This is ascertained by the amount of displacement of the bony structures.

- **Grade 1:** this includes strains and contusions of the acromioclavicular joint in which there are pain, swelling, and tenderness localized to the joint itself. There is no gross deformity and no more than a suggestion of separation as seen in roentgenogram.

- **Grade 2:** there is localized pain, swelling and tenderness, in addition to reluctance or inability to lift strongly. The outer end of the clavicle may be quite prominent. Roentgenograms taken by the recommended technique (zanca-view) show the acromioclavicular joint to be separated approximately one half; that is, the clavicle is displaced cephalad about one half the normal superior-inferior depth of the joint as compared with the normal side. In addition, the distance between the inferior cortex of the clavicle and the superior tip of the coracoid process is increased (again, compared with the normal side). This represents a partial tear of the conoid and the trapezoid ligaments. We measure both bony relationships, but the more significant for establishing the grade of injury is the coracoclavicular one.
- **Grade 3:** these injuries show a marked deformity of the outer end of the clavicle which presents under the skin posteriorly and upward. There is usually severe disability and pain. Roentgenograms show definite separation of the acromioclavicular joint, greater than one half its normal depth; but more important, there is wide separation of the coracoclavicular relationship. This indicates that the conoid and the trapezoid ligaments have been completely torn.

8.3 Classification of AC-joint injuries according to Allman [1]

Classification and diagnosis of the acromioclavicular sprains are based on the extent of involvement of the injured ligaments.

- **Grade I** sprains of the acromioclavicular joint are the result of a mild force with only a few fibres of the acromioclavicular ligament and capsule involved. There is no laxity of the acromioclavicular joint. Pain is minimum, although point tenderness usually can be elicited over the acromioclavicular joint. The roentgenogram is negative initially, but later it may show subperiosteal calcification about the distal end of the clavicle.
- **Grade II** sprains (Fig. 34a) are usually the result of a moderate force which causes rupture of the capsule and acromioclavicular ligament. This injury frequently is referred to as a subluxation. There is no rupture of the coracoclavicular ligaments. Pain and tenderness are lo-

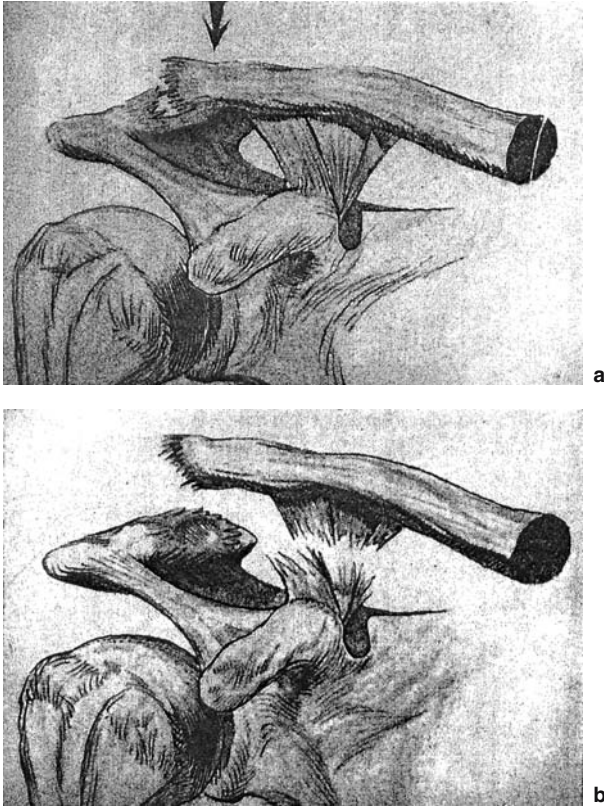


Fig. 34. a Anatomic sketch of grade-II sprain of the acromioclavicular joint (acromioclavicular separation). b Anatomic sketch of grade-III sprain of the acromioclavicular joint (dislocation)

calized over the acromioclavicular joint, and laxity is present in the joint, frequently causing deformity. Roentgenograms reveal the clavicle riding higher than the acromion, but to an extent that is usually less than the width of the clavicle, even while downward stress is applied to the arm. Whenever an acromioclavicular-joint injury is suspected, stress roentgenograms of both shoulders with a 10- to 15-pound weight suspended from each wrist should be included in the work-up.

- **Grade III** sprains of the acromioclavicular joint (Fig. 34b) are usually the result of a severe force with rupture of both the acromioclavicular and coracoclavicular ligaments. This injury frequently is referred to as a dislocation. Pain and tenderness are noted over the acromioclavicular joint and usually over the distal third of the clavicle and coracoid process. Deformity is obvious, and the distal end of the clavicle is easily palpable and ballotable. On the roentgenogram, the distal end of the clavicle is above the superior surface of the acromion, and the distance between the clavicle and coracoid process is increased.

Special mention should be made of posterior displacement of the distal end of the clavicle. The mechanism of injury is usually a direct blow on the distal end of the clavicle; however, the injury may result from a fall on the posterosuperior aspect of the shoulder. This condition frequently is missed because, even on stress roentgenograms, the clavicle may not show an upward displacement.

8.4 Classification of AC-joint injury according to Rockwood et al. [115]

Rockwood modified the classification described by Tossy et al. [129] by adding Type IV, V and VI on the basis of Type 3 injury according to Tossy. Type 1 up to Type 3 are identical to Tossy's classification. The treatment of "complete" acromioclavicular dislocations remains controversial. However, since the treatment for the majority of type IV, V, and VI injuries is operative, it seems reasonable and practical to remove them from all-inclusive type III category and to create an expanded, more accurate classification system. The modified classification is described as follows.

- **Type I:**
 - Sprain of acromioclavicular ligament
 - Acromioclavicular joint intact
 - Coracoclavicular ligaments intact
 - Deltoid and trapezius muscle intact

■ Type II:

Acromioclavicular joint disrupted

Acromioclavicular joint wider: may be a slight vertical separation when compared with the normal shoulder

Sprain of the coracoclavicular ligaments

Coracoclavicular interspace might be slightly increased

Deltoid and trapezius muscles intact

■ Type III:

Acromioclavicular ligaments disrupted

Acromioclavicular joint dislocated and the shoulder complex displaced inferiorly

Coracoclavicular ligaments disrupted

Coracoclavicular interspace 25 to 100% greater than the normal shoulder

Deltoid and trapezius muscles usually detached from the distal end to the clavicle

Type III Variants:

“Pseudodislocation” through intact periosteal sleeve

Physeal injury

Coracoid process fracture

■ Type IV:

Acromioclavicular ligament disrupted

Acromioclavicular joint dislocate and clavicle anatomically displaced posteriorly into or through the trapezius muscle

Coracoclavicular ligaments completely disrupted

Coracoclavicular space may be displaced, but may *appear* same as the normal shoulder

Deltoid and trapezius muscles detached from the distal clavicle

■ Type V:

Acromioclavicular ligaments disrupted

Coracoclavicular ligaments disrupted

Acromioclavicular joint dislocated and gross disparity between the clavicle and the scapula (i.e., 100 to 300% greater than the normal shoulder)

Deltoid and trapezius muscle detached from the distal half of the clavicle

■ Type VI:

Acromioclavicular ligaments disrupted

Coracoclavicular ligaments disrupted in subcoracoid type and intact in subacromial type

Acromioclavicular joint dislocated and clavicle displaced inferior to the acromion or coracoid process

Coracoclavicular interspace reversed in the subcoracoid type (i.e., clavicle inferior to the coracoid), or decrease in the subacromial type (i.e., clavicle inferior to the acromion)

Deltoid and trapezius muscles detached from the distal clavicle

Type I

A mild force to the point of the shoulder produces a minor strain to the fibres of the acromioclavicular ligaments. The ligaments remain intact, and the acromioclavicular joint remains stable (Fig. 35 a).

Type II

A moderate force to the point of the shoulder is severe enough to rupture the ligaments of the acromioclavicular joint (Fig. 35b). The distal end of the clavicle is unstable in the horizontal plane (i.e., anteroposterior), but vertical (i.e., superoinferior) stability is preserved by virtue of

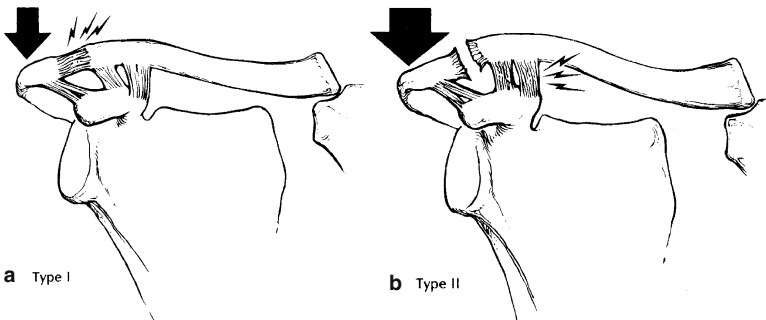


Fig. 35. The classification of ligamentous injuries to the acromioclavicular joint. **a** In type-I injury a mild force (*arrow*) applied to the point of the shoulder does not disrupt either the acromioclavicular or the coracoclavicular ligaments. **b** A moderate to heavy force (*arrow*) applied to the point of the shoulder will disrupt the acromioclavicular ligament, but the coracoclavicular ligaments remain intact

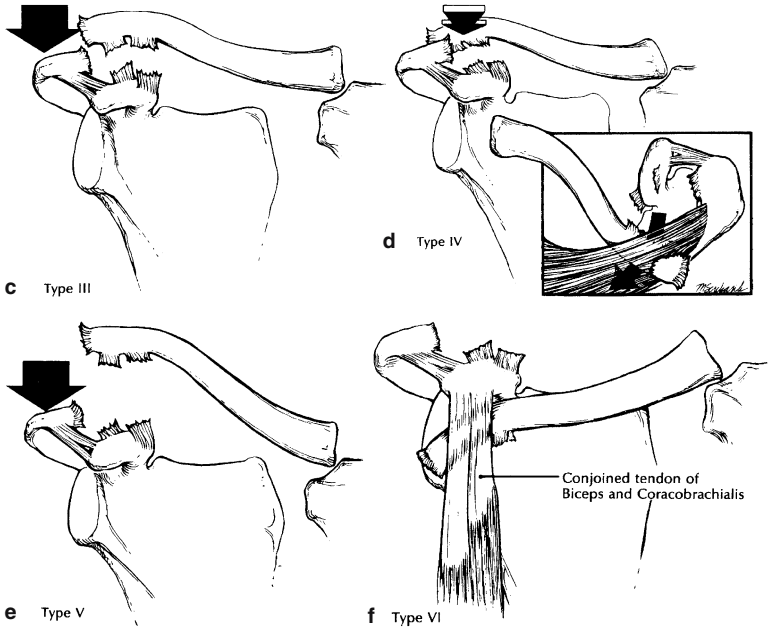


Fig. 35c When a severe force (*arrow*) is applied to the point of the shoulder both the acromioclavicular and the coracoclavicular ligaments are disrupted. **d** In a type-IV injury not only are the ligaments disrupted, but the distal end of the clavicle is also displaced posteriorly into or through the trapezius muscle. **e** A violent force (*arrow*) applied to the point of the shoulder not only ruptures the acromioclavicular and coracoclavicular ligaments, but also disrupts the muscle attachments and creates a major separation between the clavicle and the acromion. **f** This is an inferior dislocation of the distal clavicle in which the clavicle is inferior to the coracoid process and posterior to the biceps and coracobrachialis tendons. The acromioclavicular and coracoclavicular ligaments are also disrupted.

the intact coracoclavicular ligament. The scapula may rotate medially, producing a widening of the acromioclavicular joint. There may be a slight, relative upward displacement of the distal end of the clavicle secondary to a minor stretching of the coracoclavicular ligament.

Type III

When a severe force is applied to the point of the shoulder, “complete” acromioclavicular dislocation occurs. In a “classic” type III injury, the acromioclavicular and coracoclavicular ligaments are disrupted (Fig. 35 c). The distal clavicle appears to be displaced superiorly as the scapula and shoulder complex droop inferomedially. The deltoid and trapezius muscles are detached from the distal clavicle.

Type III Variants

Most often, complete separation of the articular surfaces of the distal clavicle and acromion is accompanied by complete disruption of the acromioclavicular and coracoclavicular ligaments. Children and adolescents occasionally sustain a variant of complete acromioclavicular dislocation. Radiographs reveal displacement of the distal clavicular metaphysis superiorly with a large increase in the coracoclavicular interspace. These injuries are most often Salter-Harris type I or II injuries in which the epiphysis and intact acromioclavicular joint remain in their anatomical locations while the distal clavicular metaphysis is displaced superiorly through a dorsal longitudinal rent in the periosteal sleeve. The importance of recognizing this injury is that the intact coracoclavicular ligaments remain attached to the periosteal sleeve. Nonoperative management most often results in healing of the clavicular fracture and thus reestablishment of the integrity of the coracoclavicular ligaments. Those authors who recommend surgical repair in selected instances emphasize the importance of repairing the dorsal rent in the periosteal sleeve.

A second variation of the type III injury involves complete separation of the acromioclavicular articular surfaces combined with a fracture of the coracoid process. This is an extremely uncommon injury. The mechanism of injury for this “triple lesion” is a simultaneous blow to the acromion and forcible elbow flexion against resistance. In both of these reported cases, the patients underwent operative repair.

Both operative and nonoperative methods of treatment have been described for combined acromioclavicular dislocation and coracoid process fracture with intact coracoclavicular ligaments. Results seem to be similar in both groups. Therefore, most authors recommend nonoperative treatment. Most often, the coracoid process fracture is extraarticu-

lar. However, we have encountered instances in which the coracoid fragment contains a significant position of the glenoid fossa. The conjoined tendon rotates the coracoid process and glenoid inferolaterally and can result in significant displacement. This may require open reduction and internal fixation.

Type IV

Posterior dislocation of the distal end of the clavicle, or type IV acromioclavicular dislocation, is relatively rare. The clavicle is posteriorly displaced into or through the trapezius muscle as the force applied to the acromion drives the scapula anteriorly and inferiorly (Fig. 35d). Posterior clavicular displacement may be so severe that the skin on the posterior aspect of the shoulder becomes tented. The literature concerning posterior acromioclavicular dislocations consists mostly of small series and case reports.

Bipolar clavicular dislocation (i.e., combines acromioclavicular and sternoclavicular dislocation) is a rare injury that has been sparsely reported in the literature. When this injury does occur it is most often a posterior or type IV acromioclavicular dislocation associated with an anterior sternoclavicular dislocation. This underlies the importance of a thorough evaluation of any patient with acromioclavicular joint injury with particular reference paid to the sternoclavicular joint.

Type V

Type V acromioclavicular dislocation is a markedly more severe version of the type III injury. The distal clavicle has been stripped of all its soft-tissue attachments (i.e., acromioclavicular ligaments, coracoclavicular ligament, and the deltotrapius muscle attachments) and lies subcutaneously near the base of the neck (Fig. 35e). When combined with superior displacement of the clavicle owing to unopposed pull of the sternocleidomastoid muscle, the severe downward droop of the extremity produces a grotesque disfiguration of the shoulder.

Type VI

Inferior dislocation of the distal clavicle or type VI acromioclavicular dislocation, is an exceedingly rare injury. The injury is often the result of severe trauma and is frequently accompanied by multiple injuries.

The mechanism of dislocation is thought to be severe hyperabduction and external rotation of the arm, combined with retraction of the scapula. The distal clavicle occupies either a subacromial or a subcoracoid location (Fig. 35f). In all reported cases of subcoracoid dislocations, the clavicle has become lodged behind an intact conjoined tendon. The acromioclavicular ligaments are disrupted in either a subacromial or subcoracoid dislocation. The coracoclavicular ligament, however, is intact in a subacromial dislocation and completely disrupted in a subcoracoid dislocation. Likewise, the integrity of the deltoid and trapezius muscle attachments depends on the degree of clavicular displacement.

9.1 Classification of SC-joint injury according to Allman [1]

This is an injury to the capsule and to the sternoclavicular ligament or costoclavicular ligament, or both.

- A **Grade I** sprain of the sternoclavicular joint results from a mild medially directed force applied to the lateral aspect of the involved shoulder or from the shoulder being suddenly forced forward. There is no laxity of the joint, and pain is minimum.
- A **Grade II** sprain of the sternoclavicular joint is characterized by rupture of the sternoclavicular ligaments without rupture of the costoclavicular ligament. Pain and swelling usually are localized over the joint, and mild deformity may be present.
- **Grade III** sprains of this joint are complete ruptures of the sternoclavicular and costoclavicular ligaments (Fig. 36). The displacement may be anterior or retrosternal. Usually pain and swelling are more pronounced than in Grade II sprains and the deformity is more prominent.

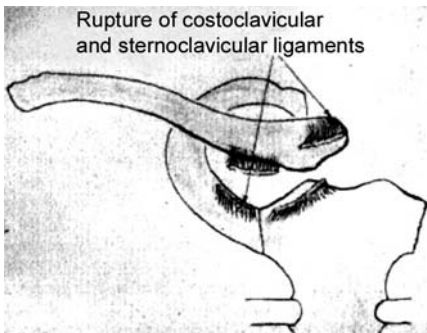


Fig. 36. Anatomic sketch of grade-III sprain of sternoclavicular joint

Retrosternal dislocations of the clavicle must be given special mention because of their serious complications of sudden death, respiratory distress, and damage of the great vessels that may occur.

10.1 Classification of fractures of the clavicle according to Allman [1]

Fractures of the clavicle may be divided into three groups:

- **Group I:** fractures of the middle third, the most frequent site
- **Group II:** fractures distal to the coracoclavicular ligament, where nonunion is frequent
- **Group III:** fractures of the proximal end of the clavicle, where displacement and nonunion are rare

Group I: *fractures of the middle third of the clavicle*

The mechanism of injury generally is a fall onto the outstretched hand or a fall on the point of the shoulder. When there is displacement, the proximal fragment of the clavicle usually is elevated and the shoulder with the distal fragment is displaced downward and inward. Local pain, swelling, and crepitating are present over the fracture site. Roentgenograms usually confirm the diagnosis; however, in the absence of displacement, the fracture may be difficult to visualize.

If displacement is present the fractures should be manipulated and reduced to a position that is as near anatomical as possible.

Group II: *fractures of the clavicle distal to the coracoclavicular ligament*

Fractures of the clavicle distal to the coracoclavicular ligament have gained a reputation for failing to unite. This situation has arisen because most physicians treat this condition by methods similar to those for other fractures of the clavicle, namely with a figure-of-eight bandage or a Billington yoke.

Neer [95] has classified fractures of the distal end of the clavicle into two types.

Group III: *fractures of the proximal end of the clavicle*

Fractures of the inner third of the clavicle are infrequent, and if the costoclavicular ligament remains intact and attached to the outer fragment, there is little or no displacement. The mechanism of injury usually is direct violence applied at an angle from the lateral side.

10.2 Classification of fractures of the clavicle according to Neer [95,101,106]*

Neer classified the clavicular fractures in three groups:

1. Midclavicular fracture: middle third (80%) (Fig. 37 f)
2. Fracture of the distal clavicle: or interligamentous fracture (15%)
3. Fracture of the inner clavicle: inner third (5%)

Distal fractures comprise 10% of clavicular injuries and can be classified into two types, depending upon the status of the ligaments (Fig. 37 a). **Type I** resents no problem and requires little or no treatment. It occurs more frequently in ratio of 3:1. The full extent of the displacement in **Type II** lesions is not shown by routine roentgenographic studies, especially when the patient is examined supine. Erect oblique views are of great value. There are four displacing forces all acting to retard union.

1. *Trapezius muscle.* This attaches upon the entire outer third of the clavicle and draw the large medial fragment *posteriorly within its substance*. Interposition of this muscle is common. The skin may be tent poled posteriorly over the end of the shaft (Fig. 37 b).
2. *Weight of the arm.* As the scapula and arm descend, the outer fragment, retaining its attachments to the trapezoid ligament and acromion, is pulled downward and forward (Fig. 37 c).
3. *Trunk muscles attaching the humerus and scapula.* These displace the outer fragment medially toward the apex of the thorax.
4. *Rotary displacement.* The scapular ligaments may rotate the outer fragment as much as 40° with movement of the arm. No similar rotation of the medial fragment occurs because it is detached.

There is extensive local tissue injury as evidenced by accompanying fractures of the upper six ribs in 25% of this series. Occasionally, the coracoid process is avulsed as well. Rib fractures result from the displacement of the humerus and scapula against the chest wall.

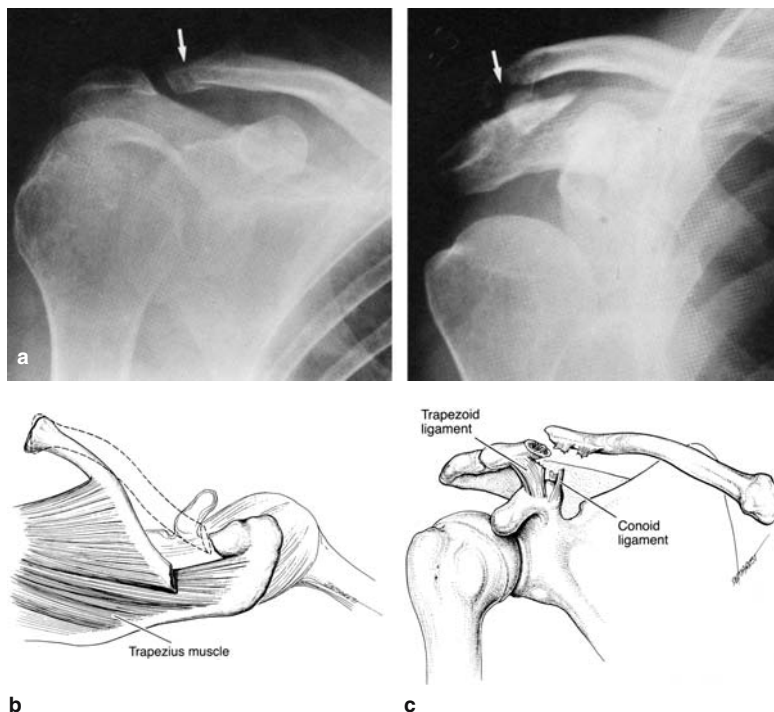


Fig. 37 a-c. a Roentgenograms depicting the two categories of fractures in the flattened portion of the clavicle. *Left:* Type I. The coracoclavicular ligaments are intact. *Right:* Type II. The medial fragment is detached from the ligaments. In the second lesion there is greater posterior displacement of the shaft and more soft tissue injury than is suggested by this view. **b** In type-II lesions the distal fragment drops forward and downward, causing the proximal fragment to be surrounded by the trapezius muscle. This posterior displacement of the proximal fragment can be seen well in the lateral view of the trauma series. **c** In type-II lesions the coracoclavicular ligaments and the acromioclavicular joint capsule remain attached to the distal fragment but are detached from the proximal fragment

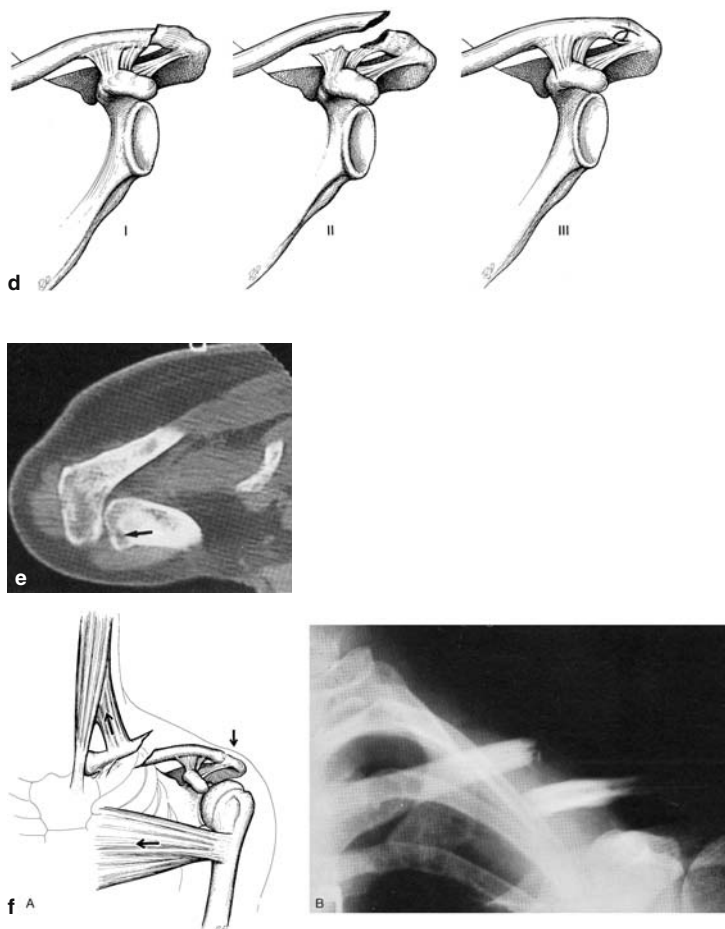


Fig. 37 d-f. **d** Classification of distal clavicle fractures. Type I: minimal displacement with intact ligaments; type II: displaced with detachment of the ligaments from the medial fragment; type III: articular surface fracture. **e** Type-III lesions can be easily overlooked in the initial films. Computerized tomography can show an occult fracture of the articular surface. A tense hemarthrosis of the acromioclavicular joint occasionally occurs. **f** Midclavicular fractures (**A**). Forces acting on the clavicle. The distal fragment is pulled down by the weight of the arm and medially by the pectoralis major and latissimus dorsi. The proximal fragment is pulled upward by the sternomastoid. Typical X-ray appearance of a middle third fracture (**B**)

Because of the differences in clinical behaviour Neer [95, 101, 106] subdivided the fractures of the distal clavicle in 1968 into three different types (Fig. 37 d):

- **Type I:** minimal displacement with intact ligaments
- **Type II:** displaced with detachment of the ligaments from the proximal fragment
- **Type III:** fractures of the articular surface

Type I: distal clavicle fractures

Type I fractures with minimal displacement and intact ligaments, require only a sling, and activities are extended as pain subsides.

Type II: distal clavicle fractures

Type II, displaced, fractures are unstable, because the coracoclavicular ligaments are detached from the proximal fragment. The proximal fragment is retracted upward and backward within the substance of the trapezius muscle, while the distal fragment drops downward and forward and is rotated by any movements of the scapula.

Type III: distal clavicle fractures

Type III fractures, those of the articular surface of the clavicle, frequently lead to symptomatic arthritic changes, and apparently because of the abundant blood supply, they may be followed by extensive resorption of the end of this bone. Resorption of the articular surface is also seen in “weightlifter’s clavicle” and in other athletic patients, who have repeated microtrauma, which Neer believe can produce small fractures of the articular surface of this type (Fig. 37 e).

10.3 Classification of fractures of the clavicle according to Jäger and Breitner [62]

In consideration of the treatment, Jäger and Breitner expanded Neer’s classification of lateral clavicular fractures (Fig. 38).

Type I represents the lateral fracture without ligamentous injury with or without involvement of the AC-joint (stable).

The interligamenteous fractures were distinguished into:

- Type IIa: with avulsion of the pars conoidea from the proximal fragment (unstable)
- Type IIb: with isolated avulsion of the pars trapezoidea from the lateral fragment (moderate unstable)
- Type III: fractures medially to the intact coracoclavicular ligaments, but in the lateral third of the clavicle
- Type IV: pseudodislocation: pediatric metaphyseal avulsion injury out of the periosteal sleeve.

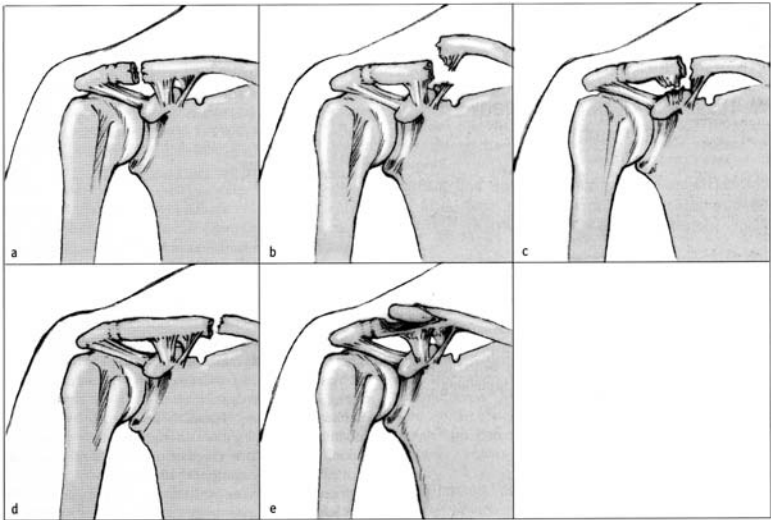


Fig. 38. Classification of distal fracture of the clavicle. (From [62]). **a** Type I: lateral fracture with intact coracoclavicular ligaments, with or without involvement of the acromioclavicular joint (stable). **b** Type IIa: fracture with avulsion of the pars conoidea, unstable. **c** Type IIb: fracture with avulsion of the pars trapezoidea, intact pars conoidea (moderate unstable). **d** Type III: fracture medially to the intact coracoclavicular ligaments. **e** Type IV: avulsion injury of the lateral clavicle out of the periosteal sleeve (pseudodislocation)

10.4 Classification of clavicular fractures according to Craig [24]

On the base of Allman's classification Craig introduced in 1990 a more detailed classification of clavicular fractures that was based on the variable fracture patterns seen within the three broad groups of Allman's clavicle fracture classification:

- **Group I:** fracture of the middle third
- **Group II:** fracture of the distal third
 - *Type I:* minimal displacement (interligamentous)
 - *Type II:* displaced secondary to a fracture medial to the coracoclavicular ligaments
 - A. Conoid and trapezoid attached
 - B. Conoid torn, trapezoid attached
 - *Type III:* fractures of the articular surface
 - *Type IV:* ligaments intact to the periosteum (children), with displacement of the proximal fragment
 - *Type V:* comminuted, with ligaments attached neither proximally nor distally, but to an inferior, comminuted fragment.
- **Group III:** fracture of the proximal third
 - *Type I:* minimal displacement
 - *Type II:* displaced (ligaments ruptured)
 - *Type III:* intraarticular
 - *Type IV:* epiphyseal separation (children and young adults)
 - *Type V:* comminuted

Group I fractures, or fractures of the middle third, are the most common fractures seen in adults and children. They occur at the point at which the clavicle changes to a flattened cross section from a prismatic cross section. The force of the traumatic impact follows the curve of the clavicle and disperses on reaching the lateral curve. In addition, the proximal and distal segments of the clavicle are mechanically secured by ligamentous structures and muscular attachments, whereas the central segment is relatively free. This fracture accounts for 80% of clavicular fractures.

Group II fractures account for 12 to 15%, of all clavicular fractures and are subclassified according to the location of the coracoclavicular ligaments relative to the fracture fragments. Neer [98] first pointed out the importance of this fracture while subdividing it into three types. *Type I* fractures are the most common by a ratio of 4:1. In this fracture, the ligaments remain intact or hold the fragments together and prevent rotation, tilting, or significant displacement. This fracture is an interligamentous fracture that occurs between the conoid and the trapezoid or between the coracoclavicular and acromioclavicular ligaments (Fig. 39a). In *type II* distal clavicular fractures, the coracoclavicular ligaments are detached from the medial segment. Both the conoid and trapezoid may be on the distal fragment (*IIA*) (Fig. 39b), or the conoid ligament may be ruptured while the trapezoid ligament remains attached to the distal segment (*IIB*) (Fig. 39c). There is really no functional difference between these two fractures. The high rate of nonunion in these fractures may be secondary to excessive motion at the fracture site. These fractures are equivalent to a serious acromioclavicular separation in which the normal constraints to anteromedial rotation of the scapula relative to the clavicle are lost. Four forces that may impair healing and may be contributing factors to the reported high incidence of nonunion act on this fracture: (1) when the patient is erect, the outer fragment, which retains the attachment of the trapezoid ligament to the scapula through the intact acromioclavicular ligaments is pulled downward and forward by the weight of the arm; (2) the pectoralis major, pectoralis minor, and latissimus dorsi draw the distal segment downward and medially, thereby causing overriding; (3) the scapula may rotate the distal segment as the arm is moved; and (4) the trapezius muscle attaches upon the entire outer two thirds of the clavicle whereas the sternocleidomastoid muscle attaches to the medial third, and these muscles act to draw the clavicular segment superiorly and posteriorly, often into the substance of the trapezius muscle.

Type III distal clavicular fractures involve the articular surface of the acromioclavicular joint alone (Fig. 39d). Although type II fractures may have intraarticular extension, type III fractures are characterized by a break in the articular surface without a ligamentous injury. A type III injury may be subtle, may be confused with a first-degree acromioclavicular separation, and may require special views to visualize. It may, in

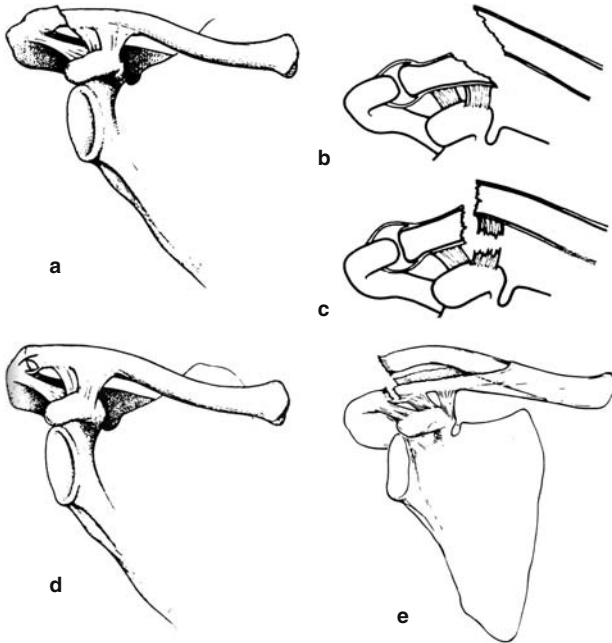


Fig. 39. Classification of fractures of the clavicle. **a** Type-I fracture of the distal end of the clavicle (group II). The intact ligaments hold the fragments in place. **b** Type II distal clavicular fracture. In type IIA both the conoid and trapezoid ligaments are on the distal segment, whereas the proximal segment, without ligamentous attachments, is displaced. **c** Type-II B fracture of the distal part of the clavicle. The conoid ligament is ruptured, whereas the trapezoid ligament remains attached to the distal segment. The proximal fragment is displaced. **d** Type-III distal clavicular fracture involving the articular surface of the acromioclavicular joint alone. No ligamentous disruption or displacement is present. These fractures are manifested as late degenerative changes of the joint. **e** A type-IV fracture occurring in children that has been called a "pseudodislocation" of the acromioclavicular joint. The coracoclavicular ligaments remain attached to the bone or the periosteum, whereas the proximal fragment ruptures through the thin superior periosteum and may be displaced upward by muscle forces. (From [24])

fact, be manifested as late degenerative joint arthrosis of the acromioclavicular joint. In addition, it has been suggested that “weightlifter’s clavicle” or resorption of the distal end of the clavicle, may occur from increased vascularity secondary to the microtrauma or microfractures that lead to such resorption.

It appears logical to add a fourth and fifth type of distal clavicular fracture because in a certain series of fractures, bone displacement occurs as a result of deforming muscle forces but the coracoclavicular ligaments remain attached to bone or periosteum.

Type IV fractures occur in children and may be confused with complete acromioclavicular separation (Fig. 39e). Called *pseudodislocation* of the acromioclavicular joint, they typically occur in children younger than 16 years. The distal end of the clavicle is fractured, and the acromioclavicular joint remains intact. In children and young adults, the attachment between bone and the periosteum is relatively loose. The proximal fragment ruptures through the thin periosteum and may be displaced upward by muscular forces. The coracoclavicular ligaments remain attached to the periosteum or may be avulsed with a small piece of bone. Clinically and radiologically, it may be impossible to distinguish between grade III acromioclavicular separations, type II fractures of the distal end of the clavicle, and type IV fractures involving rupture of the periosteum.

10.5 Classification of fractures of the clavicle in adult according to Robinson [114]*

A new classification was developed based on radiological review of the anatomical site and the extent of displacement, comminution and articular extension out of 1000 patients. There were satisfactory levels of inter- and intraobserver variation for reliability and reproducibility. Fractures of the medial fifth (type 1), undisplaced diaphyseal fractures (type 2A) and fractures of the outer fifth (type 3A) usually had a benign prognosis. The incidence of complications of union was higher in displaced diaphyseal (type 2B) and displaced outer-fifth (type 3B) fractures. In addition to displacement, the extent of comminution in type-2B fractures was a risk factor for delayed and nonunion.

Three different areas of fracture were identified: the diaphysis and the medial and lateral ends (Fig. 40). **Type I** was the fifth of the bone lying medial to a vertical line drawn upwards from the centre of the first rib. **Type 3** was the fifth of the bone lateral to a vertical line drawn upwards from the centre of the base of the coracoid process, a point normally marked by the conoid tuberosity. **Type 2** was the intermediate three-fifths of the diaphysis.

Fractures were also divided into **subgroups A and B** depending on displacement (greater or less than 100% translation) of the major fragments. This is often difficult because of the sigmoid shape of the clavicle, particularly at the ends of the bone, but weight-bearing, oblique, 30° caudal-tilted or modified axial views were used in cases in which uncertainty existed.

Type-IA and type-IB fractures were further subdivided into extra- or intraarticular; *type-2A* fractures were subdivided according to the presence of angulation, but in all these injuries there was residual bony contact. In the *type-2B* subgroup there was no residual contact between the major fragments and variable degrees of shortening which was usually apparent both clinically and radiologically. Two further subgroups of type-2B were simple or wedge comminuted fractures (type 2B1) and isolated segmental or segmentally comminuted fractures (type 2B2). *Type-3A* and *type-3B* fractures were also subdivided according to articular involvement. Displacement in type-3B injuries showed a characteristic pattern of elevation and posterior displacement of the shaft fragment, with either a simple oblique configuration or with avulsion of an inferior bone fragment.

Type-1 fractures were uncommon, at 2.8% of the fracture population; most were undisplaced and extraarticular (type IA 1). Type-2 injuries were the most common (69.2%) and most were displaced (type 2B); the most common was type 2B1. Of the type-2B1 fractures, 28.9% had wedge comminution and the remainder was simple. Type-2B2 fractures had an incidence of 25.5%. Of the type 2B2 injuries 21.1% were the isolated segmental type and the remainder was comminuted segmental. Type-3 fractures. 28% of all were predominantly undisplaced (type 3A).

Type-1 and type-2 fractures were seen in a younger population and with a greater M:F ratio than type-3 fractures. Type-2A2 fractures occurred in a younger population than the other fractures; all but two




Fig. 40. Type-1, type-2, and type-3 clavicular fractures

were in patients aged 13 to 25 years. Type-2 fractures were mainly caused by sport or RTAs whereas simple falls were the commonest cause of type-I and type-3 fractures.

10.6 Classification of nonunion of clavicular fractures according to Neer [98]*

- **Type 1** was characterized by a false joint, with hyaline-like cartilage capping the dense bone ends, and possibly joint fluid.
- **Type 2** lesions consisted of resorption of the bone adjacent to the fractures, resulting in tapering bone ends, obliteration of the medullary canal, and a gap which was filled with fibrous tissue.

10.7 Classification of epiphyseal fractures of the proximal end of the clavicle according to Rockwood and Wirth [115a]*

The epiphyseal fractures of the proximal end of the clavicle have to be differentiated from Grad III sterno clavicular joint dislocations (Fig. 41 a,b).

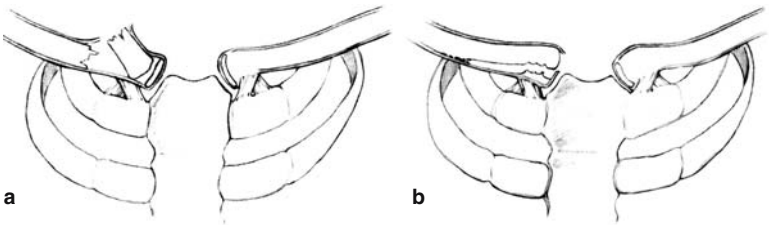


Fig. 41. Types of epiphyseal fractures of the proximal clavicle. a Type I; b Type II

11.1 Classification of proximal humeral fractures according to Neer [93]

The classification adopted is based, neither on the level of the fracture nor on the mechanism of injury, but on the presence or absence of displacement of one or more of the four major segments. Since all minimally displaced fractures pose analogous problems in treatment and prognosis, it seems logical that they be grouped together, regardless of the number of fracture lines. Displaced fractures require more accurate identification in order to depict both the effect of muscle attachments on free fragments as well as the circulatory status and continuity of the articular surface. The classification illustrated was formed to identify the types of displacement that were actually encountered (Fig. 42).

Group I, minimum displacement

This group includes all fractures, regardless of the level or number of fracture lines, in which no segment is displaced more than 1.0 cm or is angulated more than 45°. This group constitutes over 85% of proximal humeral fractures. These lesions present similar problems in management. The fragments are usually held together by soft tissue or are impacted, permitting early functional exercises; however, a brief period of immobilization may be required before the head and shaft rotate as one.

Group II, articular-segment displacement

Pure displacement at the anatomical neck without separation of one tuberosity or both is quite rare. This lesion can escape notice unless a good anteroposterior roentgenogram of the upper end of the humerus is obtained and may lead to disability because of malunion or avascular necrosis.

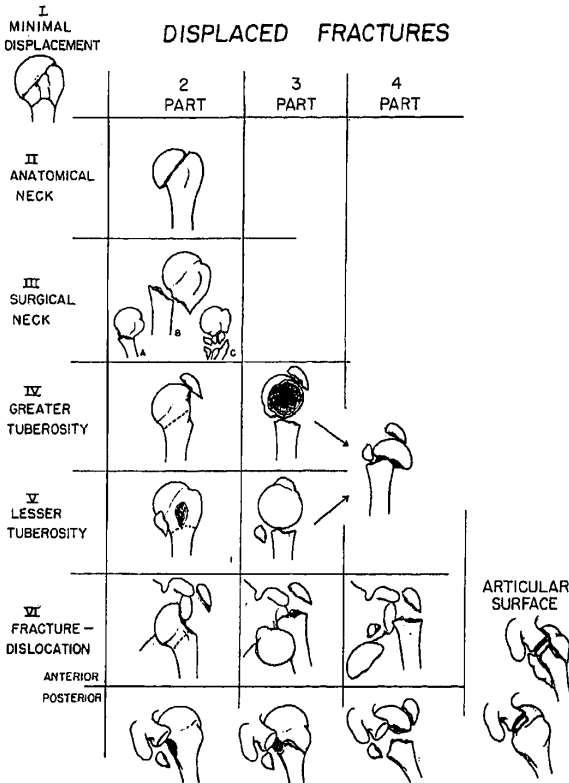


Fig. 42. The anatomic classification. Group I includes all proximal humeral fractures, regardless of the number of lines of cleavage, in which no segment is displaced more than 1 cm or angulated more than 45° . Group II, the anatomic-neck fracture, is a displacement of the head segment, with or without hairline tuberosity components. Group III, the surgical-neck fracture, is a displacement of the shaft segment with the rotator cuff intact. Group IV, the greater tuberosity displacement, occurs as a two-part and, with an unimpacted surgical-neck fracture, as a three-part lesion. Group V, the lesser tuberosity, occurs as a two-part and, with an unimpacted surgical-neck fracture, as a three-part lesion. Groups IV and V blend as the four-part fracture in which both tuberosities are displaced. Group VI, the fracture/dislocation, implies damage outside the joint space, anteriorly and posteriorly, and segment distribution is important in estimating the circulation of the head. The articular surface, in which portions of the head are dislocated, are the impression fracture and the head-splitting fracture.

Group III, shaft displacement

This fracture occurs just distal to the tuberosities at the level of the surgical neck and is displaced more than 1.0 cm or is angulated more than 45°. Although fissure fractures may be present proximally, the rotator-cuff attachments are intact and hold the head in neutral rotation. The head is only slightly abducted unless tilted by an overriding shaft. Epiphyseal fractures are of this category. Three types are seen in adult patients.

The *angulated surgical-neck fracture* is impacted. Residual angulation of more than 45° causes permanent limitation of abduction and elevation. The periosteal sleeve is usually intact posteriorly and affords considerable stability when closed reduction is accomplished by traction and elevation of the arm forward beyond the pivotal position.

The *separated surgical-neck fracture* is one in which the shaft is displaced medially and anteriorly, pulled by the pectoralis major. This fracture is often unstable after closed reduction, and immobilization in a position to relax the pectoralis is helpful. The displacement is made worse by placing the arm in abduction or in a tight sling. Instability and interposition of soft tissue may lead to nonunion. Associated neurovascular damage is not uncommon.

The *comminuted surgical-neck fracture*, in which fragmentation extends distally for several centimetres, often undergoes twist displacement when the arm is internally rotated across the chest, because the tuberosities and head are held in neutral rotation by the intact rotator cuff. Intermediate fragments may be displaced by the pectoralis. This fracture can be adequately aligned by overhead ulnar-pin traction applied in neutral rotation to relax the pectoralis.

Group IV, greater-tuberosity displacement

The greater tuberosity or one of its facets for tendon attachment is retracted more than 1.0 cm from the lesser tuberosity. The separation is pathognomonic of a longitudinal tear in the rotator cuff. The tear usually occurs at the rotator interval, but, when only the posterior part of the greater tuberosity is retracted, the tear occurs posterior to this interval. In the two-part pattern, the articular segment remains in a normal relationship with the shaft, although a minimally displaced fracture of the surgical neck may be present. In the three-part pattern, in addition to

the retraction of the tuberosity, displacement at the surgical neck is also present which allows the articular segment to be internally rotated by the subscapularis. This exaggerates the rotator-cuff defect and causes the articular segment to face posteriorly. This is a much more serious displacement. The attached muscles act to prevent closed reduction. Nevertheless, a good source of blood supply to the head remains because soft parts are attached to the articular segment anteriorly. If this source of blood supply is preserved during an open reduction, the prognosis for survival of the humeral head would appear to be much better than that of the four-part fracture in which the head is detached.

Group V, lesser-tuberosity displacement

The two-part lesion occurs as an isolate avulsion or in association with an undisplaced fracture of the surgical neck. Displacement of the lesser tuberosity spreads the anterior fibres at the rotator interval and produces a bone prominence. Neither the defect appears to be of clinical importance. In the three-part displacement, however, the displacement at the surgical neck allows the articular segment to be externally rotated and abducted by the supraspinatus and external rotators. This exaggerates the rotator-cuff defect and interferes with closed reduction. The articular surface is made to face anteriorly. At open reduction, articular cartilage is found presenting at the gaping tear in the rotator cuff, a situation which suggests that the head is dislocated, a false fractures-dislocation. However, the head segment retains abundant soft-part attachments posteriorly and adequate blood supply. Open reduction can be readily accomplished by derotating the head and approximating the tuberosities and cuff. In the four-part fracture, both tuberosities are retracted and, as in all four-part fracture, both tuberosities are retracted and, as in all four-part lesions, the blood supply to the humeral head has been severed. The articular segment is usually displaced laterally between the retracted tuberosities. When the head is displaced laterally and out of contact with the glenoid, the term *lateral fracture-dislocation* is descriptive. However, the pathomechanics seem clearer when this lesion is classified as a severely displaced fracture rather than a fracture-dislocation.

Group VI, fracture-dislocation

This fracture occurs with a true dislocation which implies ligamentous damage and injury outside the joint, in turn implying a greater threat of pericapsular bone formation. The displacement of the humeral head may be anteroinferior, posterior, or superior; but no instance of superior displacement, associated with a fracture of the proximal end of the humerus, was encountered in this study. In two-part and three-part fracture-dislocations, the blood supply to the humeral head is usually adequate because one of the tuberosities, with soft tissue attachments, remains in continuity with the articular segment. The lesser tuberosity always remains attached to the humeral head in anterior three-part fracture-dislocation while the greater tuberosity remains to provide circulation to the head in posterior three-part fracture-dislocations. In four-part fracture-dislocations the head is detached. Neurovascular symptoms occur more commonly with anterior four-part displacements.

Displaced fractures of the articular surface are classified with fracture-dislocations because, while part of the articular cartilage has been crushed by impact against the glenoid and stays within the joint space, other fragments of cartilage are extruded from it. The impression fracture is commonly encountered with a posterior dislocation but rarely occurs to a significant extent with an anterior dislocation. When the impression defect is small and the lesion is recognized early, closed reduction is effective. When the impression involves more than 20% of the articular surface, redislocation tends to occur unless the main articular fragment is stabilized, as by transplantation of the subscapularis tendon into the defect in the head. When the articular defect involves more than 50% of the cartilage-covered surface, the joint is unstable and dislocation readily recurs despite transplantation of the subscapularis. A prosthesis may be used at time to render this lesion stable. The head-splitting fracture results from a central impact which may extrude fragments of cartilage both anteriorly and posterior. The articular surface is fragmented into many disconnected pieces.

This original 4-segment system was simplified in 1975 [94] as shown in Fig. 43. The Roman numerals used to designate the six subgroups were deleted, and the definitions of the categories were re-stated. It was emphasized that the 4-segment classification is not meant to be a numerical classification that is oversimplified or pattern for easy roentgen

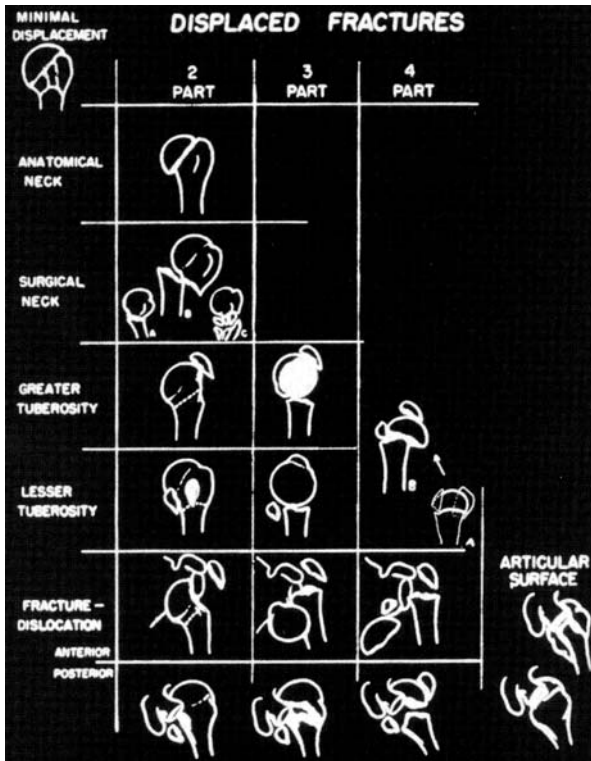


Fig. 43. The four-segment classification system and terminology for proximal humeral fractures and fractures dislocations. In a one-part fracture (minimal displacement) no segment is displaced more than 1.0 cm or angulated more than 45° regardless of the number of fracture lines. The terminology for displaced lesions relates a pattern of displacement (two-part, three-part, or four-part) and the key segment displaced. In the two-part pattern, the segment named is the one displaced, including the two-part articular segment (anatomic neck) fracture, the two-part shaft (surgical neck) fracture of three types (A, impacted, B, unimpacted, and C, comminuted), the two-part greater tuberosity fracture, the two-part lesser tuberosity fracture, and the two-part fracture/dislocations. In all three-part displacements, one tuberosity is displaced and there is a displaced unimpacted surgical neck component that allows the head to be rotated by the tuberosity, which remains attached to it, including the three-part greater tuberosity fracture, the three-part lesser tuberosity fracture, and the three-part fracture/dislocations. Of the four-part fractures, the impacted cal-

classification, but rather is a “concept” or mental picture of the actual patomechanics and pathoanatomy of displaced proximal humeral fractures and the terminology to identify each category. The need for understanding the pathology and knowing the criteria for each category, as described in Fig. 43, remained.

Thirty years later Neer updated the criteria for the categories and outlined the requirements for the reliable use [94]. The pathoanatomy of displaced proximal humeral fractures will not change; however, treatment will change as improvements are made.

Terminology

The terminology for the 4-segment classification is illustrated in Fig. 43. If no major segment (groups of fragments) is displaced more than 1 cm or 45°, the fracture is 1-part, or minimal displacement, regardless of the number of fracture lines. The terminology for displaced fractures and fracture dislocations relates a pattern of displacement (i.e., 2-part, 3-part, or 4-part) and is the key segment displaced. In 2-part fractures, the segment named is the one displaced. In all 3-part fractures and fracture-dislocations, there is an unimpacted, displaced surgical neck component to allow the rotary displacement of the head caused by the muscle forces on the tuberosity that remains attached to the articular

gus four-part fracture (A) is less displaced and considered to be, in the continuum of lateral displacement, the precursor to B, the four-part fracture (lateral fracture/dislocation) in which the head is dislocated laterally and detached from both tuberosities and from its blood supply. In fracture/dislocation, the fracture occurs with a true dislocation, which implies damage outside the joint so that neurovascular injuries and periscapular bone occurs more often. They are named according to the pattern of the fracture (two-part, three-part, or four-part) and the location of the head (anterior, posterior, inferior, etc.). In four-part fracture/dislocations, the head is detached from its blood supply. Displaced fractures of the articular surface, the impression and head-splitting fractures, are classified with fracture/dislocations because, while part of the articular cartilage is crushed or fragmented against the glenoid, other fragments are extruded from it. Large-impression fractures usually occur with posterior dislocations, as drawn in the diagram, and head-splitting fractures usually extrude fragments both anteriorly and posteriorly.

segment. The displaced tuberosity segment is named to identify the type of 3-part displacement. Of the 4-part fractures, the valgus-impacted 4-part fracture is a less displaced, borderline precursor to the true 4-part fracture (lateral fracture-dislocation). In all fracture-dislocations, the articular segment is displaced out of contact with the glenoid and location of the head (anterior, posterior, lateral, and inferior, and theoretically, in violent trauma, superior, inferior, or intrathoracic) is named to identify the type of fracture-dislocation. The large articular surface defects, the “head-splitting” and “impression” fractures, are classified as special fracture-dislocations, because parts of the articular surface are displaced outside of the joint.

One part fractures (minimal displacement)

Eight out of ten proximal humeral fractures are of this type, and it is important to be able to identify them. This category includes all fractures of the proximal humerus, regardless of the level or number of fracture line, in which no segment is displaced more than 1 cm or angulated more than 45° . The fragments are usually held together by the soft tissue or are impacted, permitting early gentle exercises; however, before exercises are started, clinical examination for false motion between the head and the shaft is important to avoid nonunion. Transitory subluxation resulting from temporary muscle atony can cause considerable concern.

The authors of the AO classification thought it was a deficiency of the 4-segment system that it had not established, experimentally or clinically, that its displacement criterion is the allowable deformity for adequate function and that it guarantees vascular continuity between fragments. The 4-segment system was not intended to imply that this amount of displacement gave assurance of a good result. On the contrary, in many lectures and articles, it has been emphasized that unless minimally displaced fractures are carefully treated with well-directed exercises for a surprisingly long period of time, the result may be disappointing. Even then, late avascular necrosis and post-traumatic arthritis occasionally occur.

The drawing of minimal displacement in the original 4-segment diagram, as shown in Fig. 43, and the drawing to show the technique for exploring acute fractures depict the intertubercular (bicapital groove)

fragment, which has received some recent interest. This intermediate fragment has been recognized at surgery for many years. Because special imaging has shown it is common and late avascular necrosis of the humeral head following minimal displacements is rare, it seems unlikely that this fragment per se is the important cause of avascular necrosis of the humeral head, even though the ascending branch of the anterior circumflex humeral artery enters the bone in this area.

Two-part articular segment displacement (anatomic neck)

Isolated displacement of the articular segment at the anatomic neck level, without displacement of the tuberosities, is rare. The undisplaced tuberosities prevent the articular surface from being displaced in valgus (laterally). The displacement of the head can easily be overlooked without supplemental roentgen studies. No surgeon has had a great deal of experience with this fracture, but there appears to be a high incidence of avascular necrosis of the head. Because the tuberosities are in good position, it is logical to treat a new injury either by open reduction and internal fixation or by accepting the position, hoping for a comfortable malunion, and if this fails, using a prosthesis. The tuberosities being undisplaced facilitate late prosthetic replacement of the head.

Two-part shaft displacement (surgical neck)

Two-part shaft displacement fractures occur in patients of all ages (from before closure of the epiphyses to the very old). The pectoralis major is the deforming muscle. There may be hairline, undisplaced fissure fractures proximally in the tuberosities, but they and the articular segment are held in neutral rotation by the rotator cuff muscles. There are three clinical types, each with special treatment considerations.

Impacted. For the impacted type, there is more than 45° angulation and the apex is usually anterior. The periosteum is intact on the side opposite the apex. Supplemental roentgen views rotating around the humerus can be helpful in determining the amount of angulation. Closed disimpaction with fluoroscopic control is considered for active patients.

Unimpacted. For the unimpacted type, the pectoralis major acts to displace the shaft anteromedially and the head tends to remain in neutral

rotation. The sharp calcar may damage the axillary artery or brachial plexus. Closed reduction may follow one of three courses: (1) adequate and stable reduction, (2) adequate but unstable reduction requiring a percutaneous pin, or (3) unsuccessful result, requiring an open reduction because of interposition.

Comminuted. For the comminuted type, fragmentation of the upper shaft is present and the pectoralis major may retract a large fragment; however, because the head and tuberosities are held in neutral rotation by the rotator cuff, adequate alignment can usually be obtained with a light plastic spica applied with the patient sitting with the arm in neutral rotation, slight forward flexion, near the side. If this is successful, it may be preferable to attempting internal fixation; however, when circumstances permit, experienced surgeons may prefer open reduction and internal fixation or, there is minimal comminution, percutaneous pinning.

Two-part greater tuberosity displacement

Two-part greater tuberosity displacement is usually seen with an anterior dislocation that has reduced after relocation of the head. The segment is usually fragmented and one or all of its three facets for the rotator cuff and covering a portion of the articular surface. It is difficult to measure radiographically the exact amount of displacement present. Superior displacement is measured on the anteriorposterior view and posterior displacement on the axillary view. The defect in the head and the amount of coverage of the articular surface are measured, and the prominence of the greater tuberosity fragment is considered. CT scans, especially the axial cuts, can be helpful. If the greater tuberosity covers a part of the articular surface of the head, open reduction and cuff repair through a deltoid-splitting approach is preferred. Large greater tuberosity fracture fragments may be best treated by the deltopectoral approach rather than a deltoid-splitting approach.

Two-part lesser tuberosity displacement

Two-part lesser tuberosity displacement fractures are usually produced by muscle contraction as in seizures. Axillary view and CT scans are helpful in evaluation the amount of displacement. Occasionally, when

the lesser tuberosity would block internal rotation, especially when a piece of the articular surface is attached to it, open reduction, internal fixation, and repair of the subscapularis tendon are used.

Three-part displacements

In all 3-part displacements, one tuberosity remains attached to the head to rotate it and allow it some blood supply. An unimpacted, displaced surgical neck component is always present to allow the rotation to occur. One tuberosity is displaced. When the greater tuberosity is displaced, the head is rotated internally. When the lesser tuberosity is displaced, the head is rotated externally. The category is usually evident on the plain films. The Velpeau axillary view and CT scans can be helpful in showing the articular surface involvement. Open reduction and internal fixation through a deltopectoral approach is usually preferred. In 3-part greater tuberosity displacements, a prosthesis may be preferred when the soft-tissue attachments to the head are found at surgery to be frail or the patient is elderly.

Four-part fractures

As shown in Fig. 43, in a true 4-part fracture (lateral fracture-dislocation), the articular segment is displaced out of contact with the glenoid (i.e., dislocated), detached from the shaft and both tuberosities, and detached from its blood supply. The exception is the valgus-impacted type 4-part fracture, which, as will be discussed, is a less-displaced, borderline lesion. When the head has no significant soft-tissue attachments, prosthetic replacement is preferred with careful reattachment of the tuberosities and rotator cuff and meticulous aftercare.

Valgus-impacted 4-part fracture. The valgus-impacted 4-part fracture, depicted in Fig. 43, is borderline in the continuum of lateral displacement of the head that progresses from the minimal displacement category to this lesion and on to the 4-part fracture (lateral fracture-dislocation) category. For clarification, it has been placed in the present 4-segment diagram (Fig. 43) as a subtype 4-part lesion with an arrow to indicate it is the precursor to the 4-part fracture (lateral fracture-dislocation) but without lateral displacement of the head. Both tuberosities are fractured and displace enough to make room for the articular segment

to be impacted on the shaft and to be tilted into at least 45° valgus. In the valgus-impacted 4-part fracture there is no lateral displacement of the articular segment, so the medial periosteum may remain intact to allow some blood supply to the head. The prognosis for survival of the head is better than in true 4-part fractures (lateral fracture-dislocations). As stated above, my preferred treatment is nonoperative for the minimal displacement category and prosthetic replacement for true 4-part fractures (later fracture-dislocations). A marginal lesion of this type between these two categories with enough angulation of the head to justify surgery, is explored by extending the tear in the rotator interval, with care taken to avoid injury to the blood supply, and if enough soft tissue is attached to the head, disimpaction and internal fixation is considered. When the 4-segment system criteria for exploring and intraoperative findings for decision making are used, the diagnosis of impacted valgus 4-part fracture and disimpaction has been infrequent. It is difficult for surgeons to agree on the incidence and treatment of a borderline displacement, such as the valgus-impacted 4-part fracture. Accurate measurement of angulation on plain films is difficult because of angle of valgus or varus is altered by rotation the humeral and because of the round shape of the head. In the 4-segment system, angulation of less than 45° is in the minimal displacement category. Transitory subluxation, as occurs at time with minimal displacements, can be misleading as to the height of the head in reference to the tuberosities and glenoid. In the valgus-impacted 4-part fracture, the articular segment should be angulated without lateral displacement, causing the upper humerus to resemble an ice cream cone. True 4-part fractures (lateral fracture-dislocations) are easy to distinguish in plain films except in marginal displacements, where the final decision between performing disimpaction and using a prosthesis depends on the quality of the soft-tissue attachments on the articular segment observed intraoperatively.

Fracture-dislocations

As shown in Fig. 41, some 2-part and 3-part displacements and all 4-part displacements are fracture-dislocations, because the head is out of contact with the glenoid. With anterior dislocations, the greater tuberosity is displaced prior to lesser tuberosity displacement, and with posterior dislocations, the lesser tuberosity is displaced prior to greater tu-

berosity displacement, as can be seen in Fig. 43. In 4-part fracture-dislocations, both tuberosities are fractured, and although the tuberosities may be held together by the soft-tissue rather than retracted, the head is detached and dislocated. The authors preferred treatment is closed or open reduction for 2-part fracture-dislocations; open reduction and internal fixation for 3-part fracture-dislocations, unless as discussed above, the soft-tissue attachments to the head are frail and the patient is elderly; and a prosthesis for 4-part fracture-dislocations.

Articular surface defects

Impression fractures. Large impression fractures, as illustrate in Fig. 41, are usually associated with posterior dislocations and pose a diagnostic pitfall. Axillary views are the key to avoid missing them, and CT scans are helpful in evaluating them. Treatment depends upon the size of the head defect and duration of the dislocation.

Head-splitting fractures. To quote from the initial description of the 4-segment classification, head-splitting fractures usually result from a central impact which may extrude fragments of cartilage both anteriorly and posteriorly. The articular surface is fragmented into many disconnected pieces. A prosthesis is usually required. A recently published article misstated that the splitting of the head fracture was not included in the original 4-segment classification.

11.2 AO-Classification of proximal humeral fractures [63, 91]*

The clinical basis for this classification was provided by a radiographic analysis of 930 surgically treated fractures of the proximal humerus on file at AO documentation centre. 200 cases were excluded because of poor radiograph quality, incomplete records, or open epiphyses, leaving a final data base of 730 fractures. The standard AO alpha numerical system has been adopted to this application following the interrelated themes of fracture anatomy and vascular status of the articular segment. The classification recognizes both displaced (Neer criteria) and undis-

placed fractures and provides adequate specificity for documentation as part of the AO documentation system for all fractures. In addition, it provides a framework for more detailed therapeutic and prognostic guidelines.

General considerations

The principle of the comprehensive classification of fractures of long bones

The fundamental principle of this classification is the division of all fractures of a bone segment into three types and their further subdivision into three groups and their subgroups, and the arrangement of these in an ascending order of severity according to the morphologic complexities of the fracture, the difficulties inherent in their treatment, and their prognosis.

Which type?... Which group?... Which subgroup?... These three questions and the three possible answers to each are the key to the classification.

The three *types* are labelled A, B, and C. Each type is divided into three *groups*: A1, A2, A3; B1, B2, B3; C1, C2, C3. Thus there are nine groups. As each group is further subdivided into three *subgroups*, denoted by a number .1, .2, .3, there are 27 subgroups for each segment. The subgroups represent the three characteristic variations within the group.

The colours green, orange, and red, as well as the *darkening arrows*, indicate the *increasing severity*: A1 indicates the simplest fracture with the best prognosis and C3 the most difficult fracture with the worst prognosis. Thus when one has classified a fracture one has established its severity and obtained a guide to its best possible treatment (Fig. 44a).

The anatomic location

This is designated by two numbers, one for the bone and one for its segment.

The long bones

Ulna and radius, and tibia and fibula are each considered as one bone. Therefore we have four long bones (Fig. 44b):

1 = humerus

2 = radius/ulna

3 = femur

4 = tibia/fibula

The bone segments

Each long bone has three segments: the proximal, the diaphyseal, and the distal segment (Fig. 42b). The malleolar segment is an exception and is classified as the fourth segment of the tibia/fibula (44-).

The segments are designated by numbers (Fig. 44c):

1 = the proximal segment

2 = the middle segment

3 = the distal segment

The proximal and distal segments of long bones are each defined by a square whose sides are the same length as the widest part of the epiphysis (exceptions: 31- and 44-).

Before a fracture can be assigned to a segment, one must first determine its centre. In a simple fracture the centre is at the level of the broadest part of the wedge. In a complex fracture the centre can only be determined after reduction.

Any fracture associated with a displaced articular component is classified as an articular fracture. If the fracture is associated only with an undisplaced fissure which reaches the joint, it is classified as metaphyseal or diaphyseal depending on the location of its centre.

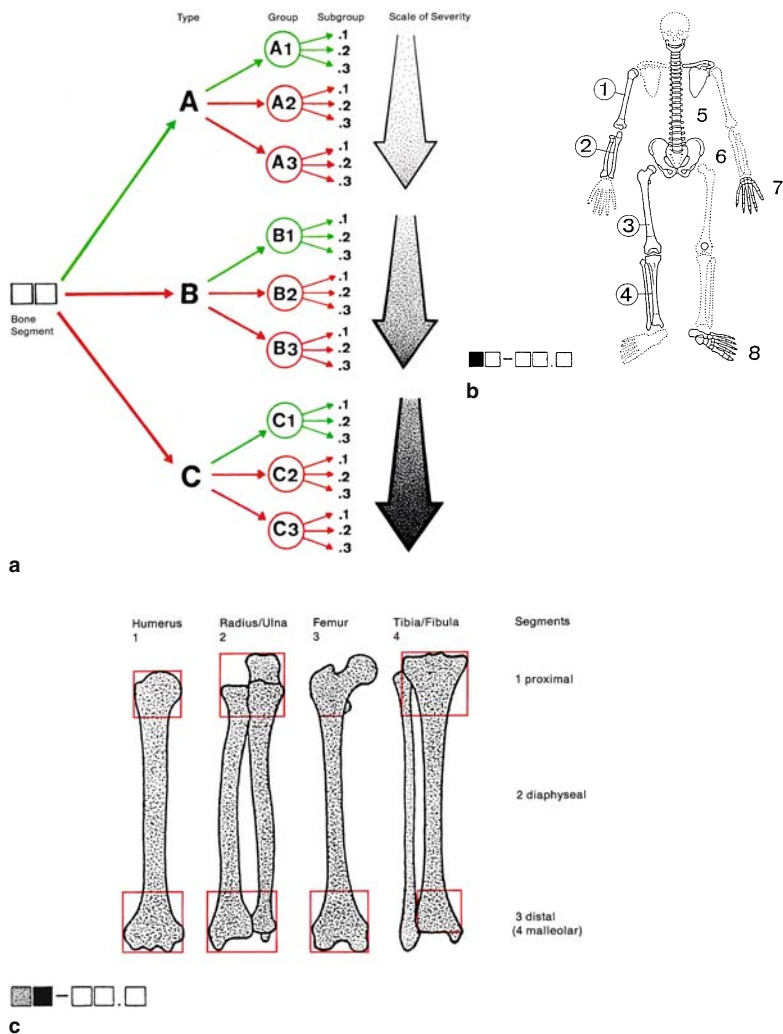
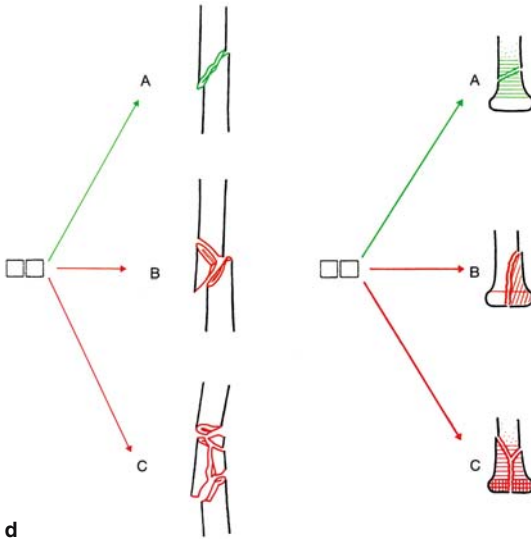
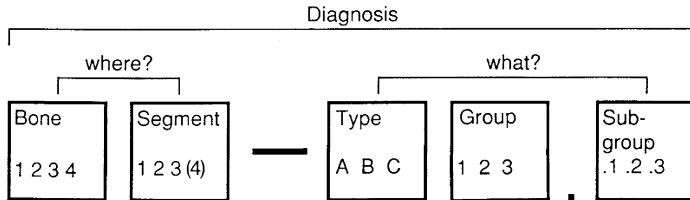


Fig. 44. The AO classification of fractures of the long bones. **a** The principle of the classification represented schematically. **b** The numbering of all bones or bone groups. The four long bones are specified with a *circle*. **c** The segments of the four long bones. The proximal and distal segments are defined by a square (exception: proximal femur)



d



e

Fig. 44d The fracture types of the diaphyseal (A simple, B wedge, C complex) and of most of the proximal and distal segments (A extraarticular, B partial articular, C complex articular) of long bones. **e** Alpha-numeric coding of the diagnosis (=location + morphological characteristic)

The fracture types

Diaphyseal segment

All fractures of the diaphyseal segment are either “simple” (type A) or “multifragmentary”. Multifragmentary fractures are either “wedge” fractures (type B) or “complex” fractures (type C).

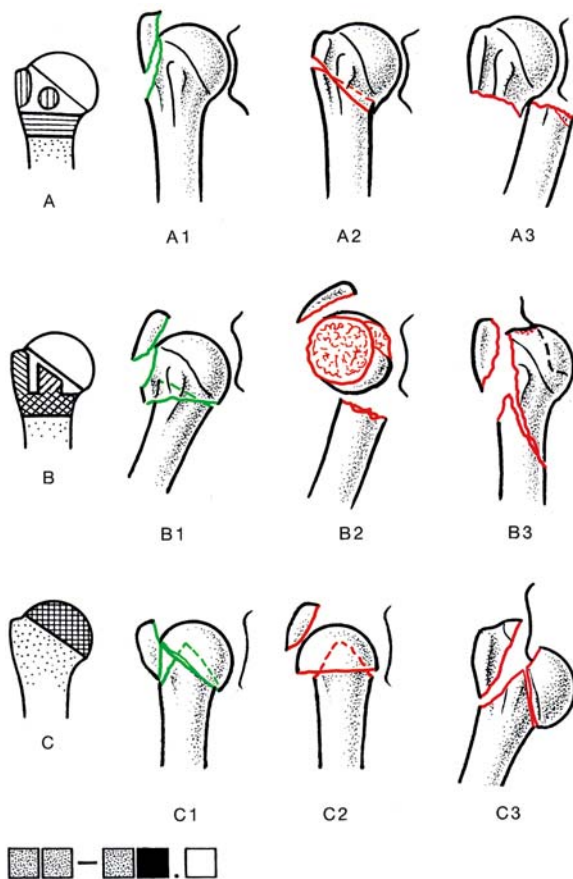


Fig. 44f The AO classification of proximal humeral fractures

Proximal and distal segments

In the proximal and distal segments the fractures are either “extraarticular” (type A) or “articular”. The articular fractures are either “partial articular” (type B) or “complete articular” (type C).

The three *exceptions* are: the *proximal humerus* (A=extraarticular unifocal, B=extraarticular bifocal, and C=articular), the *proximal fe-*

mur (A=trochanteric area, B=neck, C=head), and the *malleolar segment* (A=infrasyndesmotoc, B=transsyndesmotoc, and C=suprasyndesmotoc) (Fig. 44 d).

The coding of the diagnosis

The diagnosis of a fracture is obtained by combining its anatomic location with its morphologic characteristic. The answers o the questions “Where?”... and “What?”... are the key to the diagnosis.

An alpha-numeric coding system was chosen to express the diagnosis in order to facilitate computer storage and retrieval. Two numbers are used to express the location of the fracture. These are followed by a letter and two numbers which express the morphological characteristics of the fracture (Fig. 44 e).

Example of the coding of a fracture of a diaphyseal segment: 32-B2.1

3	2-	B	2	.1
Femur	diaphysis	wedge fracture	bending wedge	subtrochanteric

Example of the coding of a fracture of a distal segment: 33-C3.2

3	3-	C	3	.2
Femur	distal	complete	multifragmentary	metaphyseal multifragmentary

Humerus proximal (Fig. 44 f)

A = Extraarticular unifocal fracture

- A1 Extraarticular unifocal fracture, tuberosity
 - .1 greater tuberosity, not displaced
 - .2 greater tuberosity, displaced
 - .3 with a glenohumeral dislocation
- A2 Extraarticular unifocal fracture, impacted metaphyseal
 - .1 without frontal malalignment
 - .2 with varus malalignment
 - .3 with valgus malalignment
- A3 Extraarticular unifocal fracture, nonimpacted metaphyseal
 - .1 simple, with angulation
 - .2 simple, with translation
 - .3 multifragmentary

B = Extraarticular bifocal fracture

- B1 Extraarticular bifocal fracture, with metaphyseal impaction
 - .1 lateral+greater tuberosity
 - .2 medial+lesser tuberosity
 - .3 posterior+greater tuberosity
- B2 Extraarticular bifocal fracture, without metaphyseal impaction
 - .1 without rotatory displacement of the epiphyseal impaction
 - .2 with rotatory displacement of the epiphyseal fragment
 - .3 multifragmentary metaphyseal+one of the tuberosities
- B3 Extraarticular bifocal fracture, with glenohumeral dislocation
 - .1 “vertical” cervical line+greater tuberosity intact+anterior and medial dislocation
 - .2 “vertical” cervical line+greater tuberosity fractured+anterior and medial dislocation
 - .3 lesser tuberosity fractured+posterior dislocation

C = Articular fracture

- C1 Articular fracture, with slight displacement
 - .1 cephalotubercular, with valgus malalignment
 - .2 cephalotubercular, with varus malalignment
 - .3 anatomical neck
- C2 Articular fracture, impacted with marked displacement
 - .1 cephalotubercular, with valgus malalignment
 - .2 cephalotubercular, with varus malalignment
 - .3 transephalic and tubercular, with varus malalignment
- C3 Articular fracture, dislocated
 - .1 anatomical neck
 - .2 anatomical neck and tuberosities
 - .3 cephalotubercular fragmentation

11.3 Classification of proximal humeral fractures according to Habermeyer [17]

In consideration of the four-segment concept of Neer as well as the prognostic important graduation of the height of the fracture, the following classification was developed (Fig. 45):












Type	I	II	III
0	 <p>nondisplaced or "one-part fracture"</p>		
A	 <p>greater tuberosity</p>	 <p>lesser tuberosity</p>	
B	 <p>2</p>	 <p>3</p>	 <p>4-part/ surgical neck</p>
C	 <p>2</p>	 <p>3</p>	 <p>4-part/ anatomical neck</p>
X	 <p>anterior fracture dislocation</p>	 <p>posterior fracture dislocation</p>	

Fig. 45. Classification of humeral head fractures according to Habermeyer. (From [17])

- **Type-0-fracture:** nondislocated one part fracture
- **Type-A-fracture:** includes 2-part fractures with avulsion of the greater (Type A I) and the lesser tuberosity (Type A II)
- **Type-B-fracture:** occurs at the surgical neck and can exhibit 2 parts (surgical neck fracture, Type B I), 3 parts (surgical neck fracture + one tubercle, Type B II), or 4 parts (surgical neck fracture+greater and lesser tuberosities, Type B III).
- **Type-C-fracture:** occurs at the anatomical neck and represents a higher risk for humeral head necrosis; the graduation into 2- (Type C I), 3- (Type C II), and 4-part-fractures (Type C III) are identical to type B fractures.
- **Type-X-fracture:** represents anterior or posterior fracture dislocations. This denotation is added to Type A, B, or C.

11.4 Surgical classification of sequelae of proximal humerus fracture according to Boileau et al. [15] *

The inconsistent results reported with the use of shoulder prosthesis to treat fracture sequelae were partly due to this enormous variability in the anatomic lesions and the resulting comparisons between very heterogeneous groups of sequelae. Starting from this basis, the authors determined that the first logical step was to try to categorize the sequelae of fractures of the proximal humerus. A study of the natural history of the different fractures and how they developed into their sequelae allowed them to understand the lesions that clinically presented later. By studying the initial radiographs and those at later stages, and by reviewing the operative notes, the authors were able to distinguish 4 basic pathologic types of lesions that, when present, dominated the clinical picture and allowed the fracture sequelae to be grouped as follows (Fig. 46):

- **Intracapsular/impacted fracture sequelae**
 - Type 1: cephalic collapse or necrosis
 - Type 2: locked dislocations or fracture-dislocations
- **Extracapsular/disimpacted fracture sequelae**
 - Type 3: surgical neck nonunions
 - Type 4: severe tuberosity malunions

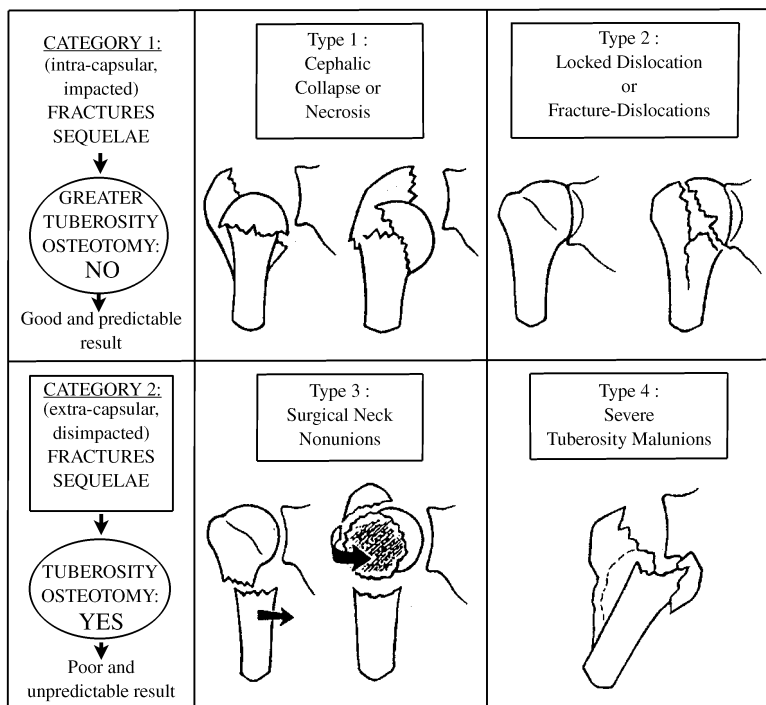


Fig. 46. Surgical classification of sequelae of proximal humeral fracture: four types of sequelae

Type 1: *humeral head collapse or necrosis with minimal tuberosity malunion.* The initial fractures in this group were dominated by 3- and 4-part fractures impacted either in valgus or in varus, leading to slight malunion of the tuberosities.

Type 2: *locked dislocations of fracture-dislocations.*

Type 3: *nonunion of the surgical neck.* Nonunions of the surgical neck followed either nonoperative 3-part fractures, with rotation of the humeral head fragment and significant displacement of the greater tuberosity, or 2- and 4-part fractures that had undergone primary surgery.

Type 4: *severe malunion of the tuberosities.* The initial fracture was a displaced or dislocated 4-part fracture with disimpaction of the head.

11.5 Classification of periprosthetic humeral fractures according to Wright and Cofield [72, 139]*

The *fracture patterns* were defined in relationship to the distal tip of the stem of the implant.

- A **type-A fracture** was centred at the tip and extended proximally more than one-third of the length of the stem.
- A **type-B fracture** was also centred at the tip of the stem but had less proximal extension.
- A **type-C fracture** involved the humeral shaft distal the tip of the prosthesis and extended into the distal humeral metaphysis.

The *angulation of the fracture* were graded as

- **None**
- **Mild:** more than 0 to 15° angulation
- **Moderate:** 16 to 30° of angulation
- **Severe:** more than 30° of angulation

The *displacement of the fracture* were graded as

- **None**
- **Mild** displacement of less than one-third of diameter of the shaft
- **Moderate** displacement of one to two-thirds of the diameter of the shaft
- **Severe** displacement of more than two-thirds of the diameter of the shaft

12.1 Classification of scapula fractures according to Euler and Rüedi [37]

Basically scapular fractures can be classified into intracapsular and extracapsular fractures. This classification is to be geared to anatomical structures and represents an ascending order of the injury severity. The aim is to give a prognosis to the expected loss of function (Fig. 47).

- A Fractures of the body
Scapula blade, isolated or comminuted
- B Fractures of the processes
 - B1 Spine
 - B2 Coracoid process
 - B3 Acromion
- C Fractures of the scapular neck
 - C1 Anatomical neck
 - C2 Surgical neck
 - C3 Surgical neck with
 - a) Fracture of the clavicle and the acromion
 - b) Tear of the coracoclavicular and coracoacromial ligaments
- D Articular fractures
 - D1 Glenoid rim fracture
 - D2 Fracture of the glenoid fossa
 - a) With inferior fragment of the glenoid
 - b) With horizontal split of the scapula
 - c) With coracoglenoideal bloc formation
 - d) Comminuted fractures
 - D3 Fracture combination with scapula neck fracture and fracture of the body respectively
- E Fracture combination with humeral head fractures

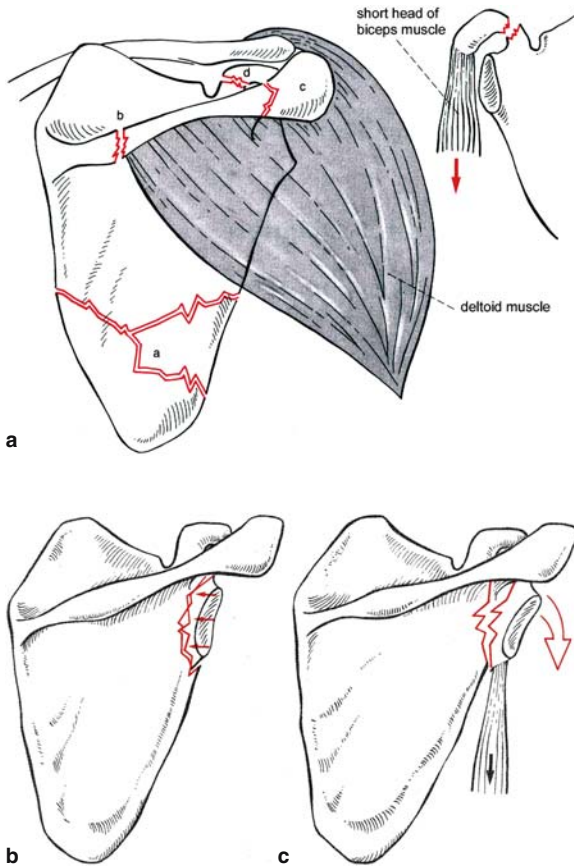
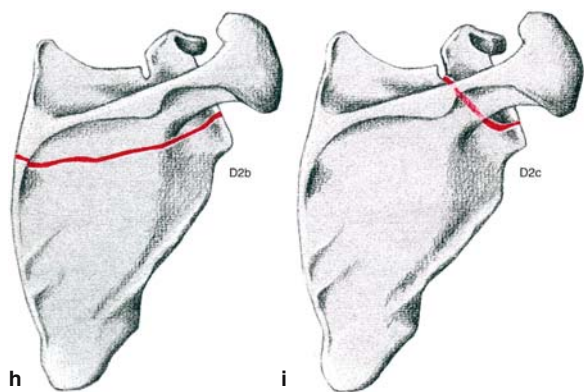
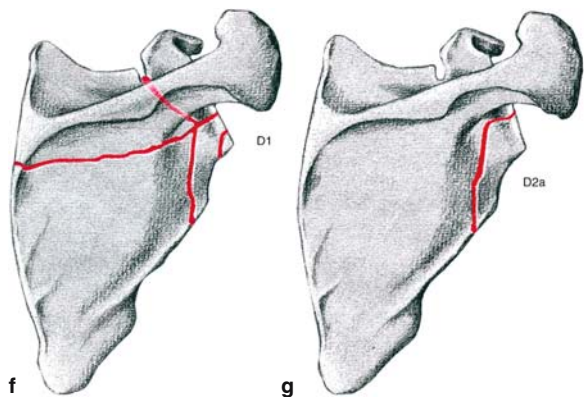
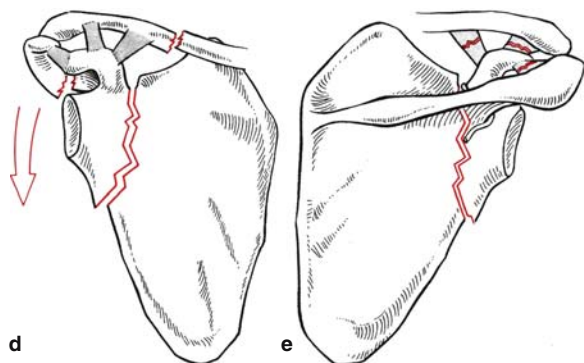


Fig. 47. Classification of scapular fractures. **a** Scapular fractures, group A, fractures of the body (*a*); and group B, fractures of the processes: B1, spine (*b*), B2, coracoid process (*d*); B3, acromion (*c*). **b** Fracture of the anatomic neck, medial impression (C1 *a*). **c** Fracture of the anatomic neck, lateral tilt of the glenoid (C1 *b*). **d** Fracture of the surgical neck (C3 *a*). With concomitant clavicular fracture the coracoclavicular and coracoacromial ligaments remain intact. **e** Fracture of the surgical neck with dislocation (C3 *b*). The coracoclavicular and coracoacromial ligaments are torn. **f** Glenoid fractures (group D). Glenoid rim fracture (*D1*). **g** Glenoid fracture: fracture of the glenoid fossa with inferior glenoid fragment (*D2a*). **h** Glenoid fracture with horizontal split of the scapula (*D2b*). **i** Glenoid fracture with coracoglenoideal bloc formation (*D2c*). (From [37])



12.2 Classification of scapular fractures according to DeCloux and Lemerle [30]

DeCloux and Lemerle [30] divided the scapular fractures anatomically into three types (Fig. 48):

- **Type I:** fractures of the body
- **Type II:** fractures of the apophysis
- **Type III:** fractures through the superior lateral angle

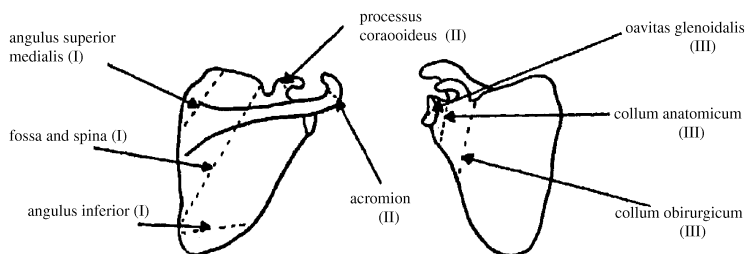


Fig. 48. Classification of scapular fractures. (From [30])

12.3 Classification of scapular fractures according to Zdravkovic and Damholt [143]

Zdravkovic and Damholt specified the type III scapular fractures according to DeCloux by describing the site of fracture and the degree of displacement measured in mm on the X-ray films.

Site of fracture:

- Anatomical neck
- Surgical neck
- Surgical neck+glenoid cavity

Degree of displacement (mm):

- < 5
- 5–9
- 10–19
- > 20

12.4 Classification of intraarticular scapular fractures according to Ideberg et al. [61]*

Intraarticular fractures were classified into five main types based on conventional AP and lateral radiographs (Fig. 49). Chip fragment fractures, often seen in shoulder dislocations, are included in this classification as fracture type 1, with subdivision into two types, depending on whether the size of the fragment is less or equal (type 1 A) or larger (type 1 B) than 5 mm when measured directly on the film.

- **Type 1:** anterior glenoid rim fracture. Type 1 A with a fracture fragment of 5 mm or less, and type 1 B with a fracture fragment larger than 5 mm.
- **Type 2:** inferior glenoid fracture involving part of the neck.
- **Type 3:** superior glenoid fracture extending through the base of the coracoid process.
- **Type 4:** horizontal fracture involving both scapula neck and body. Fracture line always runs inferior to the spine of the scapula.
- **Type 5:** horizontal fracture (as in type 4), with an additional complete or incomplete neck fracture.

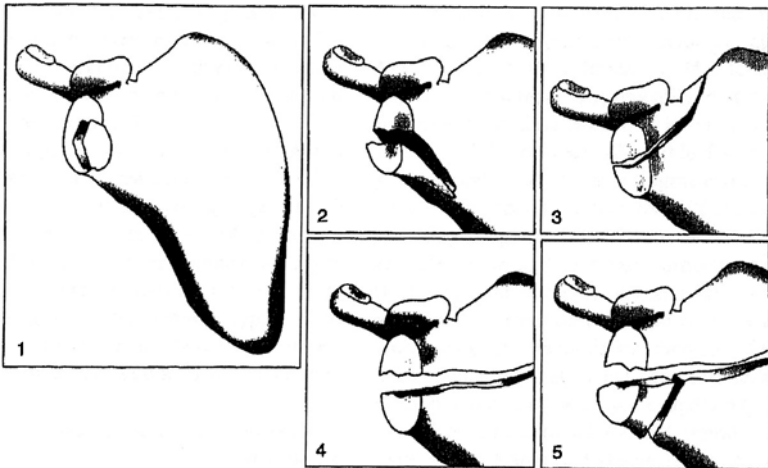


Fig. 49. Classification of intraarticular scapular fractures. (From [61])

12.5 Classification of fractures of the glenoid cavity according to Goss [48]

Fractures of the glenoid cavity make up 10% of scapular fractures, no more than 10% of which are significantly displaced.

This classification scheme outlines the various mechanisms of injury and fracture patterns that can occur. For the purpose of this discussion, one need consider only whether the glenoid rim or the glenoid fossa is fractured. Fractures of the glenoid rim occur when a laterally applied high energy force drives the humeral head against the glenoid margin.

Fracture of the glenoid fossa occurs when a laterally applied high-energy force drives the humeral head directly into the glenoid cavity. The fracture generally begins as a transverse disruption, which then propagates in one of several possible directions depending on the vector of the traumatic force. The degree of resultant incongruity of the articular surface is of prime concern.

The author distinguishes six different types of glenoid fractures (Fig. 50):

- Type I: glenoid rim fractures
 - Type Ia: anterior rim fracture
 - Type Ib: posterior rim fracture
- Type II: fracture line through the glenoid fossa exiting at the lateral border of the scapula
- Type III: fracture line through the glenoid fossa exiting at the superior border of the scapula
- Type IV: fracture line through the glenoid fossa exiting at the medial border of the scapula
- Type Va: combination of types II and IV
- Type Vb: combination of types III and IV
- Type Vc: combination of types II, III, and IV
- Type VI: comminute fracture

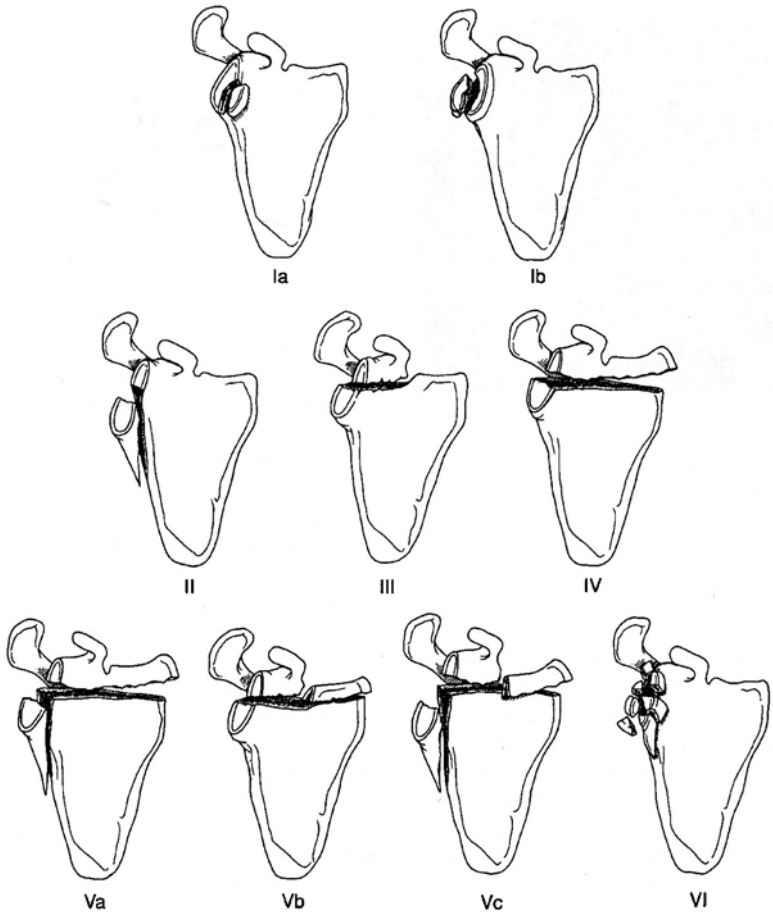


Fig. 50. Classification of fractures of the glenoid cavity. (From [48])

12.6 Classification of glenoid neck fractures according to Goss [48]

Fractures of the glenoid neck make up 25% of scapular fractures; of that number, 10% or fewer (2.5% of the total) are significantly displaced.

This classification scheme is based on whether these injuries are minimally or significantly displaced. If significant displacement exists, it may be in either the translational or the rotatory plane.

Fractures of the glenoid neck may be caused by a direct blow over the anterior or posterior aspect of the shoulder, a fall on an outstretched arm, or a fall on the superior aspect of the shoulder. Displacement may occur if the fracture is complete, with the fracture line exiting through both the lateral and superior scapular margins. If the superior support structures (the clavicle-AC-joint-acromion strut or the coracoid process-coracoclavicular ligaments linkage) are disrupted, displacement is especially likely.

Two different types of glenoid neck fractures have to be distinguished (Fig. 51):

- **Type I** includes all minimally displaced fractures.
- **Type II** includes all significantly displaced fractures (either translational or angulatory displacement).

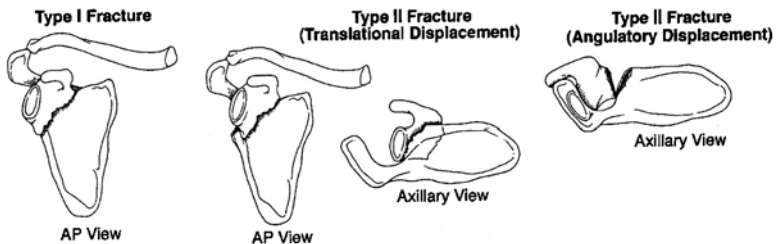


Fig. 51. Classification of fractures of the glenoid neck. *AP* anteroposterior. (From [48])

12.7 Types of traumatic ring/strut disruption of the superior shoulder suspensory complex according to Goss [47, 48]

The superior shoulder suspensory complex (SSSC) is a bone-soft-tissue ring at the end of a superior and an inferior bone strut (Fig. 52a). The ring is composed of the glenoid process, the coracoid process, the coracoclavicular ligaments, the distal clavicle, the AC joint, and the acromial process. The superior strut is the middle third of the clavicle. The inferior strut is the lateral scapular body and spine. Each individual structure has its own particular functions. The complex as a whole maintains a normal stable relationship between the scapula and upper extremity and the axial skeleton, allows limited motion to occur through the AC joint and the coracoclavicular ligaments, and provides a firm point of attachment for several soft-tissue structures. Traumatic disruptions of one of the components of the SSSC (Fig. 52b) are common. They tend to be minor injuries, however, since such single disruptions usually do not significantly compromise the overall integrity of the complex. If the traumatic force is sufficiently severe or adversely directed, the ring may fail in two or more places (termed a “double disruption”), a situation in which significant displacement at both the individual sites and of the SSSC as a whole frequently occurs. Similarly, a disruption of one portion of the ring combined with a fracture of one of the struts or fractures of both struts also creates a potentially unstable anatomic situation. This, in turn, often leads to adverse long-term functional consequences, including delayed union, nonunion, and malunion; subacromial impingement; decreased strength and muscle-fatigue discomfort due to altered shoulder mechanics; neurovascular compromise due to a drooping shoulder; and glenohumeral degenerative joint disease. Consequently, injuries of the SSSC need to be carefully evaluated for the presence of a double disruption. Computed tomography with reconstructions is often necessary to make a definitive diagnosis. If unacceptable displacement is present, surgical reduction and stabilization of one or more of the injury sites is necessary. Frequently, operative management of one of the injury sites will satisfactorily reduce and stabilize the second disruption indirectly. Fractures of the glenoid, coracoid, and acro-

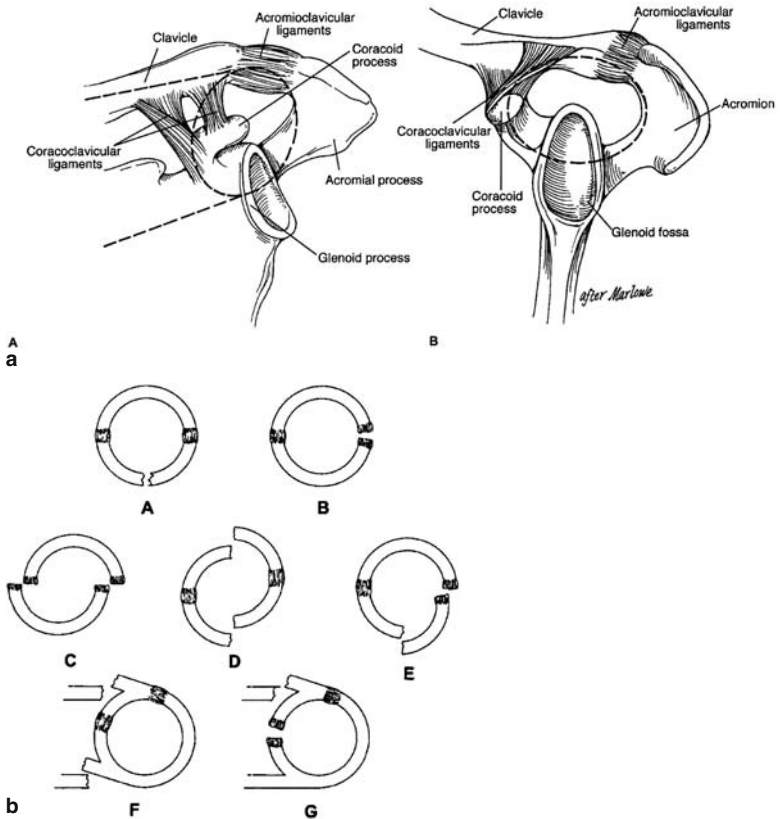


Fig. 52. a Superior shoulder suspensory complex. A AP view of the bone/soft tissue ring and superior and inferior bone struts. B Lateral view of the bone/soft tissue ring. b Types of traumatic ring/strut disruptions. Single disruptions of the bone/soft tissue ring may be a break (A) or a ligament disruption (B). Double disruptions of the bone/soft tissue ring may be a double-ligament disruption (C), a double break (D), or a combination of a bone break and a ligament disruption (E). Other double disruptions may be a break of both struts (F) or a break of one strut and a ring disruption (G)

mial process may each be part of a double disruption and require surgical management. All of the various combinations cannot be detailed, and some are extremely rare.

■ *Single disruptions*

Type A: single disruption by a break

Type B: single disruption by a ligament disruption

■ *Double disruptions*

Type C: double-ligament disruption

Type D: double break

Type E: combination of bone break and a ligament disruption

Type F: break of both struts

Type G: break of one strut and a ring disruption

13.1 Grading of chondromalacia according to Outerbridge [106]

Outerbridge described in 1961 the macroscopic aspect of changes of the articular cartilage for the articular surface of the patella. Meanwhile this classification is generally used for the description of articular cartilage lesions.

The macroscopic changes of chondromalacia can be classified into four grades:

- In **grade 1** there are softening and swelling of the cartilage.
- In **grade 2** there are fragmentation and fissuring in an area half an inch or less in diameter.
- **Grade 3** is the same as grade 2 but an area more than half an inch in diameter is involved.
- In **grade 4** there is erosion of cartilage down to bone.

13.2 Classification of glenoid morphology in primary glenohumeral osteoarthritis according to Walch et al. [134]*

The authors classified the glenoid morphology into three types base on the CT scan findings out of 113 patients (Fig. 53). Intraobserver reproducibility and interobserver reliability were good with a kappa index that ranged from 0.65 to 0.70.

- **Type A** (59%): the humeral head was centred, and the resultant strengths were equally distributed against the surface of the glenoid. Glenoid retroversion averaged 11.5° (standard deviation [SD], 8.8°). The erosion may be minor – **type A1** (43%) – or major – **type A2**

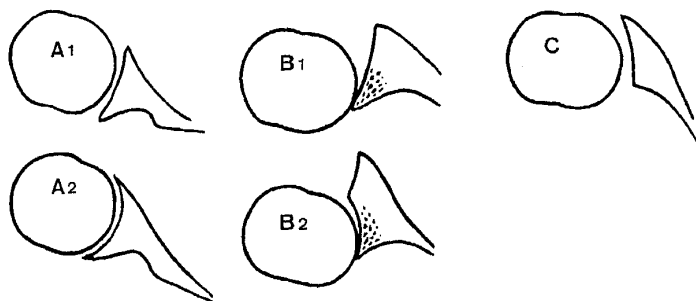


Fig. 53. Different morphological types of the glenoid in primary glenohumeral osteoarthritis

(16%) marked by a central erosion that led to a centred glenoid cupula. In advanced cases, the humeral head protruded into the glenoid cavity.

- **Type B** (32%): the humeral head was subluxated posteriorly, and the distributed loads were asymmetric. The CT scan revealed numerous anatomic changes, more pronounced on the posterior margin of the glenoid. The retroversion averaged 18° (SD, 7.2°). Two subgroups were identified: **B1** (17%) showed narrowing of the posterior joint space, subchondral sclerosis, and osteophytes, and **B2** (15%) demonstrated a posterior cupula that gave an unusual biconcave aspect of the glenoid. In type B2, there was an excessive retroversion of the glenoid according to Friedman et al. [41], but the value of the retroversion does not explain the biconcavity of the glenoid.
- **Type C** (9%): this type of glenoid morphology was defined by a glenoid retroversion of more than 25° , regardless of the erosion. The retroversion was of dysplastic origin, and the humeral head was well centred or slightly subluxated posteriorly. The average retroversion was 35.7° (SD, 5.9°).

13.3 Assessment of humeral head subluxation according to Walch et al. [134]

The position of the humeral head with respect to the glenoid was evaluated using an index of subluxation, which is the relative part of the humeral head posterior to the bisecting line of the glenoid (Fig. 54). An index between 45 and 55% represents a centred humeral head, 0% is an anterior dislocation, and 100% is a posterior dislocation.

$$\text{Index} = D/E$$

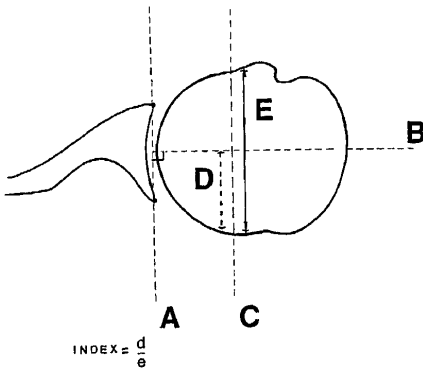


Fig. 54. Method used to evaluate the humeral head subluxation. *A* Line tangent to the anterior and posterior edges of the glenoid fossa. *B* Line bisecting the glenoid. *C* Line parallel to *A* transecting the medial third of the humeral head. *D* Relative part of the humeral head posterior to *B*. *E* Diameter of the humeral head on line *C*. *D*, *E*, Index of subluxation. An index between 45 and 55% indicates a well-centred humeral head. An index of more than 55% indicates posterior subluxation and below 45% indicates anterior subluxation

13.4 Classification of vertical glenoid morphology according to Habermeyer [51a]*

In the true antero-posterior view the authors identified four different types of inclination deformity of the glenoid due to a vertical line perpendicular to the inferior border of the X-ray film along the lateral base

of the coracoid (coracoid baseline) and along the superior and inferior glenoid rim (glenoid line).

In this investigation the coracoid baseline is reproducible because the ap-view is taken into a standardized standing position of the patient, so that the inferior border of the X-ray film is parallel to the bottom and the lateral base of the coracoid does not change with rotation of the scapula.

Type 0 (Fig. 55a) represents normal glenoids; the coracoid baseline and the glenoid line run parallel. Both lines intersect below the inferior glenoid rim in type 1 (Fig. 55b) glenoids. In type 2 (Fig. 55c) glenoids,

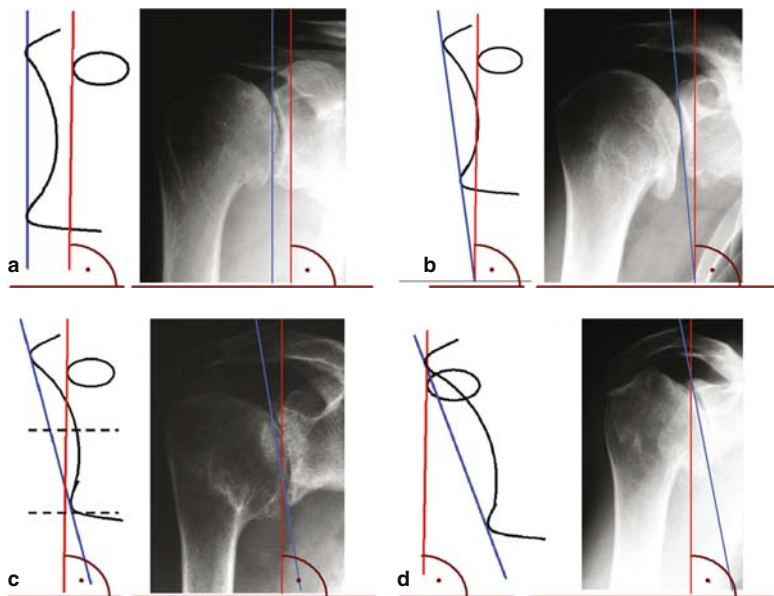


Fig. 55. Classification of glenoid inclination. a Inclination type 0: the coracoid baseline (red) and the glenoid line (blue) run parallel (the brown line represents the inferior border of the X-ray film). b Inclination type 1: the coracoid baseline and the glenoid line intersect below the inferior glenoid rim. c Inclination type 2: the coracoid baseline and the glenoid line intersect between the inferior glenoid rim and the centre of the glenoid. d Inclination type 3: the coracoid baseline and the glenoid line intersect above the coracoid base

the coracoid baseline and the glenoid line intersect between the inferior glenoid rim and the centre of the glenoid. In type 3 (Fig. 55 d) glenoids the lines intersect above the coracoid base.

13.5 Classification of osteoarthritis with massive rotator cuff tears according to Favard et al. [38]*

- **Group 1:** is characterised by upward migration of the humeral head, superior gleno-humeral joint space narrowing, an acromion changed in shape due to the imprint of the humeral head and subacromial arthritis (Fig. 56 a).
- **Group 2:** this group is characterised by central gleno-humeral joint space narrowing and with little alteration in the shape of the acromion which does not have a humeral head imprint (Fig. 56 b).
- **Group 3:** this group is characterised by signs of bony destruction in the form of lysis of either the head or the acromion. The bony elements not affected by the lysis do not undergo any modification in their shape, for example, the greater tuberosity is not eroded and the acromion does not have a humeral head imprint. Gleno-humeral joint space narrowing is either minimal or nonexistent (Fig. 56 c).

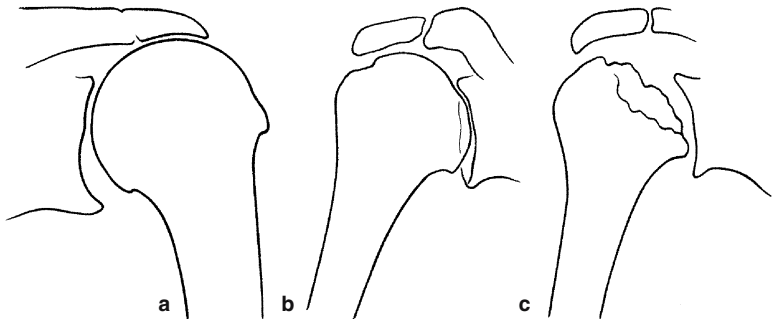


Fig. 56. a Group 1. Superior glenohumeral wear: upward migration of the humeral head. Acromion modification with inferior concavity wear. b Group 2. Central narrowing of the glenohumeral joint. Little alteration in the shape of the acromion without humeral head imprint. c Group 3. Lysis of either the humeral head or the acromion

There was no age difference between the three groups. The acromio-humeral joint space narrowing was significantly greater in group 1 than in group 3 and 2.

13.6 Classification of cuff tear arthropathy according to Seebauer et al. [132]

Analysis of cuff tear arthropathy and failed treatment has led to a biomechanical classification of cuff tear arthropathy. Four distinct groups have been formed on the basis of the biomechanics and clinical outcomes of arthroplasty. The four types are distinguished by the degree of superior migration from the centre of rotation and the amount of instability of the centre of rotation. This classification (Table 5) has proposed benefits in surgical decision-making for optimal implant type, goals of reconstruction, and outcomes.

Table 5. Classification of cuff-tear arthropathy. (From [132])

Type IA: centred stable (Fig. 57 a)	Intact anterior restraints	Minimal superior migration	Dynamic joint stabilization	Acetabularization of coracoacromial arch and femoralization of humeral head
Type IB: centred medialized (Fig. 57 b)	Intact anterior restraints; force couple intact/ compensated	Minimal superior migration	Compromised dynamic joint stabilization	Medial erosion of the glenoid, acetabulari- zation of coracoacromial arch, and femoralization of humeral head
Type IIA: decentred limited stable (Fig. 57 c)	Compromised anterior restraints; com- promised force couple	Superior translation	Insufficient dynamic joint stabilization	Minimum stabilization by coracoacromial arch, superior-medial erosion and extensive acetabularization of coracoacromial arch and femoralization of humeral head
Type IIB: decentred unstable (Fig. 57 d)	Incompetent anterior structures	Anterior superior escape	Absent dynamic joint stabilization	No stabilization by coracoacromial arch; deficient anterior structures

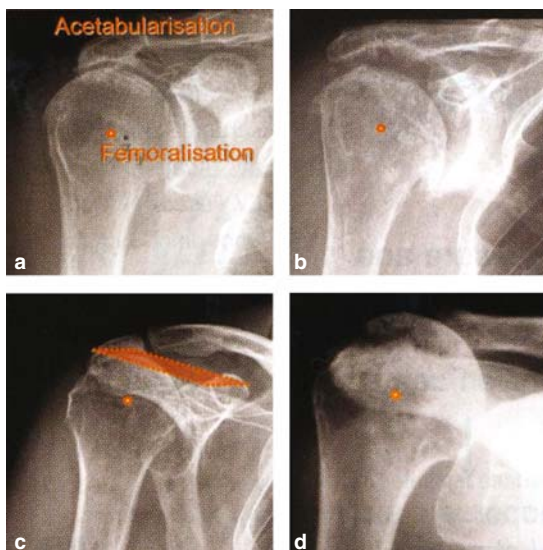


Fig. 57. Biomechanical classification of cuff-tear arthropathy. **a** Type IA: centred, stable. **b** Type IB: centred, medialized. **c** Type IIA: de-centred, limited stabilization. **d** Type IIB: de-centred unstable. (From [132])

13.7 Classification of cuff tear arthropathy according to Hamada et al. [55] (Fig. 58 a–e)

Roentgenographic grades of massive cuff tears were proposed. These were based chiefly on the acromiohumeral interval (AHI), which has been considered in the literature to be a sensitive indicator for the full-thickness cuff tear. Five grades were classified:

- **Grade 1:** the AHI was more than 6 mm
- **Grade 2:** the AHI was 5 mm or less
- **Grade 3:** acetabularization was added to the Grade 2 characteristics (The term acetabularization is defined as a concave deformity of the acromion undersurface. It has two subtypes:
 - an excavating deformity of the acromion
 - a deformity formed by the excessive spur along the coracoacromial ligament)

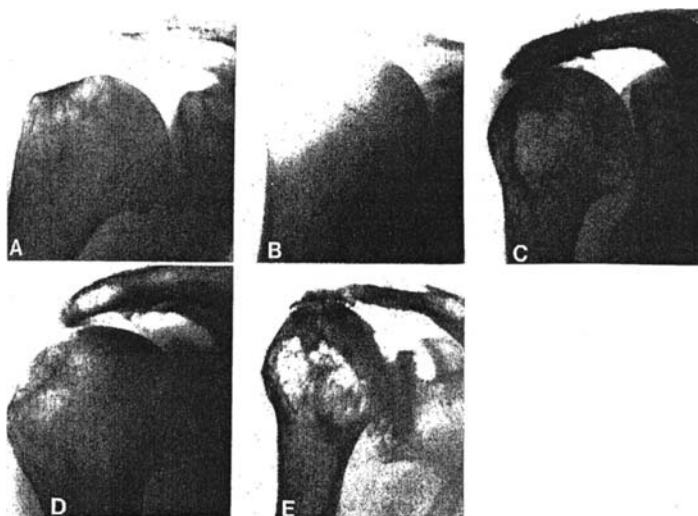


Fig. 58. Radiological classification of cuff-tear arthropathy. A Grade 1; B grade 2; C grade 3; D grade 4; E grade 5. (From [55])

- **Grade 4:** narrowing of the glenohumeral joint was added to the Grade 3 features
- **Grade 5:** comprised instances of humeral-head collapse, which is characteristic of cuff-tear arthropathy

13.8 Classification of glenoid erosion in glenohumeral osteoarthritis with massive rupture of the cuff according to Sirveaux et al. [120]

Radiological the authors defined four types of glenoid erosion. In type E0, the head of the humerus migrated upwards without erosion of the glenoid. Type E1 was defined by a concentric erosion of the glenoid. In type E2 there was an erosion of the superior part of the glenoid and in type E3 the erosion extended to the inferior part of the glenoid (Fig. 59).

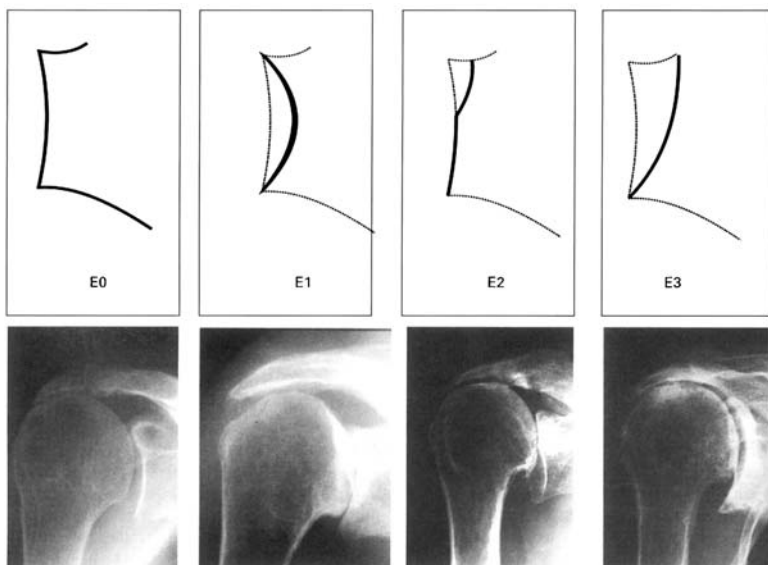


Fig. 59. Radiological classification of glenoid erosion in osteoarthritis with massive rupture of the cuff. (From [120])

13.9 Radiographic classification of dislocation arthropathy of the shoulder according to Samilson and Prieto [117]

The authors examined seventy-four shoulders with a history of single or multiple dislocations of the shoulder demonstrated radiographic evidence of glenohumeral arthropathy.

Radiographic evidence of arthrosis was graded as mild, moderate, or severe evaluated in the anteroposterior radiograph.

- **Mild arthrosis** was indicated by evidence on the anteriorposterior radiograph of either an inferior humeral or glenoid exostosis, or both, measuring less than 3 mm in height (Fig. 60a).
- **Moderate arthrosis** was indicated by evidence on the anteroposterior radiograph of either an inferior humeral or glenoid exostosis, or both, between 3 and 7 mm in height, with slight glenohumeral-joint irregularity (Fig. 60b).

- **Severe arthrosis** was indicated by evidence on the anteroposterior radiograph of either an inferior humeral or glenoid exostosis, or both, that was more than 7 mm in height, with narrowing of the glenohumeral joint and sclerosis (Fig. 60c).

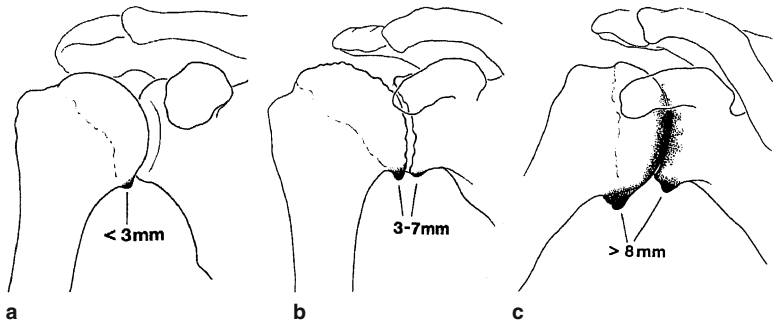


Fig. 60. Radiological classification of dislocation arthropathy. **a** Mild arthrosis evidence on the anteroposterior radiograph of an inferior humeral or glenoid exostosis, or both, measuring <3 mm. **b** Moderate arthrosis evidence on the anteroposterior radiograph of an inferior humeral or glenoid exostosis, or both, measuring between 3 and 7 mm, with slight glenohumeral-joint irregularity. **c** Severe arthrosis evidence on the anteroposterior radiograph of an inferior humeral or glenoid osteosis, or both, measuring >8 mm, with glenohumeral narrowing and sclerosis. (From [117])

14.1 Classification of osteonecrosis of bone according to Cruess [25]

Since the diagnosis of osteonecrosis is made on radiologic and clinical grounds, it must be emphasized that the insult that leads to either radiographic changes or symptoms must have occurred at least months earlier. There have been various attempts at staging the development of the lesion to aid in understanding the process and to apply appropriate therapy. The most widely recognized system of staging is that of Marcus et al. [83], but it has as a defect the fact that there is no prediagnostic stage. For this reason, a modification of the staging system first proposed by Arlet and Ficat [4] appears to be the most worthwhile. The modification is proposed because there are therapeutic implications to Stage 5, the phase at which acetabular changes are visible (Fig. 61).

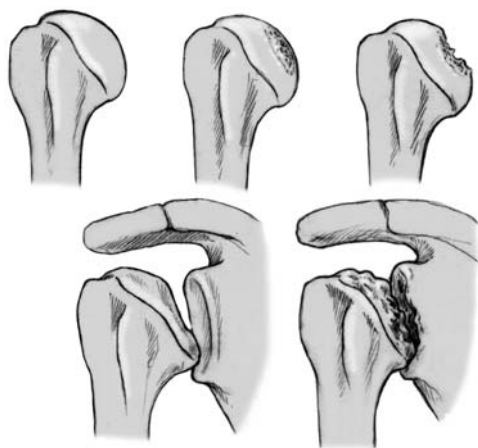


Fig. 61. Classification of osteonecrosis of bone modified for the humeral head according to Nové-Josseand and Basso [105a] based on Cruess [25]

- **Stage 1:** this is the preradiologic stage and is characterized by a total absence of radiologic features. Some patients will complain of a stiff, painful hip and there is occasionally even limitation of motion. Scintimetry may show either absence of uptake in areas of the femoral head or (and this is much more likely) increased uptake in the femoral head as a whole. Such an increase indicates that the area of osteonecrosis has already provoked a reparative response.
- **Stage 2:** this stage is characterized by radiologic evidence of repair in the presence of a femoral head with a well-preserved shape. A variety of radiologic changes are reported. Ficat and Arlet describe three forms (A) diffuse osteoporosis, (B) a sclerotic form, and (C) a mixed osteoporotic/sclerotic form. A fourth form may be recognized as a localized subchondral osteolytic lesion. It is reasonable to assume that the sclerotic changes represent a later stage in the development-beyond that of either osteolysis or osteoporosis – during which time the body has laid down appositional new bone as part of the repair process. However, with a preserved femoral head shape, this form is still classed in Stage 2.
- **Stage 3:** this stage is characterized by the classical radiographic feature of osteonecrosis, the so called “crescent sign”. The stage represents collapse of the subchondral bone with the area of collapse beginning characteristically in the anterolateral area of the femoral head, best seen on a lateral view or on tomograms. Changes vary from slight flattening to extensive collapse. This is a frequent observation in symptomatic patients. The relationship of the radiologic changes, symptom change, and clinical pathology would all favour the development of a subchondral fracture.
- **Stage 4:** there is extensive collapse of subchondral bone and severe deformity of the head due to flattening superiorly. This stage correlated with the operative findings of a separated, sometimes free, osteocartilagenous flap lying on depressed subchondral bone. Obviously, not all lesions may reach Stage 4.
- **Stage 5:** the difference between Stages 4 and 5 rests in the appearance of the acetabulum. This is normal in Stage 4, but shows pathologic changes in Stage 5. The reason for adding this stage relates to the rationale for therapy. As long as acetabular cartilage remains relatively normal, hemiarthroplasty is a reasonable therapeutic choice.

14.2 Classification of avascular necrosis of the humeral head according to Neer [102]

The pathologic changes that occur in the humeral head are similar to those occurring in the femoral head as described by Ficat and Arlet [147] and Springfield and Enneking [148] but with some differences. The differences are best explained by describing the point of maximum joint reaction force and the anatomical contour of the glenoid compared to that of the acetabulum. The glenoid is flat, and the point of maximum pressure on the head seems to occur when the arm has been raised about 90° . At this point the scapula has rotated 30° , so that the area of the head that is placed under maximum pressure is that contacting the glenoid when the humerus has been elevated 60° . This area of contact is the site where the humeral head consistently collapses in avascular necrosis and where maximum wear and sclerosis occur in osteoarthritis.

Avascular changes with collapse of the articular surfaces in the elbows of two paraplegic patients, as mentioned above, confirm the importance of pressure and load in the configuration of avascular necrosis of the humeral head. In their discussions of the aetiology of avascular necrosis, both Cruess [149] and Springfield and Enneking [148] pointed out that the alterations in the femoral head did not match the anatomical configuration of the blood vessels in the femoral head nor the random site of infarction that might occur if the infarcts were due to “sludging”. Since the location of the crescent sign and the later collapse at the head correspond to the point of maximum joint reaction force on the humeral head, Neer [102] believes the consistent location of the wedge-shaped area of infarction is largely due to pressure.

To assist in describing the indications and treatment of this condition, Neer has adapted the excellent classifications of Ficat and Enneking to the shoulder. As illustrated in Fig. 62.

- **Stage I.** Stage I disease shows only subtle changes that are not always definitely diagnostic. Recent developments with magnetic resonance imaging (MRI) are helpful. The head retains its normal shape. There may be slight mottling of the trabecular pattern or an area of subchondral decalcification. There may be no pain, but some patients do have pain. Patients with infarctional diseases (Gaucher's disease and

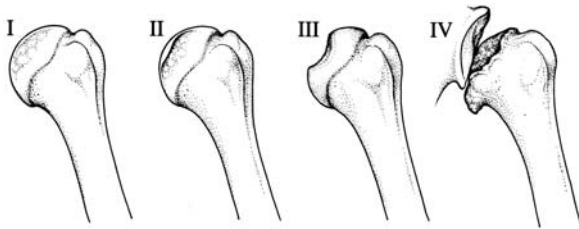


Fig. 62. Classification of avascular necrosis of the humeral head according to Neer [102]

sickle cell disease) have more very early pain. Unfortunately, at this time there is no infallible way to document the diagnosis.

- **Stage II.** Stage II disease has an articular surface that is grossly round when inspected at surgery, and although the articular cartilage can be indented on pressure in an area where it has lost the support of the subchondral bone, it returns to its normal shape. This is the area where a “meniscus sign” can be seen. Tomograms and MRI are especially helpful in evaluating the extent of head involvement. Pain is usually present and may be severe. The severe pain probably corresponds to minute fractures and the sudden slight collapse of subchondral bone.
- **Stage III.** Stage III disease is characterized by an area of wrinkled and loose articular cartilage. This corresponds to the wedge-shaped area of fracturing and collapse of subchondral bone. Eventually the edge of this detached cartilage may become torn, forming a flap. With each episode of collapse of the subchondral bone, the pain is intensified. Eventually the X-ray film shows a “step-off” phenomenon, and the diagnosis is quite obvious. The articular surface of the glenoid remains intact.
- **Stage IV.** Stage IV disease shows involvement of the articular surface of the glenoid due to the incongruity of the humeral head. As secondary arthritic changes occur, a ring of marginal excrescences develops around the head, particularly inferiorly, and the articular surface of the glenoid becomes worn unevenly, as in osteoarthritis. Because of the way the arms are used in everyday activities, the incongruous head presses more intensely on the posterior part of the gle-

noid, leading to uneven wear and eventually to a posterior subluxation. With the posterior subluxation, the posterior glenoid becomes rounded off and sclerotic, and an indentation develops in the head because of contact against the posterior edge of the glenoid. By this time, osteochondral bodies and a general synovitis of the joint are present.

14.3 Classification of the extend of osteonecrosis of the humeral head according to Hatstrup and Cofield [56]

The authors assessed the extent of osteonecrosis of the humeral head radiologically. The extent of involvement was classified from the maximum involvement shown on any single view. Four groups were defined: those with **less than one quarter** of the humeral head involved, those with involvement **between one quarter and one half** of the diameter of the humeral head, those with involvement **between one half and three quarters** of the humeral head, and those with **more than three quarters** of the diameters of the humeral head involved.

15.1 Variations in Involvement in rheumatoid arthritis [102]*

Low-grade, intermediate, and severe involvement. There is a great deal about rheumatoid arthritis that is poorly understood. We do not know its cause or have a specific diagnostic test. In our present state of ignorance, it is helpful in making clinical decisions to classify the disease as low-grade, intermediate, or severe.

Post-operative rehabilitation is much easier in those with mild disease. Bone loss is apt to occur more slowly, and they may develop marginal osteophytes similar to those seen in osteoarthritis.

In the more severe form of rheumatoid arthritis, there may be rapid destruction of the joint surfaces with early ascent of the humerus and involvement of the rotator cuff. If shoulder arthroplasties are postponed unnecessarily, severe bone loss and rotator cuff damage can occur needlessly. In one major rheumatoid hospital in the United States, patients underwent an average of four other major arthroplasties (hips, knees or elbows) prior to the first shoulder arthroplasty. The delays in performing shoulder arthroplasty undoubtedly contributed to their very high incidence of rotator cuff defects and severe glenoid bone loss.

Dry, wet, and resorptive. In addition to the variations in severity of the disease as discussed above, there are three clinical types of this condition. As illustrated in Fig. 63 A to C. In the **dry form** there is sclerosis, subchondral cysts, and loss of joint space. Minimal margin erosion is seen, and marginal osteophytes may form similar to those characteristic of osteoarthritis. The joints tend to be stiffer than in the other types of this disease. Muscle wasting may be intense in patients with juvenile rheumatoid arthritis with this type of disease; however, muscles are usually in better condition in adults. When only a few joints are in-

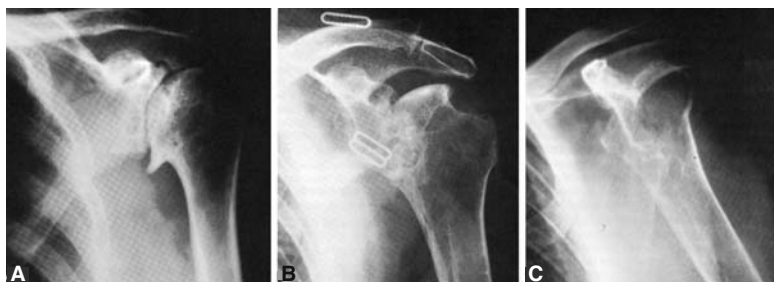


Fig. 63. Variations in involvement in rheumatoid arthritis. **A** Dry form with stiffness, sclerosis, and marginal osteophytes similar to those seen in osteoarthritis. **B** Wet form with inflammation and abundant marginal erosion of the articular surfaces by the destructive granulation. **C** End-stage bone destruction with complete loss of glenoid and head after years of involvement

involved, many terms have been used, which probably apply to this condition: “inflammatory osteoarthritis”, “low-grade rheumatoid arthritis,” and “mixed arthritis”.

In the **wet form** there are exuberant granulations with marginal erosion, which causes the ends of the bone to become pointed. Severe destruction of the glenoid may occur not only because of granulation erosion and disuse osteopenia but also because the pointed end of the humerus causes pressure erosion of the glenoid.

There is a **wet and resorptive form** of rheumatoid arthritis associated with severe bone loss and central migration of the humerus that Neer has termed “centralization”.

Centralization: severe loss of bone is associated with loss of the contour of the shoulder. The point of the shoulder becomes flattened and resembles a Burgundy wine bottle without the shoulders of a Bordeaux bottle, a finding that if looked far can easily be seen. This finding is significant in revealing marked bone loss and the probability of difficulty in implanting a glenoid component.

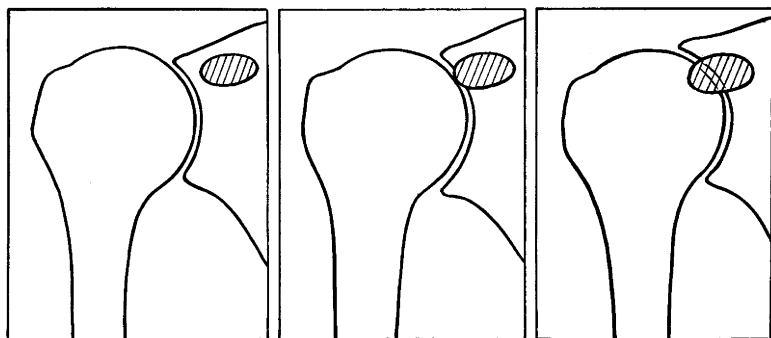


Fig. 64. Assessing glenoid wear in rheumatoid arthritis on true AP view: stage 1, subcondral bone intact or minimally deformed; stage 2, wear reaching the foot of the coracoid; and stage 3, wear beyond the foot of the coracoid

15.2 Staging of glenoid wear in rheumatoid arthritis according to Lévigne and Franceschi [76]*

Glenoid wear was graded as **stage 1** when the subcondral bone was intact or minimally deformed, as **stage 2** when the wear reached the foot of the coracoid and as **stage 3** when it went beyond the foot of the coracoid (Fig. 64).

15.3 Staging of humeral head wear in rheumatoid arthritis according to Lévigne and Franceschi [76]*

Wear of the humeral head was graded as **stage 1** when the subchondral bone was intact or had micro-geodes, as **stage 2** when the anatomical neck was deformed by a notch greater than 10 mm and as **stage 3** when the head had lost its spherical form (Fig. 65).

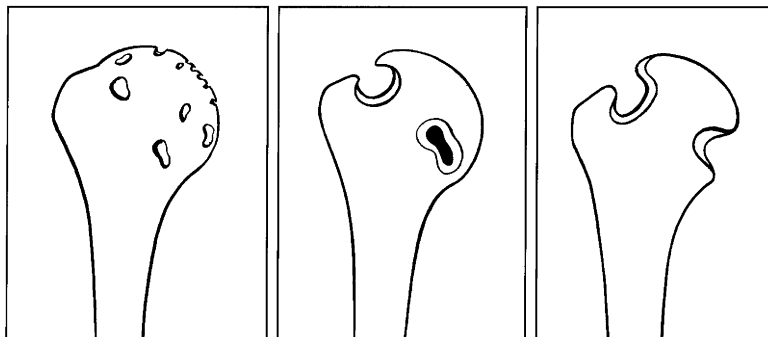


Fig. 65. Assessing humeral head wear in rheumatoid arthritis on true AP view: stage 1, microgeodes; stage 2, notch in the greater tuberosity; stage 3, loss of spherical form

15.4 Radiological classification of rheumatoid arthritis according to Lévigne and Franceschi [76]*

By examining the different preoperative radiographic appearances and particularly by analysing the radiographic history of the many patients followed regularly since their initial diagnosis, the authors were able to distinguish *three radiographic forms* as defined on two criteria: the sphericity of the humeral head and upward migration of the head in relation to the glenoid (Fig. 66).

- The **“ascending” form**. This was the most frequent occurring in 41% in their series. It is characterised by upward migration of the humeral head which precedes glenoid wear. The head retains its sphericity throughout the evolution. Narrowing of the joint space occurs at the superior pole of the glenoid followed by localised wear at this level, which progressively destroys the subchondral bone and gives the glenoid a sinusoidal appearance on the AP radiograph. The humeral head retains its sphericity but migrates upwards, inwards and backwards under the spine of the scapula. It ascends and medialises. At more evolved stage the surgical neck of the humerus comes into contact with the inferior border of the glenoid which leaves an imprint and creates the classical notch on the medial surface of the surgical neck (Fig. 66a).

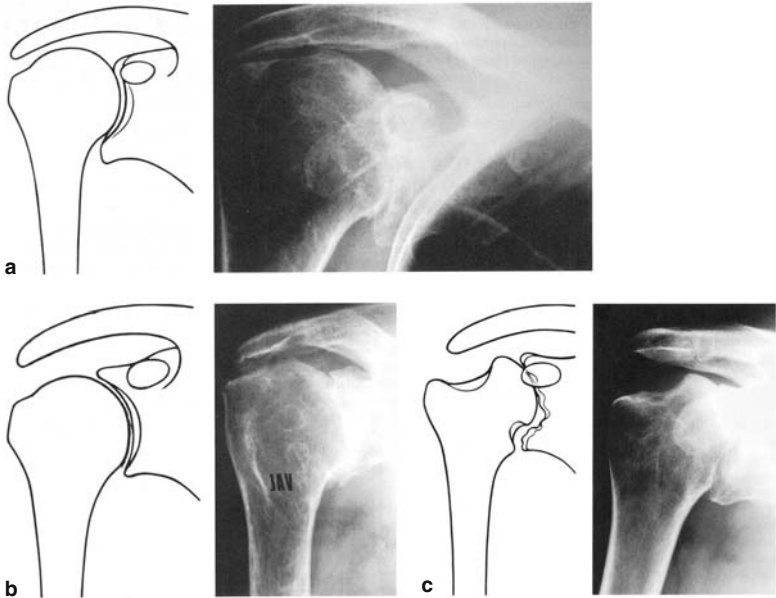


Fig. 66. Radiological classification of rheumatoid arthritis. **a** The ascending form of rheumatoid arthritis. **b** The centred form of rheumatoid arthritis. **c** The destructive form of rheumatoid arthritis. (From [76])

- The “**centred**” form. This was almost as frequent, occurring in 36% in their series. It is characterised by the absence of upward migration of the humeral head and a progress, uniform wear of the glenoid throughout its height. The humeral head retains its sphericity but pushes into the glenoid like an “egg into an egg-cup”. This form is reminiscent of the appearance seen in osteoarthritis and may be accompanied by marginal osteophytes at the superior and inferior poles of the glenoid. The progressive medialisation of the humeral head is followed in time by a reduction in the acromio-humeral distance (Fig. 66b).
- The “**destructive**” form. This is less frequent occurring in 19%. It is characterised by destruction of the humeral head which loses its sphericity. Wear occurs at the level of the anatomical neck producing a characteristic notch which progressively wears away at the circum-

ference of the neck to give it a “champagne cork” appearance. This very aggressive form of rheumatoid arthritis destroys the glenoid simultaneously. Some of the cases did not display a loss of joint space due to the articular incongruity (Fig. 66c).

15.5 Radiologic classification of rheumatoid arthritis according to Larsen, Dale, Eek [75]*

The system offers a possibility to reproduce radiographic evaluation of arthritis in the essential joints of the extremities. The reproducibility has been tested several times, with the general result that different observers uniformly graded 90% of films of rheumatoid arthritis. The validity of the radiographic criteria is based on the joint pathology. This system is not specific for rheumatoid arthritis. When new bone formation is not predominant it is possible to evaluate extremity joints in other chronic inflammatory conditions, such as ankylosing spondylitis and psoriatic arthropathy, which are known to present many common features in joint pathology. However, the system is not suited for evaluating juvenile rheumatoid arthritis or arthropathies in childhood with abnormal epiphyseal development. Osteoarthritis may cause abnormalities comparable with grade I, or even more severe grades, particularly in the interphalangeal joint of the finger (erosive, osteoarthritis), in the hips and in the knees. Osteoarthrosis is usually differential diagnosis without considering the clinical and laboratory data, as well as the result of radiography of the spine and sacroiliac joints.

The present system is a purely radiographic evaluation method for arthritis. It should not be considered as a general measure of the severity of the disease:

- **Grade 0.** *Normal conditions.* Abnormalities not related to arthritis, such as marginal bone deposition, may be present.
- **Grade I.** *Slight abnormality.* One or more of the following lesions are present: periarticular soft tissue swelling, periarticular osteoporosis and slight joint space narrowing. When possible, use for comparison a normal contralateral or a previous film of the joint in the same patient. Soft tissue swelling and osteoporosis may be reversible. This stage represents an early uncertain phase of arthritis or a later phase

without destruction. Compatible appearances may occur without arthritis in old age, traumatic conditions, Sudeck's atrophy etc.

- **Grade II. *Definite early abnormality.*** Erosion and joint space narrowing corresponding to the standards. Erosion is obligatory except in the weight-bearing joints.
- **Grade III. *Medium destructive abnormality.*** Erosion and joint space narrowing corresponding to the standards. Erosion is obligatory in all joints.
- **Grade IV. *Severe destructive abnormality.*** Erosion and joint space narrowing corresponding to the standards. Bone deformation is present in the weight-bearing joints.
- **Grade V. *Mutilating abnormality.*** The original articular surfaces have disappeared. Gross bone deformation is present in the weight-bearing joints. Dislocation and bony ankylosis, being late and secondary, should not be considered in the grading; if present, the grading should be made according to the concomitant bone destruction or deformation.

There may sometimes, especially in the erosive phase of arthritis, be some disparity between the degree of erosion and the narrowing of the joint space, because loosening of joint ligaments and the presence of excess joint fluid may cause widening of the joint space. If so, the degree of erosion should be the decisive factor when using the present grading system.

This system is recommended for the following purposes:

1. In diagnostic radiology for numerical evaluation of arthritis and for recording of spontaneous variations of the disease.
2. In therapeutic connections, for evaluating disease progression. The system is applicable both in trials of drugs and in synovectomy.
3. In epidemiology of arthritis for exact recording of lesions in individual joints.

16.1 Stages of joint infection according to Gächter [42] and Stutz et al. [125]

Septic arthritis can be divided into several stages arthroscopically:

- **Stage I:** opacity of fluid, redness of the synovial membrane, possible petechial bleeding, no radiological alterations.
- **Stage II:** severe inflammation, fibrinous deposition, pus, no radiological alterations.
- **Stage III:** thickening of the synovial membrane, compartment formation (“spongelike” arthroscopic view, especially in the suprapatellar pouch), no radiological alterations.
- **Stage IV:** aggressive pannus with infiltration of the cartilage, possibly undermining the cartilage, radiological signs of subchondral osteolysis, possible osseous erosions and cysts.

16.2 Proposed classification system of septic arthritis according to Tan et al. [126]

Part of the difficulty in reporting outcomes in infected shoulder patients is the lack of a uniform classification system for septic joints. A number of systems exist to describe osteomyelitis or infection around a total joint, but none are universally accepted. The ideal system will allow for stratification of the disease, improve decision making, and facilitate outcome reporting that is suitable for meaningful comparison. To our knowledge, a comprehensive classification system for septic arthritis of the shoulder, as such, does not exist at this time.

Therefore, we propose a new classification system for septic joints based on (a) the site and extent of tissue involvement; (b) the host’s status, systemically and locally; and (c) the duration of symptoms and

virulence of the organism. Clearly, all three of these factors must be considered when assessing treatment results and efficacy of treatment alternatives. In this system, the infectious process is staged using four anatomic types, three host physiologic classes, and two clinical settings.

- *Joint name* (glenohumeral, elbow, hip, knee, etc.)
- *Anatomic type*:
 - I: Periarticular soft-tissue infection without pyarthrosis
 - II: Isolated septic arthritis
 - III: Septic arthritis with soft-tissue extension, but no osteomyelitis
 - IV: Septic arthritis with contiguous osteomyelitis
- *Host class*:
 - A: Normal immune system
 - B: Compromised system
 - B_L: Local tissue compromise
 - B_S: Systemic immune compromise
 - C: Risk associated with aggressive treatment unwarranted
- *Clinical setting*
 - 1: Less than 5 days of symptoms and nonvirulent organism
 - 2: Symptoms for 5 days or more, or a virulent organism
- *Clinical stage for the septic joint*
 Anatomic type+host class+clinical setting=stage

The **anatomic types** include infection isolated to the periarticular soft tissue only, to the joint only, involvement of the joint and soft tissue, and involvement of the joint and bone. Anatomic type I is periarticular soft-tissue infection without pyarthrosis. Such a case may occur in a post surgical deep wound infection. Isolated glenohumeral sepsis (type II) occurs when the purulent material is confined within the capsule. Anatomic type III exists when there is involvement of the joint and surrounding soft tissue, such as deep wound infection or septic bursitis, along with the joint sepsis. There is no bony involvement in type III. When there is osteomyelitis contiguous with a joint infection, it is classified as type IV. In the shoulder girdle, this usually involves the proximal humerus but may occasionally develop in the acromion, distal clavicle, or glenoid.

The **host** is classified into either an A, H, or C physiologic group, according to the system of Cierny and Mader [20]. An A host represents a patient with normal metabolic and immune status. The B host is com-

promised either locally (B_L) or systemically (B_S). Local issues include retained nonabsorbable suture or other biomaterial, local irradiation, scarring from multiple procedures, and lymphedema. Systemic compromise includes extreme age, chronic disease, or any condition causing suppression of the immune system. The C host status is reserved for those patients in whom the risks associated with aggressive treatment would outweigh the negative aspects of the infection.

The **clinical setting** takes into account the duration of symptoms and aggressiveness of the organism. We have grouped patients with less than 5 days or symptoms and infection with a less virulent bacterial strain into group 1. Those patients who are infected with a virulent organism or with symptoms for 5 days or greater fall into group 2. The cut-off was chosen at 5 days because animal studies have shown that irreversible joint damage occurs if septic arthritis persists beyond this time. The virulent organisms may vary between hospitals and geographic locations but generally include methicillin-resistant *S. aureus*, gram-negative bacilli, vancomycin-resistant enterococcal species, and clostridia.

17.1 The system for the surgical staging of musculoskeletal sarcoma according to Enneking et al. [35, 138]

A surgical staging system for sarcoma should:

1. Incorporate the most significant prognostic factors into a system which describes progressive degrees of risk to which a patient is subject.
2. Delineate progressive stages of disease that have specific implications for surgical management.
3. Provide guidelines to the use of adjunctive therapies.

The staging system is based on the interrelationship of the grade (G), the site (T), and the presence or absence of metastases (M). Each of these is stratified further based on variable that affect prognosis and treatment.

Grade (G)

The grade of the tumour depends on three factors and is neither a purely histologic grade, as in the Broder system, nor a radiographic grade, as in the Lodwick system. It is best to conceptualize the grade as “clinical” or “surgical”, representing an assessment of the biologic aggressiveness of the lesion. Benign lesions are designated grade G₀, low-grade malignant neoplasms as G₁, and high-grade malignant neoplasms as G₂. In the MTS system, the histology is graded as either low grade or high grade. Some histologic grading systems include three or four levels of stratification; in these systems, poor interobserver agreement has been shown. For malignant neoplasms, generally, the surgical grade follows the histologic grade. A malignant neoplasm with a more benign cytologic appearance, however, may be considered high grade on its aggressive radiographic appearance and clinical behaviour.

Site (T)

The local extent of the neoplasm is determined by the staging studies. A T_0 lesion is confined within its capsule and remains within its compartment of origin. A T_1 lesion does not have a true limiting capsule, but has compressed the surrounding tissue into a pseudocapsule. Fingerlike projections or isolated nodules of tumour called *satellite lesions* are found in the reactive zone. Both the lesion and the reactive zone must be contained within the compartment of origin to be designated T_1 . A lesion outside the constraints of an anatomic compartment, by definition is extracompartmental (T_2). Direct spread may have occurred by obvious extension of the tumour mass or, more subtly, by the tumour's reactive zone lying outside the compartment of origin. An osteosarcoma of the distal femur that has destroyed the anterior cortex of the femur and has a soft-tissue component in the anterior thigh, for example, is considered T_2 . Likewise, a large soft-tissue sarcoma arising in the anterior compartment of the thigh with associated reactive changes in the adjacent femur on an isotope scan or MR image is considered T_2 . Because of the poor quality or lack of an effective barrier to tumour spread, there are sites in the body that, by definition are T_2 . Table 6 defines intracompartmental and extracompartmental sites as well as the means of extracompartmental extension.

Metastasis (M)

The final consideration in staging musculoskeletal neoplasms is the presence (M_1) or absence (M_0) of metastases. A malignant tumour with metastases at the time of presentation is designated M_1 . In the MTS system, a lesion with regional lymph node metastases is included as a M_1 lesion because it carries a poor prognosis similar to that when distant metastases are present. Generally, musculoskeletal sarcomas metastasize hematogenously, with the lungs as the most common site, followed by the skeleton. Only a few types of sarcomas, including rhabdomyosarcoma, epitheloid sarcoma, and synovial cell sarcoma, have a significant incidence of regional lymph node metastasis. A lesion with "skip" metastases also is included as a M_1 lesion, carrying a similarly poor prognosis. The grade (G), site (T), and presence of metastases (M) determine the assignment in the surgical staging system. Table 7 shows the application for benign lesions and Table 8, the application for malignant

Table 6. Surgical sites (T)

Intracompartmental (T ₁)	Extracompartmental (T ₂)
Intraosseous	Soft tissue extension
Intraarticular	Soft tissue extension
Superficial to deep fascia	Deep fascial extension
Paraosseous	Intraosseous or extrafascial
Intrafascial compartments	Extrafascial planes or spaces
Ray of hand or foot	Mid and hind foot
Posterior calf	Popliteal space
Anterolateral leg	Groin-femoral triangle
Anterior thigh	Intrapelvic
Medial thigh	Midhand
Posterior thigh	Antecubital fossae
Buttocks	Axilla
Volar forearm	Periclavicular
Dorsal forearm	Paraspinal
Anterior arm	Head and neck
Posterior arm	
Periscapular	

Table 7. Staging of benign lesions

Stage	Description	Grade	Site	Metastases
1	Latent	G ₀	T ₀	M ₀
2	Active	G ₀	T ₀	M ₀
3	Aggressive	G ₀	T ₁₋₂	M ₀₋₁

lesions. The radiographic appearance and clinical behaviour stratify benign lesions as latent (stage 1), active (stage 2), or aggressive (stage 3). All benign lesions are surgical grade G₀. Malignant lesions are designated as low-grade (stage I), high-grade (stage II), or metastatic (stage III). The letter A or B is added to stage I or stage II lesions to indicate intracompartmental (A) or extracompartmental (B). Regardless the grade or site, malignant tumours with metastases are stage III.

Table 8. Staging of malignant lesions

Stage	Description	Grade	Site	Metastases
IA	Low-grade, intracompartmental	G ₁	T ₁	M ₀
IB	Low-grade, extracompartmental	G ₁	T ₂	M ₀
IIA	High-grade, intracompartmental	G ₂	T ₁	M ₀
IIB	High-grade, extracompartmental	G ₂	T ₂	M ₀
III	Any grade, metastatic	G ₁₋₂	T ₁₋₂	M ₁

Stage 1, latent benign (G₀, T₀, M₀)

Clinically, these lesions are asymptomatic and are often discovered incidentally. They seldom are associated with a pathologic fracture and rarely, if ever, cause any dysfunction. When located in the soft tissue, lesions are usually small, nontender, and freely moveable. When in bone, there seldom is cortical deformation. Latent benign lesions may enlarge slowly and respond biologically to normal inhibitors of growth.

In bone, stage 1 lesions usually have a well demarcated geographic pattern. They are well margined and often have a rim of cortical-like reactive bone surrounding them (Lodwick IA). CT reveals homogeneity without cortical breaching or extrafascial extension.

Histologically, the matrix appears mature and well differentiated, with a low cell-to-matrix ratio. Malignant cytologic indicators, such as hyperchromism, anaplasia, pleomorphism, or mitoses, are absent. The lesions are well encapsulated by mature fibrous tissue or cortical bone, with little reactive mesenchymal proliferation, inflammatory response, or angiogenesis.

Stage 2, active benign (G₀, T₀, M₀)

The majority of benign lesions that present for medical attention are active benign. These lesions tend to grow steadily and may be symptomatic. They react to normal contact inhibitors but not at normal levels. Active benign lesions tend to be small and movable when in soft tissue but, in contrast to stage 1 lesions, may be tender.

Radiographs of active benign lesions demonstrate good margination but with some irregular borders. When in bone, stage 2 lesions usually are surrounded by a rim of reactive bone with a more cancellous ap-

pearance. The inner aspect of the cortex may be septated and the overlying cortex may be deformed (Lodwick IB). An isotope scan will show increased uptake that closely conforms to the limits of the lesion as perceived on conventional radiographs. CT and MRI show the lesions to be homogeneous with an irregular but intact reactive rim and may show deformation of the cortex. CT and MR images demonstrate the lesions remain intracompartmental.

Histologically, active benign lesions have a balanced cell-to-matrix ratio. The matrix is well differentiated and evenly distributed. The cytologic appearance is benign. There may be a surrounding narrow zone of reactive fibrovascular infiltrate. Resorption of bone is osteoclastic rather than by the tumour cells.

Stage 3, aggressive benign (G_0 , T_{1-2} , M_{0-1})

Aggressive benign lesions generally are symptomatic. They are brought to attention by discomfort and usually are quite tender. They may even be associated with a pathologic fracture when the bone is subjected to moderate trauma. Their growth rate is rapid and appears to have little inhibition by growth-limiting factors. Aggressive benign lesions occasionally have an inflammatorylike appearance with surrounding erythema and induration. Conventional radiographs show the lesions to be quite aggressive – even more so than some low-grade malignancies. The interface with the normal adjacent bone is ragged and permeative. Reactive bone and Codman's triangles may be present. Cortical destruction is evident. Isotope scans show increased uptake well beyond the expected limits of the lesions based on plain radiographs. CT and MR images demonstrate the lesions to be nonhomogenous. Early extracompartmental extension is common.

Histologically, aggressive benign lesions are characterized by a well-differentiated matrix in various stages of maturity. The cell-to-matrix ratio generally is high and there may be hyperchromatic nuclei, but other cytologic features of malignancy, such as anaplasia and pleomorphism, are absent. Mitoses may be present. Microscopic or macroscopic foci of the lesion extending through the pseudocapsule (“satellite”) lesions can be demonstrated.

Stage IA, low-grade malignant, intracompartmental (G₁, T₁, M₀)

Low-grade neoplasms usually are slow-growing, painless, and asymptomatic. Because of their indolent behaviour, the malignant potential often is not recognized. Low-grade malignant neoplasms have all the invasive properties of a high-grade lesion but, because the lesions enlarge slowly, they tend to cross compartmental boundaries slowly rather than destroy them rapidly. In soft tissues, stage I lesions often are superficial, nontender, and have few surrounding inflammatory signs. The tumours' large size and their adherence to the surrounding tissue hint at their true malignant nature. On conventional radiographs, in addition to having a cancellous-like rim of reactive bone, features of a malignancy, such as endosteal scalloping or Codman's triangles, are seen. Isotope scans show an area of uptake larger than expected but within the compartment of origin. CT and MR images verify the intracompartmental location. The matrix usually is mature and well differentiated. The cell-to-matrix ratio is approximately one-to-one. The lesions show definite cytologic signs of malignancy, including anaplasia and pleomorphism (Broder's grade 1 and, occasionally, 2). There is a surrounding pseudocapsule composed of compressed reactive tissue that contains microscopic foci of tumour ("satellite" lesions).

Stage IB, low-grade malignant, extracompartmental (G₁, T₂, M₀)

The clinical findings of extracompartmental low-grade malignant tumours are similar to those of intracompartmental low-grade malignant tumours. Low-grade lesions may become extracompartmental by direct spread, not responding to the normal inhibitors of tumour growth. An adamantinoma arising in the tibia that violates the anterior cortex and enters the anterior compartment of the lower leg, for example, would be considered stage IB. Because of the inherent lack of effective barriers to tumour spread, the anatomic location may define the lesions as extracompartmental – i.e., the popliteal fossa. Previous surgery contaminates multiple compartments, rendering previously intracompartmental low-grade malignant neoplasms extracompartmental. Radiographic staging studies identify the extracompartmental spread or anatomic location of the primary lesion.

Stage IIA, high-grade malignant, intracompartmental (G_2 , T_1 , M_0)

High-grade malignant neoplasms are symptomatic. They almost always are painful and come to attention because of discomfort. High-grade lesions grow rapidly and appear to have no biologic constraints to growth. Only high-grade malignant lesions discovered very early in their course are intracompartmental. High-grade tumours are invasive and quickly extend through the host's natural barriers to tumour spread. They generally are located deep to the fascia and are fixed to surrounding tissues.

High-grade lesions are poorly margined on conventional radiographs (Lodwick III). The extent of the borders often is difficult to visualize. Occasionally, matrix formation may give an important clue as to the histogenesis of the lesion. Isotope scans typically show increased uptake in an area much greater than expected based on plain films. The reactive zone must be within the compartment of origin for the tumour to be classified as intracompartmental.

Histologically, lesions have all the characteristics of high-grade malignancies (Broder's grade 2, 3, and 4). They have hyperchromatic nuclei with frequent mitoses. The cells are anaplastic and pleomorphic. The cell-to-matrix ratio is high. Vascular invasion, necrosis, and haemorrhage often are present. There is direct destruction of normal tissue by the tumour cells. There is little or no encapsulation.

Stage IIB, high-grade malignant, extracompartmental (G_2 , T_2 , M_0)

Most high-grade malignant sarcomas present as stage IIB. High-grade lesions are aggressive and quickly extend beyond their compartment of origin. Occasionally, the patient presents with a pathologic fracture.

Radiologically, bone lesions are characterized by cortical destruction and early soft-tissue extension. The periosteal reaction often is obliterated by the rapid growth and destruction of the tumour. Isotope scans show reactive zone to extend beyond the compartment of origin. MR images and CT confirm the extracompartmental spread of high-grade neoplasms. Just as in low-grade lesions, high-grade neoplasms may be extracompartmental by virtue of their anatomic location or previous surgical intervention. Histologically, stage IIB lesions resemble stage IIA lesions, with all of the characteristics of high-grade malignancies.

Stage III, metastatic

Malignant neoplasms that present with metastases are stage III. Stage III lesions may be high grade or low grade, extracompartmental or intracompartmental. The clinical behaviour and histologic appearance of the primary lesions are similar to corresponding lesions without metastases. Staging studies usually reveal the sites of metastases. CT of the chest may reveal pulmonary metastases. Isotope scans may show distant or skip metastases. MR imaging in the longitudinal plane may demonstrate skip metastases may be discovered on physical examination.

18.1 Radiographic assessment of radiolucent lines of the humeral component according to Sperling et al. [124]

Components were divided into radiographic zones for measurement of periprosthetic lucency; the humerus had 8 zones (Fig. 67). The lines were evaluated according to their presence or absence, location, and thickness. The maximum thickness of the lines was measured to within 0.5 mm.

To combine the data on lucent lines, their extent and thickness, and the data on shift and component position, the authors selected a set of changes that orthopaedic surgeons would, in their opinion, agree were worrisome for component loosening and could be associated with clini-

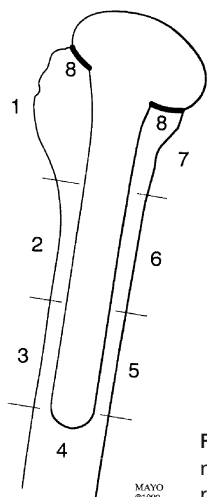


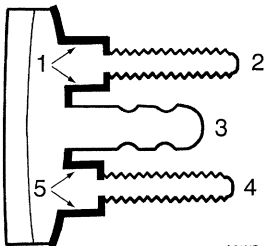
Fig. 67. Assessment of radiolucent lines of the humeral component. Humeral component-bone interface is divided into eight radiographic zones. (From [124])

cal problems. The authors designated these combinations as representing components radiographically “at risk” for clinically symptomatic component loosening. A humeral component was defined to be “at risk” if at least two of three observers identified tilt or subsidence of the component or if a lucent line 2 mm or greater in width was present in three or more zones.

18.2 Radiographic assessment of radiolucent lines of the glenoid component according to Sperling et al. [124]

Components were divided into radiographic zones for measurement of periprosthetic lucency; the glenoid had 5 zones (Fig. 68). The lines were evaluated according to their presence or absence, location, and thickness. The maximum thickness of the lines was measured to within 0.5 mm.

To combine the data on lucent lines, their extent and thickness, and the data on shift and component position, the authors selected a set of changes that orthopaedic surgeons would, in their opinion, agree were worrisome for component loosening and could be associated with clinical problems. The authors designated these combinations as representing components radiographically “at risk” for clinically symptomatic component loosening. A glenoid component was defined to be “at risk” if at least two of three independent observers identified migration or tilt of the component or if a complete lucent line was present and some part of it was 1.5 mm or greater in width.



MAYO
©1999

Fig. 68. Assessment of radiolucent lines of the glenoid component. Glenoid component-bone interface is divided into five radiographic zones. (From [124])

18.3 Radiographic assessment of radiolucent lines of the cemented glenoid component according to Molé et al. [86]

The position of the radiolucent lines was established using the six zones (Fig. 69) corresponding to numbers 1, 5 and 6 for the upper, lower and middle parts of the tray and to zones 2, 3 and 4 around the periphery of the keel. Their thickness was measured in three grades;

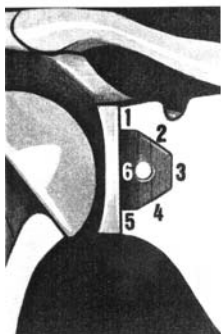
Grade 1 = less than 1 mm

Grade 2 = between 1 and 2 mm

Grade 3 = greater than 2 mm.

The authors also calculated the **radiolucent line score (RLL score)** using the six zones and three grades for each patient. This is the sum of each zone involved multiplied by its grade giving a maximum of 18 (Fig. 69). The component is arbitrarily considered as being loose if the score is greater than 12.

The radiolucent lines were considered to be progressive when the RLL score increased with time, whether this was due to an increased number of zones becoming affected or an increase in the thickness of the existing lines or both.



POINTS ZONES	< 1 mm (1 point)	1-2 mm (2 points)	> 2 mm (3 points)	RLL SCORE (18 points)
1		x		2
2	x			1
3	x			1
4	x			1
5		x		2
6		x		2

Total = 9/18

Fig. 69. Assessment of radiolucent lines of cemented glenoid components. Position of the six zones for measuring lucent lines and example of evaluation of the radiolucent line (RLL) score (score=9/18 in this case). (From [86])

18.4 Radiographic assessment of radiolucent lines of the glenoid component according to Franklin et al. [40]

- Class 0: no lucency
- Class 1: lucency at the superior and/or inferior flange only
- Class 2: incomplete lucency at the keel
- Class 3: complete lucency of up to 2 mm around the component
- Class 4: complete lucency greater than 2 mm around the component
- Class 5a: component translated (e.g., tipped or shifted)
- Class 5b: component dislocated from the bone

18.5 Radiographic assessment of radiolucent lines of the cemented glenoid component according to Wilde et al. [136]

An evaluation was made of the thickness of the radiolucent zone at the bone-cement interface around the glenoid component. The bone-cement interface of the glenoid component, for purposes of evaluation, was divided into three zones (Fig. 70) Zone 1 comprised the interface between the subchondral bone of the glenoid and the collar of the prosthesis. The stem of the prosthesis was divided into two equal positions representing Zones 2 and 3.

Zone 1 includes the area between the shoulder of the glenoid component and the glenoid itself. It would not be surprising that a radiolucent zone would appear in the area as the hard subchondral surface does not permit interdigitation with the cement.

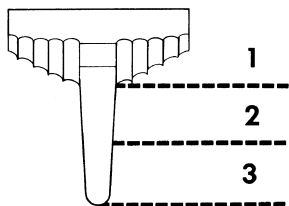


Fig. 70. Assessment of radiolucent lines of cemented glenoid components. (From [136])

18.6 Classification of bone defects of the scapular notch for inverse shoulder arthroplasty according to Sirveaux [120]

The scapular notch, which is a defect of the bone in the inferior part of the glenoid component, was noted and was classified according to the size of the defect as seen on the radiograph (Fig. 71). A defect which was confined to the pillar corresponded to **grade 1**. It was considered to be **grade 2** when it was in contact with the lower screw, **grade 3** when it was over the lower screw and **grade 4** when it extended under the baseplate.

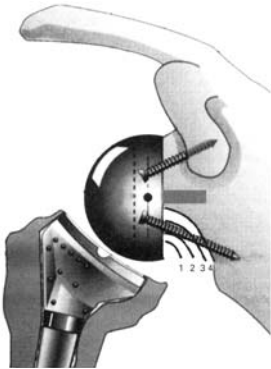


Fig. 71. Classification of bone deflection of the scapular notch in patients with inverse shoulder arthroplasty. (From [120])

18.7 Classification of glenoid bone deficiencies after glenoid component removal according to Antuna et al. [3]

Glenoid bone loss was categorized intraoperatively on the basis of location and severity (Fig. 72). Based on the location, the *defects* were categorized as **central**, **peripheral** (anterior or posterior), or **combined** (central and peripheral) deficiencies. Based on the severity, *deficiencies* were classified as **mild** if they involved less than one third of the glenoid rim or surface, **moderate** if they involved between one third and two thirds, and **severe** if they involved more than two thirds.

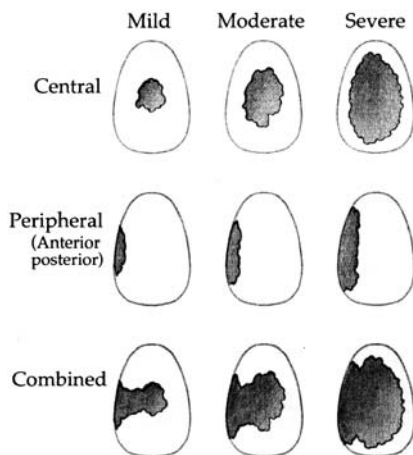


Fig. 72. Classification of glenoid bone deficiencies after glenoid-component removal. Mild and moderate deficiencies are often suitable for component reimplantation with or without bone grafting of glenoid. Severe central or combined deficiencies often preclude implantation of new component

18.8 Classification of heterotopic bone formation following total shoulder arthroplasty according to Kjaersgaard-Andersen et al. [71]*

Heterotopic bone was graded according to the filling of space between the lateral border of the glenoid and the medial border of the humeral shaft and/or the inferior border of the acromion:

- **grade 0**, no ossification;
- **grade I**, ossification occupying less than 50% of the space (Fig. 73 a)
- **grade II**, ossifications occupying more than 50% of the space but no roentgenographic bridge (Fig. 73 b); and
- **grade III**, ossifications roentgenographically bridging the space (Fig. 73 c).

Finally, the location of the heterotopic bone formation was recorded as proximal or distal to the head of the humeral component.

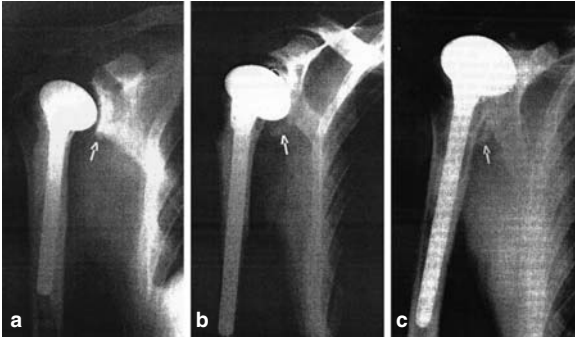


Fig. 73. Classification of heterotopic bone formation following total shoulder arthroplasty. (From [71]). **a** Grade-I heterotopic bone formation in the glenohumeral space (*arrow*). **b** Grade-II heterotopic bone formation in the glenohumeral space (*arrow*). This ossification probably is in the joint capsule. **c** Grade-III heterotopic bone formation bridging the glenohumeral space (*arrow*)

19.1 Constant-Murley score [23]*

In the Constant and Murley method of functional assessment, a hundred-point score is based on the assessment of a number of individual subjective and objective parameters in an entirely clinical setting (Table 9).

The authors consider a hundred-point scoring system, combined with the ability to assess individual parameters with numerical values, to be the best method of functional assessment of the shoulder. The parameters are chosen for their functional relevance. The first subjective parameter assesses the most severe degree of pain experienced during activities of normal daily living (Table 10). Absence of pain scores 15, whilst the presence of severe pain scores zero.

The other subjective parameter assessed is the ability of the individual to carry out daily activities in relation to work, recreation, and ability to sleep (Table 11). The ability of the patient to perform everyday activities in terms of the position of the arm in relation to the trunk is also evaluated. Twenty points may be allocated for activities of daily living, as shown in Table 11. Ten points are based on the patient's subjective answers regarding ability to perform normal work and recreation and to sleep well. Four of the points are allocated to work, four to recreational

Table 9. Scoring for individual parameters

Parameter	Score
Pain	15
Activities of daily living	20
Range of motion	40
Power	25
Total	100

Table 10. Scoring for pain experienced during normal daily activity

Pain experienced	Score
None	15
Mild	10
Moderate	5
Severe	0

Table 11. Scoring for activities of daily living

Activity	Score
Activity level	
Full work	4
Full recreation/sport	4
Unaffected sleep	2
Positioning	
Up to waist	2
Up to xiphoid	4
Up to neck	6
Up to top of head	8
Above head	10
Total	20^a

^a Only one of the five positions is found in each patient. The maximum points attainable by a normal individual in this section can only be 20

activities outside work and two to unaffected sleep. The patient is asked to say what percentage of work and recreation has to be abolished as a result of the shoulder problems. Unaffected sleep score two points and gross disturbance scores zero. One must be sure that sleep disturbance is caused by the shoulder and not by other problems, before reducing the allocated points.

The other 10 points allocated to activities of daily living are given for the ability to perform tasks at a variety of levels, ranging from below waist to above head level. This is not the assessment of pure motion; it is the assessment of the ability of the hand to work at the levels described. Thus, it combines forward elevation with slight rotation, and

the ability to hold the shoulder in particular positions while activities are being performed. Since the shoulder at rest will allow below-waist activities to be undertaken without much shoulder function, such activities get only 2 points. Increasing point for activities above the level are allocated as shown in Table 11.

The objective assessment rates the patient on painless active motion in the planes of pure forward and lateral elevation (Table 12), as well as composite functional external and internal rotation (Tables 13 and 14). Finally the shoulder power is included in the assessment, and is measured as abduction power at 90° (or less if the patient is unable to abduction to that level). Power is tested using the method described by Moseley [89]. He used a tensiometer to measure isometric power of the shoulder at 90° of lateral elevation. The authors' method is to use a spring balance to test power of shoulder abduction at 90° , in pounds. In patients whose active range of abduction is less than 90° , the power at whatever maximum active abduction can be performed is taken using

Table 12. Points awarded for forward and lateral elevation

Elevation ($^\circ$)	Points
0–30	0
31–60	2
61–90	4
91–120	6
121–150	8
151–180	10

Table 13. External rotation scoring

Position	Points
Hand behind head with elbow held forward	2
Hand behind head with elbow held back	2
Hand on top of head with elbow held forward	2
Hand on top of head with elbow held back	2
Full elevation from on top of head	2
Total	10

Table 14. Internal rotation scoring

Position	Points
Dorsum of hand to lateral thigh	0
Dorsum of hand to buttock	2
Dorsum of hand to lumbosacral junction	4
Dorsum of hand to waist (third lumbar vertebra)	6
Dorsum of hand to 12th dorsal vertebra	8
Dorsum of hand to interscapular region (DV 7)	10

the spring balance in the way already described. Although this method of estimating shoulder power is not as exact as that obtained with the Cybex II, it gives a reasonable reflection of shoulder power, compared with the more sophisticated methods described. It appears that graphic representation of isokinetic power to 90° abduction, as reported by Wallace et al. [135] would parallel results of isometric power measurements obtained by the method described here.

A normal shoulder in a 25-year-old man resists 25 pounds without difficulty. The score given for normal power is 25 points, with proportionately less for less power. The spring balance can have handles attached to make the procedure easier for the patient, especially for those with rheumatoid deformities of the hands. The power of the normal shoulder, as measured by this method, diminishes with advancing age.

The complete shoulder functional assessment form as used by the author is shown in Table 15.

19.1.1 Normative age- and sex-specific Constant Score according to Gerber et al. [141]

Yian et al. [141] report normative age- and sex-specific Constant Score and strength values, by use of the Isobex device, in a large population (n=1620) sample (Table 16).

Using Constant's original normal values for the calculation of the relative Constant score can overestimate shoulder function in women aged over 40 years and men aged over 60 years.

Table 15. Shoulder functional assessment

Pain	Score	
	Right	Left
Activities of daily living	15	15
Work	4	4
Recreation	4	4
Sleep	2	2
Position	10	10
Range		
Abduction	10	10
Flexion	10	10
Internal rotation	10	10
External rotation	10	10
Power	25	25
Total	100	100

Table 16. Normative age- and gender-related Constant score. (From [141])

Age (years)	Constant score	
	Male	Female
21–30	94	86
31–40	94	86
41–50	93	85
51–60	91	83
61–70	90	82
71–80	86	81

Different population norms may need to be established and absolute Constant scores should accompany relative Constant scores to allow future comparisons with other populations.

19.1.2 Normative age- and gender-related Constant Score according to Katolik et al. [67]

The utilization of normal data (Table 17) from a large (n=441) metropolitan population without shoulder symptoms to generate adjusted age- and gender-matched Constant scores should serve as an excellent basis for the reporting and comparison of outcomes data, to facilitate communication between investigators and to permit and encourage multi-member studies.

Table 17. Normative age- and gender-related Constant score. (From [67])

Age (years)	Constant score	
	Male	Female
18–29	95	88
30–39	95	87
40–49	96	86
50–59	94	84
60–69	92	83
≥70	88	81

19.1.3 Valuation of the Constant Score according to Boehm [12]

The valuation of the Constant Score on the basis of the age- and gender-related Constant Score is shown in Table 18.

Table 18. Valuation of the age- and gender-related Constant score

Valuation	Constant score (%)
Excellent	91–100
Good	81–90
Satisfactory	71–80
Adequate	61–70
Poor	< 60

19.2 Questionnaire based on the Constant-Murley Score for patient self-evaluation of shoulder function according to Boehm [13]*

The aim was to develop a German questionnaire for self-assessment of shoulder function equivalent to the Constant Score (CS) (see Fig. 74). To evaluate the retest reliability, the CS questionnaire was completed twice within 1 week by 47 patients prior to shoulder surgery. For validation the CS was assessed by the physician after the second self-test. The medium selectivity of the CS questionnaire at hospital admission was 0.47, the medium item difficulty 0.40, the test-retest reliability 0.675 ($p=0.000$), the internal consistency of the questionnaire 0.80, and of the physician's CS evaluation 0.85. Construct, content, and discriminative validity of the questionnaire could be demonstrated. A high correlation of the patient-based questionnaire with the physician-assessed CS was found ($p=0.82$). The statistical analyses demonstrated that the CS questionnaire is a reliable and valid instrument to evaluate the CS and can therefore be used for follow-up studies.

The subjective experienced pain will be documented using a visual analog scale range from zero to 15, whereas absence of pain scores 15 and presence of severe pain scores zero.

The categories of activities of daily living and range of motion were evaluated equivalent to the Constant-Murley Score. The authors performed an analysis of patients' power for the calculation of a conversion factor from self-assessment to mechanical testing by an examiner. In the questionnaire the patient is asked to fill a paper-bag with Tetra-Paks, to hang this filled paper-bag at the wrist and hold it for 5 seconds at 90° abduction. Twenty-five points should be achieved for this category, so that the relation between the measured power using a spring scale for power measurement and the self-assessment using the Tetra-Paks method was defined by performing a cross-over analysis of power. The evaluated conversion factor is 2.20. The allocation of points for the measurement of power is shown in Table 19.

Patient data

Code:	Datum:
-------	--------

Please mark with a cross:

Affected shoulder (resp. treated shoulder):

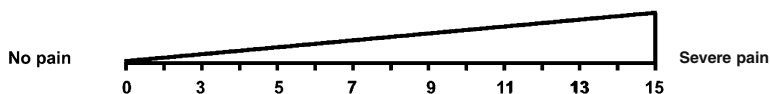
right left

Are you right dominant or left dominant ?


I. Pain

Please mark with a cross the average intensity of pain of both shoulders during last week:

Right shoulder



Left shoulder



Constant Score Patient – Universität Würzburg – Orthopädische Klinik König-Ludwig-Haus

Fig. 74. Questionnaire based on the Constant-Murley Score for patient self-evaluation of shoulder function according to Boehm [13]

II. Profession: Please mark with a cross, for both shoulders, if you have pain or you have been limited using your arm for occupational activity. (If you are not employed, please indicate for main activity of daily living)

	Right shoulder	Left shoulder
a. no limitation	<input type="checkbox"/>	<input type="checkbox"/>
b. less than reduced to the half	<input type="checkbox"/>	<input type="checkbox"/>
c. reduced to the half	<input type="checkbox"/>	<input type="checkbox"/>
d. more than reduced to the half	<input type="checkbox"/>	<input type="checkbox"/>
e. completely reduced	<input type="checkbox"/>	<input type="checkbox"/>

III. Leisure Please mark with a cross, for both shoulders, if you have pain or have been limited in recreational activities (Hobby, Sports, Garden etc.)

	Right shoulder	Left shoulder
a. no limitation	<input type="checkbox"/>	<input type="checkbox"/>
b. less than reduced to the half	<input type="checkbox"/>	<input type="checkbox"/>
c. reduced to the half	<input type="checkbox"/>	<input type="checkbox"/>
d. more than reduced to the half	<input type="checkbox"/>	<input type="checkbox"/>
e. completely reduced	<input type="checkbox"/>	<input type="checkbox"/>

IV. Working height Please mark with a cross up to which height you are able to perform pain free or without limitation. Activities (i.e. hang up laundry) are able up to and including...

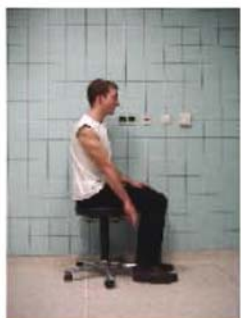	Right shoulder	Left shoulder
a. belt height	<input type="checkbox"/>	<input type="checkbox"/>
b. chest height	<input type="checkbox"/>	<input type="checkbox"/>
c. neck height	<input type="checkbox"/>	<input type="checkbox"/>
d. up to the top of head	<input type="checkbox"/>	<input type="checkbox"/>
e. above head	<input type="checkbox"/>	<input type="checkbox"/>

V. Sleep Please mark with a cross, if your sleep is disturbed by shoulder pain

	Right shoulder	Left shoulder
a. not disturbed	<input type="checkbox"/>	<input type="checkbox"/>
b. wake up occasionally	<input type="checkbox"/>	<input type="checkbox"/>
c. wake up continuously	<input type="checkbox"/>	<input type="checkbox"/>

Please mark with a cross for each image and both shoulders, if you are able to perform the movement painfree

VI. Pain free forward elevation of the arm



0 - 30

 right left

31 - 60

 right left

61 - 90

 right left

91 - 100

 right left

121 - 150

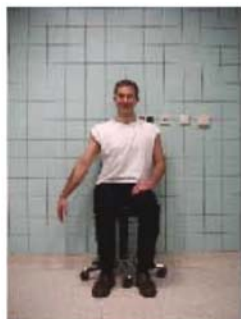 right left

>150

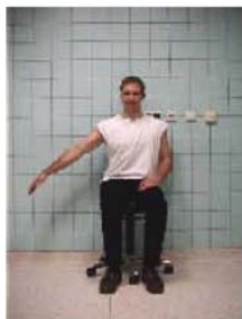 right left

Fig. 74 (continued)

VII. Pain free lateral elevation of the arm



0 - 30

 right left

31 - 60

 right left

61 - 90

 right left

91 -100

 right left

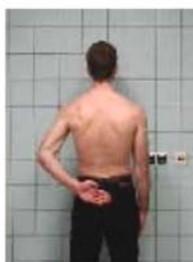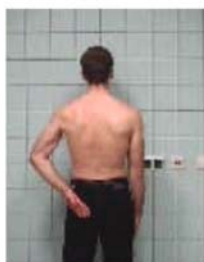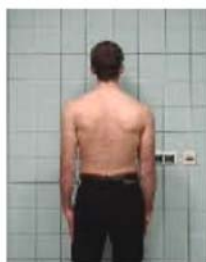121 -150

 right left

>150

 right left

VII. Pain free internal rotation behind the body



**Up to the origin
of the pocket**

**Up to under
the belt**

right

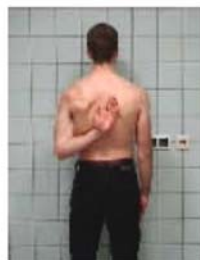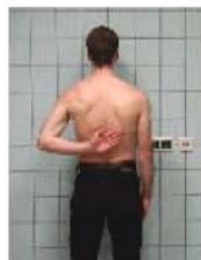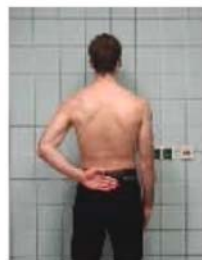right

right

left

left

left



belt

Above belt

**between the
scapulae**

right

right

right

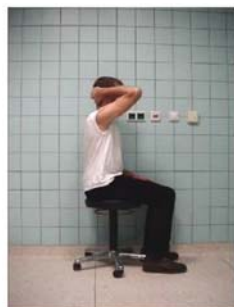left

left

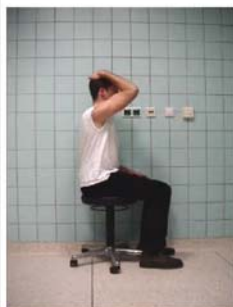left

Fig. 74 (continued)

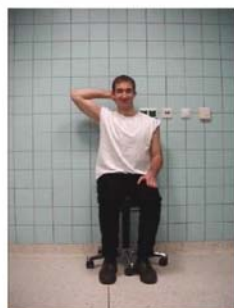IX. Pain free external rotation

 right left

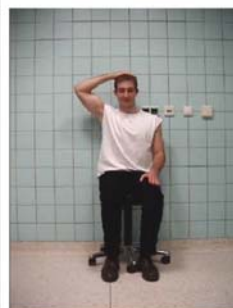Hand at the
neck with
elbow held
forward

 right left

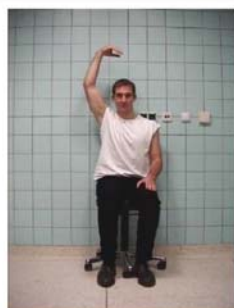Hand on top
of the head
with elbow
held forward

 right left

Hand at the
neck with
elbow held
back

 right left

Hand on top
of the head
with elbow
held back

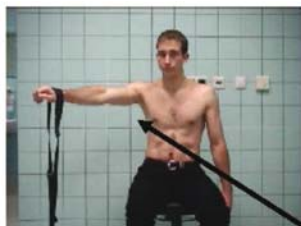 right left

Hand above
head

No painless movement
possible!

 right left

X. Measurement of power. Please fill a paper-bag with 1 L Tetra-Packs and keep this in the below-mentioned position for 5 seconds. Please indicate how much kg you are able to keep.



Arm positioned in 90° abduction to the body and slightly in front of the body

Right:
weight: ____ kg

left:
weight: ____ kg

Notes:

THANK YOU!

Constant Score Patient – Universität Würzburg – Orthopädische Klinik König-Ludwig-Haus

This document was created with Win2PDF available at <http://www.danepairie.com>. The unregistered version of Win2PDF is for evaluation or non-commercial use only.

Fig. 74 (continued)

Table 19. Allocation of points for the measurement of power using Tetra-Paks

No. of Tetra-Paks	Points	No. of Tetra-Paks	Points
0	0	7	15
1	2	8	18
2	4	9	20
3	7	10	22
4	9	11	24
5	11	12	25
6	13	>12	25

19.3 UCLA shoulder rating [2]

Occasionally, analysis of pain, function and range of motion does not fit exactly the numerical criteria indicated, and the interval numbers provide flexibility for “in-between” indications.

In general, the authors consider a >8 result for pain, function and range of motion to be excellent, >6 good, >4 fair, and <3 poor (Table 20).

Table 20. UCLA shoulder rating

Parameter	Score	Finding
Pain	1	Constant, unbearable; strong medication frequently
	2	Constant, but bearable; strong medication occasionally
	4	None or little at rest; occurs with light activities; salicylates frequently
	5	With heavy or particular activities only; salicylates occasionally
	8	Occasional and slight
	10	No pain
Function	1	Unable to use arm
	2	Very light activities only
	4	Light housework or most daily living activities
	5	Most housework, washing hair, putting on brassiere, shopping, driving
	8	Slight restriction only; able to work above shoulder level
	10	Normal activities
Muscle power and motion	1	Ankylosis with deformity
	2	Ankylosis with good functional position
	4	Muscle power poor to fair; elevation $<60^\circ$, internal rotation $<45^\circ$
	5	Muscle power fair to good: elevation 90° , internal rotation 90°
	8	Muscle power good or normal; elevation 140° , external rotation 20°
	10	Normal muscle power; motion near normal

19.4 DASH (Disabilities of the Arm, Shoulder and Hand) Questionnaire [60] © *

The goal was to produce a brief, self-administered measure of symptoms and functional status, with a focus on physical function, to be used by clinicians in daily practice and as a research tool. This is a joint initiative of the American Academy of Orthopedic Surgeons (AAOS), the Council of Musculoskeletal Specialty Societies (COMSS), and the Institute for Work and Health (Toronto, Ontario).

The approach is consistent with previously described strategies for scale development. In Stage 1, Item Generation, a group of methodologists and clinical experts reviewed 13 outcome measurement scales currently in use and generated a list of 821 items. In Stage 2a, Initial Item Reduction, these 821 items were reduced to 78 items using various strategies including removal of items which were generic, repetitive, not reflective of disability, or not relevant to the upper extremity or the one of the targeted concepts of symptoms and functional status. Items not highly endorsed in a survey of content experts were also eliminated. Stage 2b, Further Item Reduction, will be based on results of field testing in which patients complete the 78-item questionnaire. This field testing, which is currently underway in 20 centres in the United States, Canada, and Australia, will generate the final format and content of the Disabilities of the Arm, Shoulder, and Hand (DASH) questionnaire.

The DASH Outcome Measure (Fig. 75) is a 30-item, self-report questionnaire designed to measure physical function and symptoms in people with any of several musculoskeletal disorders of the upper limb. The tool gives clinicians and researchers the advantage of having a single, reliable instrument that can be used to assess any or all joints in the upper extremity.

DISABILITIES OF THE ARM, SHOULDER AND HAND

Please rate your ability to do the following activities in the last week by circling the number below the appropriate response.

	NO DIFFICULTY	MILD DIFFICULTY	MODERATE DIFFICULTY	SEVERE DIFFICULTY	UNABLE
1. Open a tight or new jar.	1	2	3	4	5
2. Write.	1	2	3	4	5
3. Turn a key.	1	2	3	4	5
4. Prepare a meal.	1	2	3	4	5
5. Push open a heavy door.	1	2	3	4	5
6. Place an object on a shelf above your head.	1	2	3	4	5
7. Do heavy household chores (e.g., wash walls, wash floors).	1	2	3	4	5
8. Garden or do yard work.	1	2	3	4	5
9. Make a bed.	1	2	3	4	5
10. Carry a shopping bag or briefcase.	1	2	3	4	5
11. Carry a heavy object (over 10 lbs).	1	2	3	4	5
12. Change a lightbulb overhead.	1	2	3	4	5
13. Wash or blow dry your hair.	1	2	3	4	5
14. Wash your back.	1	2	3	4	5
15. Put on a pullover sweater.	1	2	3	4	5
16. Use a knife to cut food.	1	2	3	4	5
17. Recreational activities which require little effort (e.g., cardplaying, knitting, etc.).	1	2	3	4	5
18. Recreational activities in which you take some force or impact through your arm, shoulder or hand (e.g., golf, hammering, tennis, etc.).	1	2	3	4	5
19. Recreational activities in which you move your arm freely (e.g., playing frisbee, badminton, etc.).	1	2	3	4	5
20. Manage transportation needs (getting from one place to another).	1	2	3	4	5
21. Sexual activities.	1	2	3	4	5

Fig. 75. The DASH questionnaire

DISABILITIES OF THE ARM, SHOULDER AND HAND

	NOT AT ALL	SLIGHTLY	MODERATELY	QUITE A BIT	EXTREMELY
22. During the past week, to what extent has your arm, shoulder or hand problem interfered with your normal social activities with family, friends, neighbours or groups? (circle number)	1	2	3	4	5
	NOT LIMITED AT ALL	SLIGHTLY LIMITED	MODERATELY LIMITED	VERY LIMITED	UNABLE
23. During the past week, were you limited in your work or other regular daily activities as a result of your arm, shoulder or hand problem? (circle number)	1	2	3	4	5
Please rate the severity of the following symptoms in the last week. (circle number)					
	NONE	MILD	MODERATE	SEVERE	EXTREME
24. Arm, shoulder or hand pain.	1	2	3	4	5
25. Arm, shoulder or hand pain when you performed any specific activity.	1	2	3	4	5
26. Tingling (pins and needles) in your arm, shoulder or hand.	1	2	3	4	5
27. Weakness in your arm, shoulder or hand.	1	2	3	4	5
28. Stiffness in your arm, shoulder or hand.	1	2	3	4	5
	NO DIFFICULTY	MILD DIFFICULTY	MODERATE DIFFICULTY	SEVERE DIFFICULTY	SO MUCH DIFFICULTY THAT I CAN'T SLEEP
29. During the past week, how much difficulty have you had sleeping because of the pain in your arm, shoulder or hand? (circle number)	1	2	3	4	5
	STRONGLY DISAGREE	DISAGREE	NEITHER AGREE NOR DISAGREE	AGREE	STRONGLY AGREE
30. I feel less capable, less confident or less useful because of my arm, shoulder or hand problem. (circle number)	1	2	3	4	5

DASH DISABILITY/SYMPTOM SCORE = $\frac{(\text{sum of } n \text{ responses})}{n} - 1$ x 25, where n is equal to the number of completed responses.

A DASH score may **not** be calculated if there are greater than 3 missing items.

Fig. 75 (continued)

DISABILITIES OF THE ARM, SHOULDER AND HAND

WORK MODULE (OPTIONAL)

The following questions ask about the impact of your arm, shoulder or hand problem on your ability to work (including homemaking if that is your main work role).

Please indicate what your job/work is: _____

I do not work. (You may skip this section.)

Please circle the number that best describes your physical ability in the past week. Did you have any difficulty:

	NO DIFFICULTY	MILD DIFFICULTY	MODERATE DIFFICULTY	SEVERE DIFFICULTY	UNABLE
1. using your usual technique for your work?	1	2	3	4	5
2. doing your usual work because of arm, shoulder or hand pain?	1	2	3	4	5
3. doing your work as well as you would like?	1	2	3	4	5
4. spending your usual amount of time doing your work?	1	2	3	4	5

SPORTS/PERFORMING ARTS MODULE (OPTIONAL)

The following questions relate to the impact of your arm, shoulder or hand problem on playing your musical instrument or sport or both.

If you play more than one sport or instrument (or play both), please answer with respect to that activity which is most important to you.

Please indicate the sport or instrument which is most important to you: _____

I do not play a sport or an instrument. (You may skip this section.)

Please circle the number that best describes your physical ability in the past week. Did you have any difficulty:

	NO DIFFICULTY	MILD DIFFICULTY	MODERATE DIFFICULTY	SEVERE DIFFICULTY	UNABLE
1. using your usual technique for playing your instrument or sport?	1	2	3	4	5
2. playing your musical instrument or sport because of arm, shoulder or hand pain?	1	2	3	4	5
3. playing your musical instrument or sport as well as you would like?	1	2	3	4	5
4. spending your usual amount of time practising or playing your instrument or sport?	1	2	3	4	5

SCORING THE OPTIONAL MODULES: Add up assigned values for each response; divide by 4 (number of items); subtract 1; multiply by 25.

An optional module score may **not** be calculated if there are any missing items.



QuickDASH

Please rate your ability to do the following activities in the last week by circling the number below the appropriate response.

	NO DIFFICULTY	MILD DIFFICULTY	MODERATE DIFFICULTY	SEVERE DIFFICULTY	UNABLE
1. Open a tight or new jar.	1	2	3	4	5
2. Do heavy household chores (e.g., wash walls, floors).	1	2	3	4	5
3. Carry a shopping bag or briefcase.	1	2	3	4	5
4. Wash your back.	1	2	3	4	5
5. Use a knife to cut food.	1	2	3	4	5
6. Recreational activities in which you take some force or impact through your arm, shoulder or hand (e.g., golf, hammering, tennis, etc.).	1	2	3	4	5

	NOT AT ALL	SLIGHTLY	MODERATELY	QUITE A BIT	EXTREMELY
7. During the past week, to what extent has your arm, shoulder or hand problem interfered with your normal social activities with family, friends, neighbours or groups?	1	2	3	4	5

	NOT LIMITED AT ALL	SLIGHTLY LIMITED	MODERATELY LIMITED	VERY LIMITED	UNABLE
8. During the past week, were you limited in your work or other regular daily activities as a result of your arm, shoulder or hand problem?	1	2	3	4	5

Please rate the severity of the following symptoms in the last week. (circle number)

	NONE	MILD	MODERATE	SEVERE	EXTREME
9. Arm, shoulder or hand pain.	1	2	3	4	5
10. Tingling (pins and needles) in your arm, shoulder or hand.	1	2	3	4	5

	NO DIFFICULTY	MILD DIFFICULTY	MODERATE DIFFICULTY	SEVERE DIFFICULTY	SO MUCH DIFFICULTY THAT I CAN'T SLEEP
11. During the past week, how much difficulty have you had sleeping because of the pain in your arm, shoulder or hand? (circle number)	1	2	3	4	5

QuickDASH DISABILITY/SYMPTOM SCORE = $\left(\frac{\text{sum of } n \text{ responses}}{n} - 1 \right) \times 25$, where n is equal to the number of completed responses.

A QuickDASH score may not be calculated if there is greater than 1 missing item.

Fig. 76. The quick DASH questionnaire

QuickDASH

WORK MODULE (OPTIONAL)

The following questions ask about the impact of your arm, shoulder or hand problem on your ability to work (including homemaking if that is your main work role).

Please indicate what your job/work is: _____

I do not work. (You may skip this section.)

Please circle the number that best describes your physical ability in the past week.

Did you have any difficulty:	NO DIFFICULTY	MILD DIFFICULTY	MODERATE DIFFICULTY	SEVERE DIFFICULTY	UNABLE
1. using your usual technique for your work?	1	2	3	4	5
2. doing your usual work because of arm, shoulder or hand pain?	1	2	3	4	5
3. doing your work as well as you would like?	1	2	3	4	5
4. spending your usual amount of time doing your work?	1	2	3	4	5

SPORTS/PERFORMING ARTS MODULE (OPTIONAL)

The following questions relate to the impact of your arm, shoulder or hand problem on playing your musical instrument or sport or both. If you play more than one sport or instrument (or play both), please answer with respect to that activity which is most important to you.

Please indicate the sport or instrument which is most important to you: _____

I do not play a sport or an instrument. (You may skip this section.)

Please circle the number that best describes your physical ability in the past week.

Did you have any difficulty:	NO DIFFICULTY	MILD DIFFICULTY	MODERATE DIFFICULTY	SEVERE DIFFICULTY	UNABLE
1. using your usual technique for playing your instrument or sport?	1	2	3	4	5
2. playing your musical instrument or sport because of arm, shoulder or hand pain?	1	2	3	4	5
3. playing your musical instrument or sport as well as you would like?	1	2	3	4	5
4. spending your usual amount of time practising or playing your instrument or sport?	1	2	3	4	5

SCORING THE OPTIONAL MODULES: Add up assigned values for each response; divide by 4 (number of items); subtract 1; multiply by 25.

An optional module score may not be calculated if there are any missing items.

A shorter version called the *QuickDASH* (Fig. 76) is also available. Both tools are valid, reliable and responsive and can be used for clinical and/or research purposes. However, because the full DASH Outcome Measure provides greater precision, it may be the best choice for clinicians who wish to monitor arm pain and function in individual patients.

19.4.1 The DASH Questionnaire

Instructions

This questionnaire asks about your symptoms as well as your ability to perform certain activities. Please answer *every question*, based on your condition in the last week, by circling the appropriate number. If you did not have the opportunity to perform an activity in the past week, please make your *best estimate* on which response would be the most accurate. It doesn't matter which hand or arm you use to perform the activity; please answer based on your ability regardless of how you perform the task.

19.4.2 The Quick DASH Questionnaire

Instructions

This questionnaire asks about your symptoms as well as your ability to perform certain activities. Please answer *every question*, based on your condition in the last week, by circling the appropriate number. If you did not have the opportunity to perform an activity in the past week, please make your *best estimate* of which response would be the most accurate. It doesn't matter which hand or arm you use to perform the activity; please answer based on your ability regardless of how you perform the task.

19.4.3 Scoring the DASH

In the spring of 2002, the authors introduced a revised scoring method for the DASH Outcome Measure. This new method is **algebraically equivalent** to the original but it is simpler, more efficient and less complicated to use when dealing with missing data. For these reasons, the authors recommend adopting this revised method; however, it does not matter which method you use as you will end up with the same score. The DASH is scored in two components: the disability/symptom ques-

tions (30 items, scored 1–5) and the optional high performance sport/music or work section (4 items, scored 1–5).

Disability/symptom score

At least 27 of the 30 items must be completed for a score to be calculated. The assigned values for all completed responses are simply summed and averaged, producing a score out of five. This value is then transformed to a score out of 100 by subtracting one and multiplying by 25. This transformation is done to make the score easier to compare to other measures scaled on a 0–100 scale. A higher score indicates greater disability.

$$\text{DASH disability/symptom score} = \frac{[(\text{sum of } n \text{ responses}) - 1] \times 25}{n},$$

where n is equal to the number of completed responses.

Optional modules (sport/music or work)

Each optional module consists of four items, which may or may not be used by individuals because of the nature of the questions. The goal of the optional modules is to identify the specific difficulties that professional athletes/performing artists or other groups of workers might experience but which may not affect their activities of daily living and consequently may go “undetected” in the 30-item portion of the DASH. The same procedure described above is followed to calculate the optional four-item module score. All four questions must be answered in order to calculate the score. Simply add up the assigned values for each response and divide by four (number of items); subtract one and multiply by 25 to get a score out of 100.

Missing Items

If more than 10% of the items (that is, more than three items) are left blank by the respondent, you will not be able to calculate a DASH disability/symptom score. By this same rule (that is, no more than 10% of the items can be left blank), no missing values can be tolerated in the high-performance sports/performing arts or work module because the module consists of only four items. This missing data “rule” applies to both the original and revised scoring methods.

19.5 The ASES (American Shoulder and Elbow Surgeons) Score [111]

The American Shoulder and Elbow Surgeons have adopted a standardized form for the assessment of the shoulder. The form has a patient self-evaluation section and a physician assessment section. The ASES standardized shoulder assessment form is offered as a baseline measure of shoulder function applicable to all patients regardless of diagnosis.

Demographic information

The patient's name, age, hand dominance, sex, diagnosis, and procedure are noted (Fig. 77a). Spaces are available to note the date of the assessment and the date of procedure, if an operative procedure has been performed. An annotation is also present to indicate whether the patient is being seen for the first time and, if not, what the length of follow-up is. It is anticipated that many clinicians will wish to “customize” this portion of the form according to their needs and the format of patient demographic information at their parent institution.

Patient self-evaluation

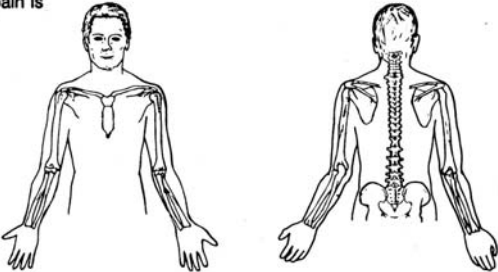
The patient self-evaluation form is divided into three sections.

Pain. The first section concerns pain (Fig. 77b). The patients are asked to identify whether they are having pain in the shoulder and are asked to record the location of their pain on the pain diagram. Patients are asked whether they have pain at night and whether they take pain medication. The next question identifies the use of a nonnarcotic analgesic. Another question identifies the use of narcotic medication. The patient is asked to record the number of pills required each day. The severity of pain is graded on a 10 cm visual analog scale that ranges from 0 (no pain at all) to 10 (pain as bad as it can be).

Instability. The patient is asked to identify whether he or she experiences symptoms of instability (Fig. 77c). The sensation of instability experienced by the patient is assessed quantitatively according to a visual analog scale. A higher score is given, if the shoulder feels very unstable.

SHOULDER ASSESSMENT FORM		
AMERICAN SHOULDER AND ELBOW SURGEONS		
Name:		Date
Age:	Hand dominance: R L Ambi	Sex: M F
Diagnosis:		Initial Assess? Y N
Procedure/Date:		Follow-up: M; Y

a

PATIENT SELF-EVALUATION		
Are you having pain in your shoulder? (circle correct answer)	Yes	No
Mark where your pain is		
		
Do you have pain in your shoulder at night?	Yes	No
Do you take pain medication (aspirin, Advil, Tylenol etc.)?	Yes	No
Do you take narcotic pain medication (codeine or stronger)?	Yes	No
How many pills do you take each day (average)?	pills	
How bad is your pain today (mark line)?		
0 <input type="checkbox"/> <input type="checkbox"/> <input type="checkbox"/> <input type="checkbox"/> <input type="checkbox"/> <input type="checkbox"/> <input type="checkbox"/> <input type="checkbox"/> <input type="checkbox"/> <input type="checkbox"/> <input type="checkbox"/> <input type="checkbox"/> 10 No pain at all Pain as bad as it can be		

b

Fig. 77. ASES score. a Demographic information. b Patient self-evaluation: pain questionnaire

Does your shoulder feel unstable (as if it is going to dislocate?)	Yes	No
How unstable is your shoulder (mark line)?		
Very stable	0	10
	Very unstable	

Fig. 77 c. Patient self-evaluation: instability questionnaire

Circle the number in the box that indicates your ability to do the following activities: 0 = Unable to do; 1 = Very difficult to do; 2 = Somewhat difficult; 3 = Not difficult		
ACTIVITY	RIGHT ARM	LEFT ARM
1. Put on a coat	0 1 2 3	0 1 2 3
2. Sleep on your painful or affected side	0 1 2 3	0 1 2 3
3. Wash back/do up bra in back	0 1 2 3	0 1 2 3
4. Manage toileting	0 1 2 3	0 1 2 3
5. Comb hair	0 1 2 3	0 1 2 3
6. Reach a high shelf	0 1 2 3	0 1 2 3
7. Lift 10 lbs. above shoulder	0 1 2 3	0 1 2 3
8. Throw a ball overhand	0 1 2 3	0 1 2 3
9. Do usual work - List:	0 1 2 3	0 1 2 3
10. Do usual sport - List:	0 1 2 3	0 1 2 3

Fig. 77 d. Patient self-evaluation: activity of daily living questionnaire

Activities of daily living. Ten activities of daily living are assessed on a four-point ordinal scale (Fig. 77 d). The patients are asked to circle 0, if they are unable to do the activity, 1, if they find it very difficult to do the activity, 2, if they find it somewhat difficult to do the activity, and 3, if they find no difficulty in performing the activity. Each shoulder is assessed separately. Because 10 questions are asked the maximum score is 30. The 10 questions include activities that are heavily dependant on a range of shoulder motion that is free from pain. The patients are also asked to identify their normal work and sporting activities. The cumulative activities of the daily living score is derived by totalling the scores awarded for each of the individual activities.

PHYSICIAN ASSESSMENT				
RANGE OF MOTION Total shoulder motion Goniometer preferred	RIGHT		LEFT	
	Active	Passive	Active	Passive
Forward elevation (Maximum arm-trunk angle)				
External rotation (Arm comfortably at side)				
External rotation (Arm at 90° abduction)				
Internal rotation (Highest posterior anatomy reached with thumb)				
Cross-body adduction (Antecubital fossa to opposite acromion)				

Fig. 77 e. Physician assessment: range of motion

SIGNS									
0 = none; 1 = mild; 2 = moderate; 3 = severe									
SIGN		Right		Left					
Supraspinatus/greater tuberosity tenderness		0	1	2	3	0	1	2	3
AC joint tenderness		0	1	2	3	0	1	2	3
Biceps tendon tenderness (or rupture)		0	1	2	3	0	1	2	3
Other tenderness - List:		0	1	2	3	0	1	2	3
Impingement I (Passive forward elevation in slight internal rotation)		Y	N			Y	N		
Impingement II (Passive internal rotation with 90° flexion)		Y	N			Y	N		
Impingement III (90° active abduction - classic painful arc)		Y	N			Y	N		
Subacromial crepitus		Y	N			Y	N		
Scars - location		Y	N			Y	N		
Atrophy - location:		Y	N			Y	N		
Deformity : describe		Y	N			Y	N		

Fig. 77 f. Physician assessment: signs

STRENGTH (record MRC grade)		
0 = no contraction; 1 = flicker; 2 = movement with gravity eliminated 3 = movement against gravity; 4 = movement against some resistance; 5 = normal power.		
	Right	Left
Testing affected by pain?	Y N	Y N
Forward elevation	0 1 2 3 4 5	0 1 2 3 4 5
Abduction	0 1 2 3 4 5	0 1 2 3 4 5
External rotation (Arm comfortably at side)	0 1 2 3 4 5	0 1 2 3 4 5
Internal rotation (Arm comfortably at side)	0 1 2 3 4 5	0 1 2 3 4 5

g

INSTABILITY		
0 = none; 1 = mild (0 - 1 cm translation) 2 = moderate (1 - 2 cm translation or translates to glenoid rim) 3 = severe (> 2 cm translation or over rim of glenoid)		
Anterior translation	0 1 2 3	0 1 2 3
Posterior translation	0 1 2 3	0 1 2 3
Inferior translation (sulcus sign)	0 1 2 3	0 1 2 3
Anterior apprehension	0 1 2 3	0 1 2 3
Reproduces symptoms?	Y N	Y N
Voluntary instability?	Y N	Y N
Relocation test positive?	Y N	Y N
Generalized ligamentous laxity?	Y N	
Other physical findings:		
Examiner's name:		
		Date

h

Fig. 77. g Physician assessment: strength. h Physician assessment: instability

Physician assessment

The physician assessment portion of the form consists of the following sections.

Range of motion. Total (combined glenohumeral and scapulothoracic) shoulder motion is measured, because the ability to differentiate glenohumeral from scapulothoracic motion is not consistent (Fig. 77 e). Both active and passive motion for both shoulders is recorded. The use of a goniometer is preferred. Forward elevation is measured as the maximum arm-trunk angle viewed from any direction. External rotation is measured with the arm comfortably at the side and also with the arm at 90° of abduction. Internal rotation is measured by noting the highest segment of spinal anatomy reached with the thumb. Cross-body adduction is measured by measuring the distance of the antecubital fossa from the opposite acromion.

Signs. Signs are graded 0 if not present, 1 if mild, 2 if moderate, and 3 if severe (Fig. 77 f). Signs that are assessed include supraspinatus or greater tuberosity tenderness, acromioclavicular joint tenderness, and biceps tendon tenderness or biceps tendon rupture. If tendon tenderness is present in other locations, the examiner is asked to note the location. Impingement is assessed in three ways: (1) passive forward elevation of the shoulder in slight internal rotation; (2) passive internal rotation at 90° of flexion; and (3) at 90° of active abduction (the classic painful arc). The presence or absence of subacromial crepitus is noted as are the presence or absence of scars, atrophy, and deformity. The examiner is asked to record the exact location of scars, atrophy, or deformity, if they do exist.

Strength. Strength is graded according to the Medical Research Council grade (Fig. 77 g). The examiner is asked to note whether pain may be influencing the assessment. Strength is measured in forward elevation, abduction, external rotation with the arm comfortably at the side, and internal rotation with the arm comfortably at the side.

Instability. Instability is graded 0, if absent, 1, if mild (0- to 1-cm translation), 2, if moderate (1- to 2-cm translation or translates to the glenoid rim), 3, if severe (greater than 2-cm translation or over rim of glenoid).

noid) (Fig. 77 h). The presence of absence of anterior translation, posterior translation, inferior translation, and anterior apprehension are all noted and graded. The examiner is asked to note whether the previously mentioned manoeuvres reproduce the patient's symptoms and whether the patients have voluntary instability, a positive relocation test, or generalized ligamentous laxity. Space is present for recording other physical findings. The examiner is asked to sign the form.

Shoulder score index

The information obtained from the patient self-evaluation form can be used to derive shoulder score. Equal weight is given to degree of pain experienced by the patient and the cumulative ADL score. The shoulder score is derived by the following formula. $(10 - \text{visual analog scale pain score}) \times 5 = \bullet + (5/3) \times \text{Cumulative ADL score}$. For example, if the visual analog scale pain score is 6, and the cumulative ADL score is 22, the shoulder function index is: $([10 - 6] \times 5 = 20) + (5/3 \times 22 = 37) = 57$ (out of a possible 100).

19.6 Simple shoulder test [79]

The Simple Shoulder Test (SST) was designed as a function-based outcome assessment tool consisting of 12 questions derived from Neer's evaluation, the ASES evaluation, and the most frequent complaints of patients observed in the shoulder practice at the University of Washington. Hundreds of additional shoulder functions could have been included, but the goal was to narrow the margin to a pertinent, yet manageable set of daily activities. The questions require only a "yes" or "no" response because the bottom line is whether the patient feels he or she can actually perform that function. Once instructed on the initial visit, the patient can administer his or her own SST in about three minutes. The only pieces of equipment necessary are 1-, 8-, and 20-pound weights. Answering the SST questions does not involve the treating physician, removing an important source of bias and making the assessment tool feasible for the busy practitioner. The physician's role is strictly to determine the patient's diagnosis and provide the treatment options. Follow-up evaluations are performed by the patient at home

and reported by mail or phone. This decreases the “lost to follow-up” category of patients, because patients are not required to return to the office for reevaluation. No score is derived, and results are not classified into fair, good, excellent, and limited goals categories. Instead, specific functional deficits for a given shoulder disorder and the observed improvement in these functions after specific treatment may be explained to the patient in simple terms, thereby improving informed consent. For example, the patient may learn that 90% of patients having procedure P, for diagnosis D, performed by Dr. C, regain their ability to sleep on their side or that 30% can lift an 8-lb weight above their head.

The simple shoulder test kit

Instructions for the use of the SST assessment tool are provided herein. Use of the kit provided will allow analysis of the functional outcomes of your own patients and their demonstration to subsequent patients without need of a computer. Strict inclusion criteria for each diagnosis and treatment group that you wish to study should be defined prior to data collection.

Figure 78a is the SST questionnaire to be given the patient at each appropriate interval. The top portion includes important demographic information to facilitate follow-up assessments. The patient’s occupation may be correlated to question 12, ability to work full-time at a regular job. If desired, the hand dominance can be associated with questions 9 and 10, which regard throwing. Next are the 12 functional questions; patients should be reminded to answer each by checking “yes” or “no” only. At the bottom is the SST classification (for office use only). The physician’s main role is to provide the diagnosis and particular treatment of the patient. The eight common shoulder diagnoses the authors defined are abbreviated, but the SST may be used for any diagnostic group desired. The SST should be denoted as the patient’s initial, preoperative, or particular follow-up assessment. The follow-up interval is calculated either from the initial SST date if nonsurgical treatment was prescribed or from the surgery date if a procedure was performed.

Figure 78b is the SST tabulation form. The response to the 12 questions for patients that meet specific circumstances (for example, SST = one year follow-up, diagnosis = DJD, and treatment = total shoulder arthroplasty) should be recorded on the same sheet. Affirmative answers

Last		First		M.I.		Date: / /		Age:	
Street/Apt #			City		State		Zip Code		
Address:						Occupation:			
Home		Business		Relative					
Phone: () -		() -		() -					
Dominant Hand: Right / Left / Ambidextrous					Shoulder Evaluated: Right / Left				

Answer each question below by checking "Yes" or "No"

	Response		
	Yes	No	
1. Is your shoulder comfortable with your arm at rest by your side?	<input type="checkbox"/>	<input type="checkbox"/>	1
2. Does your shoulder allow you to sleep comfortably?	<input type="checkbox"/>	<input type="checkbox"/>	2
3. Can you reach the small of your back to tuck in your shirt with your hand?	<input type="checkbox"/>	<input type="checkbox"/>	3
4. Can you place your hand behind your head with the elbow straight out to the side?	<input type="checkbox"/>	<input type="checkbox"/>	4
5. Can you place a coin on a shelf at the level of your shoulder without bending your elbow?	<input type="checkbox"/>	<input type="checkbox"/>	5
6. Can you lift one pound (a full pint container) to the level of your shoulder without bending your elbow?	<input type="checkbox"/>	<input type="checkbox"/>	6
7. Can you lift eight pounds (a full gallon container) to the level of your shoulder without bending your elbow?	<input type="checkbox"/>	<input type="checkbox"/>	7
8. Can you carry twenty pounds at your side with the affected extremity?	<input type="checkbox"/>	<input type="checkbox"/>	8
9. Do you think you can toss a softball under-hand ten yards with the affected extremity?	<input type="checkbox"/>	<input type="checkbox"/>	9
10. Do you think you can toss a softball over-hand twenty yards with the affected extremity?	<input type="checkbox"/>	<input type="checkbox"/>	10
11. Can you wash the back of your opposite shoulder with the affected extremity?	<input type="checkbox"/>	<input type="checkbox"/>	11
12. Would your shoulder allow you to work full-time at your regular job?	<input type="checkbox"/>	<input type="checkbox"/>	12

Office Use Only

Diagnosis: DJD RA AVN IMP RCT FS TUBS AMBRII Other: _____
 Dx Confirmed? _____ Pt # _____ Physician _____
 SST: Initial / Pre-op / Follow-up: 6 mon 1 yr 18 mon 2 yr 3 yr 4 yr 5 yr Other: _____
 Initial SST Date: / / Rx: _____ Surgery Date: / /

a

Fig. 78. The Simple Shoulder Test. a Simple Shoulder Test questionnaire form

Diagnosis: DJD RA AVN Imp RCT FS TUBS AMBRII Other _____
 SST? Initial / Pre-op / Follow-up: 6 mon 1 yr 18 mon 2 yr 3 yr 4 yr 5 yr Other: _____
 Treatment: _____

Patient Name	Shoulder Side		Q1	Q2	Q3	Q4	Q5	Q6	Q7	Q8	Q9	Q10	Q11	Q12	
1. _____	R L	1													
2. _____	R L	2													
3. _____	R L	3													
4. _____	R L	4													
5. _____	R L	5													
6. _____	R L	6													
7. _____	R L	7													
8. _____	R L	8													
9. _____	R L	9													
10. _____	R L	10													
11. _____	R L	11													
12. _____	R L	12													
13. _____	R L	13													
14. _____	R L	14													
15. _____	R L	15													
16. _____	R L	16													
17. _____	R L	17													
18. _____	R L	18													
19. _____	R L	19													
20. _____	R L	20													
21. _____	R L	21													
22. _____	R L	22													
23. _____	R L	23													
24. _____	R L	24													
25. _____	R L	25													
SST Summary			Total Yes												
			Total Pts												
			% Yes												
				Q1	Q2	Q3	Q4	Q5	Q6	Q7	Q8	Q9	Q10	Q11	Q12

Fig. 78 b. Simple Shoulder Test patient tabulation for diagnosis and treatment

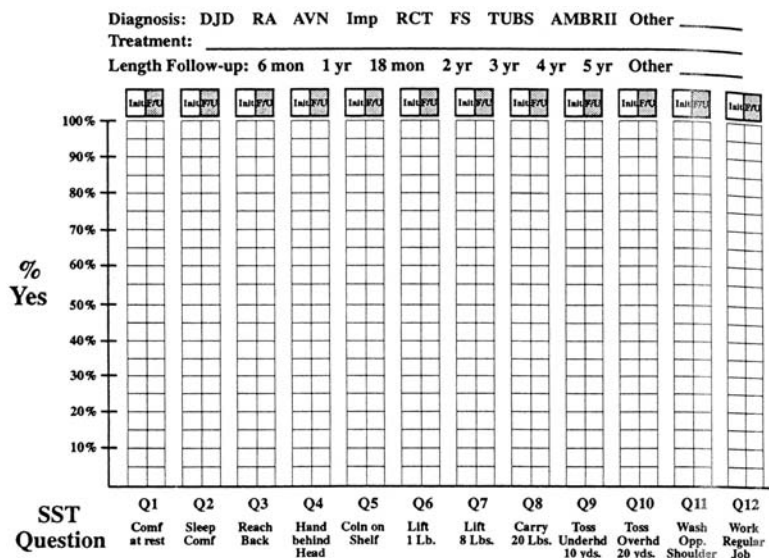


Fig. 78c. Simple Shoulder Test follow-up graph for diagnosis and treatment

to questions may be recorded as “1” and negative answers as “0” to aid in the statistical summation at the bottom. The total number of yes answers for a given question divided by total number of patients provides the percent of patients in that group who can perform that function. A separate SST tabulation sheet should be labelled for the initial visit and each follow-up period so that changes in function may be compared at intervals for the treatment group.

Figure 78c is the SST Graph Template, which allows graphic comparison of functional outcome. Percentage results from two respective SST tabulation sheets, for example, initial visit DJD versus six months after arthroplasty, may be compared in the form of bar graphs. This provides a visual aid when describing functional results to patients.

19.7 Short form 36 (SF-36)*

The SF-36 (Fig. 79 a,b) is a multi-purpose, short-form health survey with only 36 questions. It yields an 8-scale profile of functional health and well-being scores as well as psychometrically-based physical and mental health summary measures and a preference-based health utility index. It is a generic measure, as opposed to one that targets a specific age, disease, or treatment group. Accordingly, the SF-36 has proven useful in surveys of general and specific populations, comparing the relative burden of diseases, and in differentiating the health benefits produced by a wide range of different treatments. This book chapter summarizes the steps in the construction of the SF-36; how it led to the development of an even shorter (1-page, 2-minute) survey form – the SF-12; the improvements reflected in Version 2.0 of the SF-36 (Fig. 79 c,d); psychometric studies of assumptions underlying scale construction and scoring; how they have been translated in more than 50 countries as part of the International Quality of Life Assessment (IQOLA) Project; and studies of reliability and validity.

SF-36 Literature

The experience to date with the SF-36 has been documented in nearly 4,000 publications; citations for those published in 1988 through 2000 are documented in a bibliography covering the SF-36 and other instruments in the “SF” family of tools (Turner-Bowker et al. 2002). The most complete information about the history and development of the SF-36, its psychometric evaluation, studies of reliability and validity, and normative data is available in the first of three SF-36 user’s manuals (Ware et al. 1993). This information was also summarized in the first two peer-reviewed articles about the SF-36 (Ware and Sherbourne 1992; McHorney et al. 1993). A second manual documents the development and validation of the SF-36 physical and mental component summary measures and presents norms for those measures (Ware et al. 1994; Ware et al. 2000). These user’s manuals have been updated to include more up-to-date norms and other findings and to document the much improved Version 2.0 (SF-36v2), which are discussed below (Ware et al. 2000; Ware and Kosinski 2001). A fourth manual, first published in 1995 (Ware et al. 1995) and recently updated (Ware et al. 2002) presents

SF-36v1 Standard

Your Health and Well-Being

This survey asks for your views about your health. This information will help keep track of how you feel and how well you are able to do your usual activities. *Thank you for completing this survey!*

For each of the following questions, please mark an in the one box that best describes your answer.

1. In general, would you say your health is:

Excellent	Very good	Good	Fair	Poor
<input type="checkbox"/>	<input type="checkbox"/>	<input type="checkbox"/>	<input type="checkbox"/>	<input type="checkbox"/>

2. Compared to one year ago, how would you rate your health in general now?

Much better now than one year ago	Somewhat better now than one year ago	About the same as one year ago	Somewhat worse now than one year ago	Much worse now than one year ago
<input type="checkbox"/>	<input type="checkbox"/>	<input type="checkbox"/>	<input type="checkbox"/>	<input type="checkbox"/>

SF-36® Health Survey © 1988, 2002 by Medical Outcomes Trust and QualityMetric Incorporated. All Rights Reserved. SF-36® is a registered trademark of Medical Outcomes Trust. (SF-36 Standard, US Version 1.0)

Fig. 79 a. SF-36v1 Standard

3. The following items are about activities you might do during a typical day. Does your health now limit you in these activities? If so, how much?

	Yes, limited a lot	Yes, limited a little	No, not limited at all
• Vigorous activities, such as running, lifting heavy objects, participating in strenuous sports	<input type="checkbox"/>	<input type="checkbox"/>	<input type="checkbox"/>
• Moderate activities, such as moving a table, pushing a vacuum cleaner, bowling, or playing golf	<input type="checkbox"/>	<input type="checkbox"/>	<input type="checkbox"/>
• Lifting or carrying groceries	<input type="checkbox"/>	<input type="checkbox"/>	<input type="checkbox"/>
• Climbing several flights of stairs	<input type="checkbox"/>	<input type="checkbox"/>	<input type="checkbox"/>
• Climbing one flight of stairs	<input type="checkbox"/>	<input type="checkbox"/>	<input type="checkbox"/>
• Bending, kneeling, or stooping	<input type="checkbox"/>	<input type="checkbox"/>	<input type="checkbox"/>
• Walking more than a mile	<input type="checkbox"/>	<input type="checkbox"/>	<input type="checkbox"/>
• Walking several blocks	<input type="checkbox"/>	<input type="checkbox"/>	<input type="checkbox"/>
• Walking one block	<input type="checkbox"/>	<input type="checkbox"/>	<input type="checkbox"/>
• Bathing or dressing yourself	<input type="checkbox"/>	<input type="checkbox"/>	<input type="checkbox"/>

SF-36® Health Survey © 1988, 2002 by Medical Outcomes Trust and QualityMetric Incorporated. All Rights Reserved. SF-36® is a registered trademark of Medical Outcomes Trust. (SF-36 Standard, US Version 1.0)

6. During the **past 4 weeks**, to what extent has your physical health or emotional problems interfered with your normal social activities with family, friends, neighbors, or groups?

Not at all	Slightly	Moderately	Quite a bit	Extremely
<input type="radio"/>	<input type="radio"/>	<input type="radio"/>	<input type="radio"/>	<input type="radio"/>

7. How much **bodily pain** have you had during the **past 4 weeks**?

None	Very mild	Mild	Moderate	Severe	Very Severe
<input type="radio"/>	<input type="radio"/>	<input type="radio"/>	<input type="radio"/>	<input type="radio"/>	<input type="radio"/>

8. During the **past 4 weeks**, how much did **gain** interfere with your normal work (including both work outside the home and housework)?

Not at all	A little bit	Moderately	Quite a bit	Extremely
<input type="radio"/>	<input type="radio"/>	<input type="radio"/>	<input type="radio"/>	<input type="radio"/>

4. During the **past 4 weeks**, have you had any of the following problems with your work or other regular daily activities as a result of your **physical health**?

	Yes	No
• Cut down on the amount of time you spent on work or other activities	<input type="radio"/>	<input type="radio"/>
• Accomplished less than you would like	<input type="radio"/>	<input type="radio"/>
• Were limited in the kind of work or other activities	<input type="radio"/>	<input type="radio"/>
• Had difficulty performing the work or other activities (for example, it took extra effort)	<input type="radio"/>	<input type="radio"/>

5. During the **past 4 weeks**, have you had any of the following problems with your work or other regular daily activities as a result of any **emotional problems** (such as feeling depressed or anxious)?

	Yes	No
• Cut down on the amount of time you spent on work or other activities	<input type="radio"/>	<input type="radio"/>
• Accomplished less than you would like	<input type="radio"/>	<input type="radio"/>
• Did work or other activities less carefully than usual	<input type="radio"/>	<input type="radio"/>

SF-36 Health Survey © 1988, 2002 by Medical Outcome Trust and QualityMetric Incorporated. All Rights Reserved.
SF-36® is a registered trademark of Medical Outcome Trust.

SF-36 Health Survey © 1988, 2002 by Medical Outcome Trust and QualityMetric Incorporated. All Rights Reserved.
SF-36® is a registered trademark of Medical Outcome Trust.

Fig. 79 a (continued)

9. These questions are about how you feel and how things have been with you during the **past 4 weeks**. For each question, please give the one answer that comes closest to the way you have been feeling. How much of the time during the **past 4 weeks**...

	All of the time	Most of the time	A good bit of the time	Some of the time	A little of the time	None of the time
• Did you feel full of pep?	<input type="radio"/>	<input type="radio"/>	<input type="radio"/>	<input type="radio"/>	<input type="radio"/>	<input type="radio"/>
• Have you been a very nervous person?	<input type="radio"/>	<input type="radio"/>	<input type="radio"/>	<input type="radio"/>	<input type="radio"/>	<input type="radio"/>
• Have you felt so down in the dumps that nothing could cheer you up?	<input type="radio"/>	<input type="radio"/>	<input type="radio"/>	<input type="radio"/>	<input type="radio"/>	<input type="radio"/>
• Have you felt calm and peaceful?	<input type="radio"/>	<input type="radio"/>	<input type="radio"/>	<input type="radio"/>	<input type="radio"/>	<input type="radio"/>
• Did you have a lot of energy?	<input type="radio"/>	<input type="radio"/>	<input type="radio"/>	<input type="radio"/>	<input type="radio"/>	<input type="radio"/>
• Have you felt downhearted and blue?	<input type="radio"/>	<input type="radio"/>	<input type="radio"/>	<input type="radio"/>	<input type="radio"/>	<input type="radio"/>
• Did you feel worn out?	<input type="radio"/>	<input type="radio"/>	<input type="radio"/>	<input type="radio"/>	<input type="radio"/>	<input type="radio"/>
• Have you been a happy person?	<input type="radio"/>	<input type="radio"/>	<input type="radio"/>	<input type="radio"/>	<input type="radio"/>	<input type="radio"/>
• Did you feel tired?	<input type="radio"/>	<input type="radio"/>	<input type="radio"/>	<input type="radio"/>	<input type="radio"/>	<input type="radio"/>

SF-36® Health Survey © 1988, 2002 by Medical Outcomes Trust and QualityMetric Incorporated. All Rights Reserved.
SF-36® is a registered trademark of Medical Outcomes Trust.
(SF-36) Standard, US Version 1.0

Fig. 79 a (continued)

10. During the **past 4 weeks**, how much of the time has your physical health or emotional problems interfered with your social activities (like visiting friends, relatives, etc.)?

All of the time	Most of the time	Some of the time	A little of the time	None of the time
<input type="radio"/>	<input type="radio"/>	<input type="radio"/>	<input type="radio"/>	<input type="radio"/>

11. How TRUE or FALSE is each of the following statements for you?

	Definitely true	Mostly true	Don't know	Mostly false	Definitely false
• I seem to get sick a little easier than other people	<input type="radio"/>	<input type="radio"/>	<input type="radio"/>	<input type="radio"/>	<input type="radio"/>
• I am as healthy as anybody I know	<input type="radio"/>	<input type="radio"/>	<input type="radio"/>	<input type="radio"/>	<input type="radio"/>
• I expect my health to get worse	<input type="radio"/>	<input type="radio"/>	<input type="radio"/>	<input type="radio"/>	<input type="radio"/>
• My health is excellent	<input type="radio"/>	<input type="radio"/>	<input type="radio"/>	<input type="radio"/>	<input type="radio"/>

Thank you for completing these questions!

SF-36® Health Survey © 1988, 2002 by Medical Outcomes Trust and QualityMetric Incorporated. All Rights Reserved.
SF-36® is a registered trademark of Medical Outcomes Trust.
(SF-36) Standard, US Version 1.0

SF-36v1 Acute

Your Health and Well-Being

This survey asks for your views about your health. This information will help keep track of how you feel and how well you are able to do your usual activities. *Thank you for completing this survey!*

For each of the following questions, please mark an in the one box that best describes your answer.

1. In general, would you say your health is:

Excellent	Very good	Good	Fair	Poor
<input type="checkbox"/>	<input type="checkbox"/>	<input type="checkbox"/>	<input type="checkbox"/>	<input type="checkbox"/>

2. Compared to one week ago, how would you rate your health in general now?

Much better now than one week ago	Somewhat better now than one week ago	About the same as one week ago	Somewhat worse now than one week ago	Much worse now than one week ago
<input type="checkbox"/>	<input type="checkbox"/>	<input type="checkbox"/>	<input type="checkbox"/>	<input type="checkbox"/>

3. The following items are about activities you might do during a typical day. Does your health now limit you in these activities? If so, how much?

	Yes, limited a lot	Yes, limited a little	No, not limited at all
• Vigorous activities, such as running, lifting heavy objects, participating in strenuous sports	<input type="checkbox"/>	<input type="checkbox"/>	<input type="checkbox"/>
• Moderate activities, such as moving a table, pushing a vacuum cleaner, bowling, or playing golf	<input type="checkbox"/>	<input type="checkbox"/>	<input type="checkbox"/>
• Lifting or carrying groceries	<input type="checkbox"/>	<input type="checkbox"/>	<input type="checkbox"/>
• Climbing several flights of stairs	<input type="checkbox"/>	<input type="checkbox"/>	<input type="checkbox"/>
• Climbing one flight of stairs	<input type="checkbox"/>	<input type="checkbox"/>	<input type="checkbox"/>
• Bending, kneeling, or stooping	<input type="checkbox"/>	<input type="checkbox"/>	<input type="checkbox"/>
• Walking more than a mile	<input type="checkbox"/>	<input type="checkbox"/>	<input type="checkbox"/>
• Walking several blocks	<input type="checkbox"/>	<input type="checkbox"/>	<input type="checkbox"/>
• Walking one block	<input type="checkbox"/>	<input type="checkbox"/>	<input type="checkbox"/>
• Bathing or dressing yourself	<input type="checkbox"/>	<input type="checkbox"/>	<input type="checkbox"/>

SF-36® Health Survey © 1988, 2002 by Medical Outcomes Trust and QualityMetric Incorporated. All Rights Reserved. SF-36® is a registered trademark of Medical Outcomes Trust. (SF-36 v1 Acute, US Version 1.0)

SF-36® Health Survey © 1988, 2002 by Medical Outcomes Trust and QualityMetric Incorporated. All Rights Reserved. SF-36® is a registered trademark of Medical Outcomes Trust. (SF-36 v1 Acute, US Version 1.0)

Fig. 79b. SF-36v1 Acute

4. During the past week, have you had any of the following problems with your work or other regular daily activities as a result of your physical health?

- | | | |
|---|--------------------------|--------------------------|
| | Yes | No |
| | ▶ | ▶ |
| • Cut down on the amount of time you spent on work or other activities..... | <input type="checkbox"/> | <input type="checkbox"/> |
| • Accomplished less than you would like..... | <input type="checkbox"/> | <input type="checkbox"/> |
| • Were limited in the kind of work or other activities..... | <input type="checkbox"/> | <input type="checkbox"/> |
| • Had difficulty performing the work or other activities (for example, it took extra effort)..... | <input type="checkbox"/> | <input type="checkbox"/> |

5. During the past week, have you had any of the following problems with your work or other regular daily activities as a result of any emotional problems (such as feeling depressed or anxious)?

- | | | |
|---|--------------------------|--------------------------|
| | Yes | No |
| | ▶ | ▶ |
| • Cut down on the amount of time you spent on work or other activities..... | <input type="checkbox"/> | <input type="checkbox"/> |
| • Accomplished less than you would like..... | <input type="checkbox"/> | <input type="checkbox"/> |
| • Did work or other activities less carefully than usual..... | <input type="checkbox"/> | <input type="checkbox"/> |

SF-36® Health Survey © 1988, 2002 by Medical Outcomes Trust and QualityMetric Incorporated. All Rights Reserved.
SF-36® is a registered trademark of Medical Outcomes Trust.
(SF-36 Adult, US Version 1.0)

Fig. 79b (continued)

6. During the past week, to what extent has your physical health or emotional problems interfered with your normal social activities with family, friends, neighbors, or groups?

- | | | | | | |
|--|--------------------------|--------------------------|--------------------------|--------------------------|--------------------------|
| | Not at all | Slightly | Moderately | Quite a bit | Extremely |
| | ▶ | ▶ | ▶ | ▶ | ▶ |
| | <input type="checkbox"/> | <input type="checkbox"/> | <input type="checkbox"/> | <input type="checkbox"/> | <input type="checkbox"/> |

7. How much bodily pain have you had during the past week?

- | | | | | | | |
|--|--------------------------|--------------------------|--------------------------|--------------------------|--------------------------|--------------------------|
| | None | Very mild | Mild | Moderate | Severe | Very Severe |
| | ▶ | ▶ | ▶ | ▶ | ▶ | ▶ |
| | <input type="checkbox"/> | <input type="checkbox"/> | <input type="checkbox"/> | <input type="checkbox"/> | <input type="checkbox"/> | <input type="checkbox"/> |

8. During the past week, how much did pain interfere with your normal work (including both work outside the home and housework)?

- | | | | | | |
|--|--------------------------|--------------------------|--------------------------|--------------------------|--------------------------|
| | Not at all | A little bit | Moderately | Quite a bit | Extremely |
| | ▶ | ▶ | ▶ | ▶ | ▶ |
| | <input type="checkbox"/> | <input type="checkbox"/> | <input type="checkbox"/> | <input type="checkbox"/> | <input type="checkbox"/> |

SF-36® Health Survey © 1988, 2002 by Medical Outcomes Trust and QualityMetric Incorporated. All Rights Reserved.
SF-36® is a registered trademark of Medical Outcomes Trust.
(SF-36 Adult, US Version 1.0)

9. These questions are about how you feel and how things have been with you during the past week. For each question, please give the one answer that comes closest to the way you have been feeling. How much of the time during the past week...

	All of the time	Most of the time	A good bit of the time	Some of the time	A little of the time	None of the time
• Did you feel full of pep?	<input type="checkbox"/>	<input type="checkbox"/>	<input type="checkbox"/>	<input type="checkbox"/>	<input type="checkbox"/>	<input type="checkbox"/>
• Have you been a very nervous person?	<input type="checkbox"/>	<input type="checkbox"/>	<input type="checkbox"/>	<input type="checkbox"/>	<input type="checkbox"/>	<input type="checkbox"/>
• Have you felt so down in the dumps that nothing could cheer you up?	<input type="checkbox"/>	<input type="checkbox"/>	<input type="checkbox"/>	<input type="checkbox"/>	<input type="checkbox"/>	<input type="checkbox"/>
• Have you felt calm and peaceful?	<input type="checkbox"/>	<input type="checkbox"/>	<input type="checkbox"/>	<input type="checkbox"/>	<input type="checkbox"/>	<input type="checkbox"/>
• Did you have a lot of energy?	<input type="checkbox"/>	<input type="checkbox"/>	<input type="checkbox"/>	<input type="checkbox"/>	<input type="checkbox"/>	<input type="checkbox"/>
• Have you felt downhearted and blue?	<input type="checkbox"/>	<input type="checkbox"/>	<input type="checkbox"/>	<input type="checkbox"/>	<input type="checkbox"/>	<input type="checkbox"/>
• Did you feel worn out?	<input type="checkbox"/>	<input type="checkbox"/>	<input type="checkbox"/>	<input type="checkbox"/>	<input type="checkbox"/>	<input type="checkbox"/>
• Have you been a happy person?	<input type="checkbox"/>	<input type="checkbox"/>	<input type="checkbox"/>	<input type="checkbox"/>	<input type="checkbox"/>	<input type="checkbox"/>
• Did you feel tired?	<input type="checkbox"/>	<input type="checkbox"/>	<input type="checkbox"/>	<input type="checkbox"/>	<input type="checkbox"/>	<input type="checkbox"/>

10. During the past week, how much of the time has your physical health or emotional problems interfered with your social activities (like visiting friends, relatives, etc.)?

	All of the time	Most of the time	Some of the time	A little of the time	None of the time
<input type="checkbox"/>	<input type="checkbox"/>	<input type="checkbox"/>	<input type="checkbox"/>	<input type="checkbox"/>	<input type="checkbox"/>

SF-36 Health Survey © 1988, 2002 by Medical Outcomes Trust and QualityMetric Incorporated. All Rights Reserved.
SF-36 is a registered trademark of Medical Outcomes Trust.
(SF-36-ANAL, US Version 1.0)

Fig. 79 b (continued)

11. How TRUE or FALSE is each of the following statements for you?

	Definitely true	Mostly true	Don't know	Mostly false	Definitely false
• I seem to get sick a little easier than other people	<input type="checkbox"/>	<input type="checkbox"/>	<input type="checkbox"/>	<input type="checkbox"/>	<input type="checkbox"/>
• I am as healthy as anybody I know	<input type="checkbox"/>	<input type="checkbox"/>	<input type="checkbox"/>	<input type="checkbox"/>	<input type="checkbox"/>
• I expect my health to get worse	<input type="checkbox"/>	<input type="checkbox"/>	<input type="checkbox"/>	<input type="checkbox"/>	<input type="checkbox"/>
• My health is excellent	<input type="checkbox"/>	<input type="checkbox"/>	<input type="checkbox"/>	<input type="checkbox"/>	<input type="checkbox"/>

Thank you for completing these questions!

SF-36 Health Survey © 1988, 2002 by Medical Outcomes Trust and QualityMetric Incorporated. All Rights Reserved.
SF-36 is a registered trademark of Medical Outcomes Trust.
(SF-36-ANAL, US Version 1.0)

SF-36v2 Standard

Your Health and Well-Being

This survey asks for your views about your health. This information will help keep track of how you feel and how well you are able to do your usual activities. *Thank you for completing this survey!*

For each of the following questions, please mark an in the one box that best describes your answer.

1. In general, would you say your health is:

Excellent	Very good	Good	Fair	Poor
<input type="checkbox"/>	<input type="checkbox"/>	<input type="checkbox"/>	<input type="checkbox"/>	<input type="checkbox"/>

2. Compared to one year ago, how would you rate your health in general now?

Much better now than one year ago	Somewhat better now than one year ago	About the same as one year ago	Somewhat worse now than one year ago	Much worse now than one year ago
<input type="checkbox"/>	<input type="checkbox"/>	<input type="checkbox"/>	<input type="checkbox"/>	<input type="checkbox"/>

3. The following questions are about activities you might do during a typical day. Does your health now limit you in these activities? If so, how much?

	Yes, limited a lot	Yes, limited a little	No, not limited at all
• Vigorous activities, such as running, lifting heavy objects, participating in strenuous sports	<input type="checkbox"/>	<input type="checkbox"/>	<input type="checkbox"/>
• Moderate activities, such as moving a table, pushing a vacuum cleaner, bowling, or playing golf	<input type="checkbox"/>	<input type="checkbox"/>	<input type="checkbox"/>
• Lifting or carrying groceries	<input type="checkbox"/>	<input type="checkbox"/>	<input type="checkbox"/>
• Climbing several flights of stairs	<input type="checkbox"/>	<input type="checkbox"/>	<input type="checkbox"/>
• Climbing one flight of stairs	<input type="checkbox"/>	<input type="checkbox"/>	<input type="checkbox"/>
• Bending, kneeling, or stooping	<input type="checkbox"/>	<input type="checkbox"/>	<input type="checkbox"/>
• Walking more than a mile	<input type="checkbox"/>	<input type="checkbox"/>	<input type="checkbox"/>
• Walking several hundred yards	<input type="checkbox"/>	<input type="checkbox"/>	<input type="checkbox"/>
• Walking one hundred yards	<input type="checkbox"/>	<input type="checkbox"/>	<input type="checkbox"/>
• Bathing or dressing yourself	<input type="checkbox"/>	<input type="checkbox"/>	<input type="checkbox"/>

SF-36v2™ Health Survey © 1996, 2000 by QualityMetric Incorporated and Medical Outcomes Trust. All Rights Reserved. SF-36v2 is a registered trademark of Medical Outcomes Trust. (SF-36v2 Standard, US Version 2.0)

SF-36v2™ Health Survey © 1996, 2000 by QualityMetric Incorporated and Medical Outcomes Trust. All Rights Reserved. SF-36v2 is a registered trademark of Medical Outcomes Trust. (SF-36v2 Standard, US Version 2.0)

Fig. 79 c. SF-36v2 Standard

4. During the past 4 weeks, how much of the time have you had any of the following problems with your work or other regular daily activities as a result of your physical health?

All of the time	Most of the time	Some of the time	A little of the time	None of the time
-----------------	------------------	------------------	----------------------	------------------

- Cut down on the amount of time you spent on work or other activities.....
- Accomplished less than you would like.....
- Were limited in the kind of work or other activities.....
- Had difficulty performing the work or other activities (for example, it took extra effort).....

5. During the past 4 weeks, how much of the time have you had any of the following problems with your work or other regular daily activities as a result of any emotional problems (such as feeling depressed or anxious)?

All of the time	Most of the time	Some of the time	A little of the time	None of the time
-----------------	------------------	------------------	----------------------	------------------

- Cut down on the amount of time you spent on work or other activities.....
- Accomplished less than you would like.....
- Did work or other activities less carefully than usual.....

6. During the past 4 weeks, to what extent has your physical health or emotional problems interfered with your normal social activities with family, friends, neighbors, or groups?

Not at all	Slightly	Moderately	Quite a bit	Extremely
------------	----------	------------	-------------	-----------

7. How much bodily pain have you had during the past 4 weeks?

None	Very mild	Mild	Moderate	Severe	Very Severe
------	-----------	------	----------	--------	-------------

8. During the past 4 weeks, how much did pain interfere with your normal work (including both work outside the home and housework)?

Not at all	A little bit	Moderately	Quite a bit	Extremely
------------	--------------	------------	-------------	-----------

9. These questions are about how you feel and how things have been with you during the past 4 weeks. For each question, please give the one answer that comes closest to the way you have been feeling. How much of the time during the past 4 weeks...

	All of the time	Most of the time	Some of the time	A little of the time	None of the time
Did you feel full of life?	<input type="radio"/>	<input type="radio"/>	<input type="radio"/>	<input type="radio"/>	<input type="radio"/>
Have you been very nervous?	<input type="radio"/>	<input type="radio"/>	<input type="radio"/>	<input type="radio"/>	<input type="radio"/>
Have you felt so down in the dumps that nothing could cheer you up?	<input type="radio"/>	<input type="radio"/>	<input type="radio"/>	<input type="radio"/>	<input type="radio"/>
Have you felt calm and peaceful?	<input type="radio"/>	<input type="radio"/>	<input type="radio"/>	<input type="radio"/>	<input type="radio"/>
Did you have a lot of energy?	<input type="radio"/>	<input type="radio"/>	<input type="radio"/>	<input type="radio"/>	<input type="radio"/>
Have you felt downhearted and depressed?	<input type="radio"/>	<input type="radio"/>	<input type="radio"/>	<input type="radio"/>	<input type="radio"/>
Did you feel worn out?	<input type="radio"/>	<input type="radio"/>	<input type="radio"/>	<input type="radio"/>	<input type="radio"/>
Have you been happy?	<input type="radio"/>	<input type="radio"/>	<input type="radio"/>	<input type="radio"/>	<input type="radio"/>
Did you feel tired?	<input type="radio"/>	<input type="radio"/>	<input type="radio"/>	<input type="radio"/>	<input type="radio"/>

10. During the past 4 weeks, how much of the time has your physical health or emotional problems interfered with your social activities (like visiting friends, relatives, etc.)?

	All of the time	Most of the time	Some of the time	A little of the time	None of the time
	<input type="radio"/>	<input type="radio"/>	<input type="radio"/>	<input type="radio"/>	<input type="radio"/>

ES-36-200 Health Survey © 1996, 2009 by QualityMetric Incorporated and Medical Outcomes Trust. All Rights Reserved. SF-36® is a registered trademark of Medical Outcomes Trust. (SF-36v2 Standard, US Version 2.0)

Fig. 79c (continued)

11. How TRUE or FALSE is each of the following statements for you?

	Definitely true	Mostly true	Don't know	Mostly false	Definitely false
I seem to get sick a little easier than other people	<input type="radio"/>	<input type="radio"/>	<input type="radio"/>	<input type="radio"/>	<input type="radio"/>
I am as healthy as anybody I know	<input type="radio"/>	<input type="radio"/>	<input type="radio"/>	<input type="radio"/>	<input type="radio"/>
I expect my health to get worse	<input type="radio"/>	<input type="radio"/>	<input type="radio"/>	<input type="radio"/>	<input type="radio"/>
My health is excellent	<input type="radio"/>	<input type="radio"/>	<input type="radio"/>	<input type="radio"/>	<input type="radio"/>

THANK YOU FOR COMPLETING THESE QUESTIONS!

ES-36-200 Health Survey © 1996, 2009 by QualityMetric Incorporated and Medical Outcomes Trust. All Rights Reserved. SF-36® is a registered trademark of Medical Outcomes Trust. (SF-36v2 Standard, US Version 2.0)

Your Health and Well-Being

This survey asks for your views about your health. This information will help keep track of how you feel and how well you are able to do your usual activities. *Thank you for completing this survey!*

For each of the following questions, please mark an in the one box that best describes your answer.

1. In general, would you say your health is:

Excellent	Very good	Good	Fair	Poor
<input type="checkbox"/>	<input type="checkbox"/>	<input type="checkbox"/>	<input type="checkbox"/>	<input type="checkbox"/>
<input type="checkbox"/>	<input type="checkbox"/>	<input type="checkbox"/>	<input type="checkbox"/>	<input type="checkbox"/>

2. Compared to one week ago, how would you rate your health in general now?

Much better now than one week ago	Somewhat better now than one week ago	About the same now as one week ago	Somewhat worse now than one week ago	Much worse now than one week ago
<input type="checkbox"/>	<input type="checkbox"/>	<input type="checkbox"/>	<input type="checkbox"/>	<input type="checkbox"/>
<input type="checkbox"/>	<input type="checkbox"/>	<input type="checkbox"/>	<input type="checkbox"/>	<input type="checkbox"/>

SF-36v2 Health Survey © 1996, 2000 by QualityMetric, Incorporated and Medical Outcomes Trust. All Rights Reserved.
SF-36v2 is a registered trademark of Medical Outcomes Trust.
(SF-36v2 Acute, US Version 2.0)

Fig. 79 d. SF-36v2 Acute

3. The following questions are about activities you might do during a typical day. Does your health now limit you in these activities? If so, how much?

	Yes, limited a lot	Yes, limited a little	No, not limited at all
Vigorous activities, such as running, lifting heavy objects, participating in strenuous sports	<input type="checkbox"/>	<input type="checkbox"/>	<input type="checkbox"/>
Moderate activities, such as moving a table, pushing a vacuum cleaner, bowling, or playing golf	<input type="checkbox"/>	<input type="checkbox"/>	<input type="checkbox"/>
Lifting or carrying groceries	<input type="checkbox"/>	<input type="checkbox"/>	<input type="checkbox"/>
Climbing several flights of stairs	<input type="checkbox"/>	<input type="checkbox"/>	<input type="checkbox"/>
Climbing one flight of stairs	<input type="checkbox"/>	<input type="checkbox"/>	<input type="checkbox"/>
Bending, kneeling, or stooping	<input type="checkbox"/>	<input type="checkbox"/>	<input type="checkbox"/>
Walking more than a mile	<input type="checkbox"/>	<input type="checkbox"/>	<input type="checkbox"/>
Walking several hundred yards	<input type="checkbox"/>	<input type="checkbox"/>	<input type="checkbox"/>
Walking one hundred yards	<input type="checkbox"/>	<input type="checkbox"/>	<input type="checkbox"/>
Bathing or dressing yourself	<input type="checkbox"/>	<input type="checkbox"/>	<input type="checkbox"/>

SF-36v2 Health Survey © 1996, 2000 by QualityMetric, Incorporated and Medical Outcomes Trust. All Rights Reserved.
SF-36v2 is a registered trademark of Medical Outcomes Trust.
(SF-36v2 Acute, US Version 2.0)

4. During the past week, have you had any of the following problems with your work or other regular daily activities as a result of your physical health?

- | | | |
|--|--------------------------|--------------------------|
| | Yes | No |
| | ▶ | ▶ |
| • Cut down on the amount of time you spent on work or other activities..... | <input type="checkbox"/> | <input type="checkbox"/> |
| • Accomplished less than you would like | <input type="checkbox"/> | <input type="checkbox"/> |
| • Were limited in the kind of work or other activities..... | <input type="checkbox"/> | <input type="checkbox"/> |
| • Had difficulty performing the work or other activities (for example, it took extra effort) | <input type="checkbox"/> | <input type="checkbox"/> |

5. During the past week, have you had any of the following problems with your work or other regular daily activities as a result of any emotional problems (such as feeling depressed or anxious)?

- | | | |
|---|--------------------------|--------------------------|
| | Yes | No |
| | ▶ | ▶ |
| • Cut down on the amount of time you spent on work or other activities..... | <input type="checkbox"/> | <input type="checkbox"/> |
| • Accomplished less than you would like | <input type="checkbox"/> | <input type="checkbox"/> |
| • Did work or other activities less carefully than usual..... | <input type="checkbox"/> | <input type="checkbox"/> |

6. During the past week, to what extent has your physical health or emotional problems interfered with your normal social activities with family, friends, neighbors, or groups?

- | | | | | | |
|--|--------------------------|--------------------------|--------------------------|--------------------------|--------------------------|
| | Not at all | Slightly | Moderately | Quite a bit | Extremely |
| | ▶ | ▶ | ▶ | ▶ | ▶ |
| | <input type="checkbox"/> | <input type="checkbox"/> | <input type="checkbox"/> | <input type="checkbox"/> | <input type="checkbox"/> |

7. How much bodily pain have you had during the past week?

- | | | | | | | |
|--|--------------------------|--------------------------|--------------------------|--------------------------|--------------------------|--------------------------|
| | None | Very mild | Mild | Moderate | Severe | Very Severe |
| | ▶ | ▶ | ▶ | ▶ | ▶ | ▶ |
| | <input type="checkbox"/> | <input type="checkbox"/> | <input type="checkbox"/> | <input type="checkbox"/> | <input type="checkbox"/> | <input type="checkbox"/> |

8. During the past week, how much did pain interfere with your normal work (including both work outside the home and housework)?

- | | | | | | |
|--|--------------------------|--------------------------|--------------------------|--------------------------|--------------------------|
| | Not at all | A little bit | Moderately | Quite a bit | Extremely |
| | ▶ | ▶ | ▶ | ▶ | ▶ |
| | <input type="checkbox"/> | <input type="checkbox"/> | <input type="checkbox"/> | <input type="checkbox"/> | <input type="checkbox"/> |

9. These questions are about how you feel and how things have been with you during the **past week**. For each question, please give the one answer that comes closest to the way you have been feeling. How much of the time during the **past week**...

	All of the time	Most of the time	A good bit of the time	Some of the time	A little of the time	None of the time
• Did you feel full of pep?	<input type="checkbox"/>	<input type="checkbox"/>	<input type="checkbox"/>	<input type="checkbox"/>	<input type="checkbox"/>	<input type="checkbox"/>
• Have you been a very nervous person?	<input type="checkbox"/>	<input type="checkbox"/>	<input type="checkbox"/>	<input type="checkbox"/>	<input type="checkbox"/>	<input type="checkbox"/>
• Have you felt so down in the dumps that nothing could cheer you up?	<input type="checkbox"/>	<input type="checkbox"/>	<input type="checkbox"/>	<input type="checkbox"/>	<input type="checkbox"/>	<input type="checkbox"/>
• Have you felt calm and peaceful?	<input type="checkbox"/>	<input type="checkbox"/>	<input type="checkbox"/>	<input type="checkbox"/>	<input type="checkbox"/>	<input type="checkbox"/>
• Did you have a lot of energy?	<input type="checkbox"/>	<input type="checkbox"/>	<input type="checkbox"/>	<input type="checkbox"/>	<input type="checkbox"/>	<input type="checkbox"/>
• Have you felt downhearted and blue?	<input type="checkbox"/>	<input type="checkbox"/>	<input type="checkbox"/>	<input type="checkbox"/>	<input type="checkbox"/>	<input type="checkbox"/>
• Did you feel worn out?	<input type="checkbox"/>	<input type="checkbox"/>	<input type="checkbox"/>	<input type="checkbox"/>	<input type="checkbox"/>	<input type="checkbox"/>
• Have you been a happy person?	<input type="checkbox"/>	<input type="checkbox"/>	<input type="checkbox"/>	<input type="checkbox"/>	<input type="checkbox"/>	<input type="checkbox"/>
• Did you feel tired?	<input type="checkbox"/>	<input type="checkbox"/>	<input type="checkbox"/>	<input type="checkbox"/>	<input type="checkbox"/>	<input type="checkbox"/>

10. During the **past week**, how much of the time has your **physical health or emotional problems** interfered with your social activities (like visiting friends, relatives, etc.)?

	All of the time	Most of the time	Some of the time	A little of the time	None of the time
<input type="checkbox"/>	<input type="checkbox"/>	<input type="checkbox"/>	<input type="checkbox"/>	<input type="checkbox"/>	<input type="checkbox"/>

SF-36 Health Survey © 1988, 2002 by Medical Outcomes Trust and QualityMetric Incorporated. All Rights Reserved.
SF-36® is a registered trademark of Medical Outcomes Trust.
(SF-36 Acute, US Version 1.0)

Fig. 79d (continued)

11. How **TRUE** or **FALSE** is each of the following statements for you?

	Definitely true	Mostly true	Don't know	Mostly false	Definitely false
• I seem to get sick a little easier than other people	<input type="checkbox"/>	<input type="checkbox"/>	<input type="checkbox"/>	<input type="checkbox"/>	<input type="checkbox"/>
• I am as healthy as anybody I know	<input type="checkbox"/>	<input type="checkbox"/>	<input type="checkbox"/>	<input type="checkbox"/>	<input type="checkbox"/>
• I expect my health to get worse	<input type="checkbox"/>	<input type="checkbox"/>	<input type="checkbox"/>	<input type="checkbox"/>	<input type="checkbox"/>
• My health is excellent	<input type="checkbox"/>	<input type="checkbox"/>	<input type="checkbox"/>	<input type="checkbox"/>	<input type="checkbox"/>

Thank you for completing these questions!

SF-36® Health Survey © 1988, 2002 by Medical Outcomes Trust and QualityMetric Incorporated. All Rights Reserved.
SF-36® is a registered trademark of Medical Outcomes Trust.
(SF-36 Acute, US Version 1.0)

similar information for the SF-12 Health Survey, an even shorter version constructed from a subset of 12 SF-36 items.

One of the most complete independent accounts of the development of the SF-36 along with a critical commentary is offered by McDowell and Newell (1996). More recently, the SF-36 was judged to be the most widely evaluated generic patient assessed health outcome measure in a bibliographic study of the growth of “quality of life” measures published in the *British Medical Journal* (Garratt et al. 2002). Additional information about the SF-36 literature and a community forum for discussing old and new publications and the interpretation of results are available on the SF-36 web page (<http://www.sf-36.com>).

The usefulness of the SF-36 in estimating disease burden and comparing disease-specific benchmarks with general population norms is illustrated in articles describing more than 200 diseases and conditions. Among the most frequently studied diseases and conditions, with 50 or more SF-36 publications each, are: arthritis, back pain, cancer, cardiovascular disease, chronic obstructive pulmonary disease, depression, diabetes, gastro-intestinal disease, migraine headache, HIV/aids, hypertension, irritable bowel syndrome, kidney disease, low back pain, multiple sclerosis, musculoskeletal conditions, neuromuscular conditions, osteoarthritis, psychiatric diagnoses, rheumatoid arthritis, sleep disorders, spinal injuries, stroke, substance abuse, surgical procedures, transplantation, and trauma (Turner-Bowker et al. 2002).

Translations of the SF-36 have been the subject of more than 500 publications involving investigators in 22 countries. Ten or more studies have been published from 13 countries.

Construction of the SF-36

The SF-36 was constructed to satisfy minimum psychometric standards necessary for group comparisons. The eight health concepts were selected from 40 included in the Medical Outcomes Study (MOS) (Stewart and Ware 1992). Those chosen represent the most frequently measured concepts in widely-used health surveys and those most affected by disease and treatment (Ware et al. 1993; Ware 1995). The questionnaire items selected also represent multiple operational indicators of health,

including: behavioural function and dysfunction, distress and well-being, objective reports and subjective ratings, and both favourable and unfavourable self-evaluations of general health status (Ware et al. 1993).

Most SF-36 items have their roots in instruments that have been in use since the 1970s and 1980s (Stewart & Ware 1992), including items from: the General Psychological Well-Being Inventory (GPWBI) (Dupuy 1984); various physical and role functioning measures (Patrick et al. 1973; Hulka & Cassel 1973; Reynolds et al. 1974; Stewart et al. 1981); the Health Perceptions Questionnaire (HPQ) (Ware 1976); and other measures that proved to be useful during the Health Insurance Experiment (HIE) (Brook et al. 1979). MOS researchers selected and adapted questionnaire items from these and other sources, and developed new measures for a 149-item Functioning and Well-Being Profile (FWBP) (Stewart and Ware 1992). The FWBP was the source for questionnaire items and instructions adapted for use in the SF-36. The SF-36 was first made available in a “developmental” form in 1988 and in “standard” form in 1990 (Ware 1988; Ware and Sherbourne 1992). As documented elsewhere (Ware et al. 1993), the standard form eliminated more than one-fourth of the words contained in MOS versions of the 36 items and also incorporated improvements in item wording, format and scoring.

SF-36v2™ Health Survey (Version 2.0)

In 1996, Version 2.0 of the SF-36 (SF-36v2) (Fig. 79c, d) was introduced, to correct deficiencies identified in the original version. Those improvements, which are documented in the SF-36v2 user’s manual (Ware et al. 2000), were implemented after careful study using both qualitative and quantitative methods. Briefly, the SF-36v2 improvements include:

- Improvements in instructions and questionnaire items to shorten and simplify the wording and make it more familiar and less ambiguous;
- An improved layout for questions and answers in the self-administered forms that makes it easier to read and complete, and that reduces missing responses;
- Greater comparability with translations and cultural adaptations widely-used in the US and in other countries;
- Five-level response choices in place of dichotomous response choices for seven items in the two role functioning scales; and,

- Five-level (in place of six-level) response categories to simplify items in the Mental Health (MH) and Vitality (VT) scales.

SF-36® Health Survey Manual & Interpretation Guide

The SF-36® Health Survey: Manual & Interpretation Guide is a 320-page user's manual that documents the development, scoring, validation & interpretation of the SF-36® health survey. This manual includes general population & disease specific norms for the 8 SF-36® scales, and not the summary measures, which are the subject of another manual (the SF-36 Physical and mental Health Summary Scales: A Manual for Users of Version 1, Second Edition). (SF-36® is a registered trademark of the *Medical Outcomes Trust*.)

19.8 VAS [22, 112]

A sophisticated method has been devised to rate well-being and adapted to rate pathological pain. This technique, known as the linear analog, involves the use of a 10 cm line on a piece of white paper, and represents the continuum of the patient's opinion of the degree of pain. It is explained to the subject that the one extremity of the line represents "as much pain as he can possibly imagine", while the other represents "no pain at all". The subject rates the degree of pain by making a mark on the line. Scale values are then obtained by measuring the distance from zero to that mark.

Revill et al. [112] analysed the reliability of the linear analog as a method of assessment. The VAS depends, firstly, upon visual and motor co-ordination, that is, the ability of the patient to place a mark where he intends to put it. Secondly, there is a presumption that the same rating will be given for the same memory of pain on more than one occasion. A remembered pain sufficiently remote in time may be taken as such a constant stimulus. Finally, the use of drugs such as pethidine could affect both these factors. Their experiments showed that using the linear analog patients can express their opinion relatively accurately by placing a mark where they wish to be. A linear analog for rating pain with 10-, 15-, and 20-cm lines is significantly less variable than a 5-cm line (5 cm had the largest error, as might have been expected when

measuring 0–5 mm). Pethidine had no significant effect on the accuracy or reproducibility of the analog rating.

Visual analog scales are often used in the belief that the measurement continuum produces greater sensitivity than the discrete points of the categorical scale. Several studies have indicated that there is a clear correlation between visual analog scales and categorical scales, but when a visual analog scale alone is used it is unclear what point on the scale represents at least moderate baseline pain intensity.

19.9 Shoulder pain and disability index (SPADI) [113]*

The shoulder pain and disability index (SPADI) was developed to provide a self-administered instrument that would reflect the disability and pain associated with the clinical syndrome of painful shoulder. The SPADI was designed to measure current status and change over time.

Description of the index

The SPADI was developed for use in an outpatient setting. It was designed to measure the impact of shoulder pathology in terms of pain and disability, for both current status and change in status over time.

The initial version of the SPADI consisted of 20 items grouped into pain and disability subscales, items were selected and placed in either the pain or disability subscale by a panel that included three rheumatologists and a physical therapist. The face validity of each subscale was addressed by selecting items that the panel felt reflected pain and disability associated with shoulder problems.

In an effort to improve reliability and validity and to decrease the time required to complete the index, some items were eliminated from each subscale. Items were excluded from the final form of the SPADI if test-retest reliability was low or if correlation with shoulder range of motion on the involved side was low. The pain subscale was reduced from nine to five items and the disability subscale was reduced from 11 to 8 items (Table 21). The SPADI was self-administered and, in its final form, required 5–10 minutes to complete.

Table 21. Shoulder pain and disability index

<i>Pain scale</i>			
How severe is your pain?			Score
1. At its worst no pain _____	Worst pain imaginable	_____	
2. When lying on the involved side? No pain _____	Worst pain imaginable	_____	
3. Reaching for something on a high shelf? No pain _____	Worst pain imaginable	_____	
4. Touching the back of your neck? No pain _____	Worst pain imaginable	_____	
5. Pushing with the involved arm? No pain _____	Worst pain imaginable	_____	
<i>Disability scale</i>			
How much difficulty do you have?			Score
1. Washing your hair? No difficulty _____	So difficult Required help	_____	
2. Washing your back? No difficulty _____	So difficult Required help	_____	
3. Putting on an undershirt or pullover sweater? No difficulty _____	So difficult Required help	_____	
4. Putting on a shirt that buttons down the front? No difficulty _____	So difficult Required help	_____	
5. Putting on your pants? No difficulty _____	So difficult Required help	_____	
6. Placing an object on a high shelf? No difficulty _____	So difficult Required help	_____	

Table 21 (continued)

		Score
7. Carrying a heavy object of 10 pounds?		
No difficulty _____	So difficult Required help	_____
8. Removing something from your back pocket?		
No difficulty _____	So difficult Required help	_____

Scoring system. All items were rated using a visual analog scale. Visual analog scales seem to reflect more closely what the subject actually experiences and are the most widely employed type of scale in the measurement of the pain associated with rheumatic disorders. The visual analog scales used in the SPADI consisted of horizontal lines to which were attached neither numbers nor divisions. Verbal anchors, representing opposite extremes of the dimension being measured, were placed at either end of the line. The patient was instructed to place a mark on the line in the position that best represented his experience during the past week attributable to the shoulder problem.

The SPADI's scoring system was based on the assumption that the severity of pain or disability resulting from shoulder pathology was a function of the number of situations in which pain or disability was experienced as well as the intensity of that experience in each situation. A numeric score was calculated for each item by arbitrarily dividing the horizontal line into 12 segments of equal length. A number ranging from 0 to 11 was attached to this segment to produce a score for each item. The subscale scores were calculated by adding the item scores for that subscale and dividing this number by the maximum score possible for the items that were deemed applicable by the subject. This number was then multiplied by 100. Any item marked by the patient as not applicable was not included in the maximum possible score. If a subject marked more than two items not applicable, no score was calculated. Therefore, scores could theoretically range from 0 to 100 with higher scores indicating greater impairment. The total SPADI score was calcu-

lated by averaging the pain and disability subscale scores. Thus, the total SPADI score could also range from 0 to 100.

The SPADI appears to have functioned well in a patient population that consisted primarily of older men. The degree to which these results can be generalized to women and younger individuals with shoulder problems remains to be fully demonstrated.

The SPADI is an easily self-administered clinical Index. Unlike goniometry, it need not be administered by a trained clinician. Patients must be instructed in the proper use of the SPADI. After the initial training session, however, most patients can complete the SPADI without further assistance. Therefore, the SPADI could be administered by mail and used to monitor a patient's progress at home.

The SPADI demonstrates good internal consistency, test-retest reliability, and criterion and construct validity. It also appears to be able to detect change in patient status over time. The SPADI should therefore prove to be a useful Instrument both in clinical practice and in clinical research.

19.10 Self-administered questionnaire for assessment of symptoms and function of the shoulder according to L'Insalata et al. [74]*

Questionnaires validated for assessment of general health status may not be specific enough to provide an accurate, comprehensive description of symptoms and function of an individual joint. The purpose of this paper is to present a self-administered questionnaire designed to assess symptoms and function of the shoulder and to report the results of a prospective evaluation of its validity, reliability, and responsiveness to clinical change.

Development of the questionnaire

A preliminary questionnaire was developed and was completed by thirty patients who were being managed for disorders related to the shoulder. A subset of these patients was interviewed, and each question was assessed for clinical relevance, relative importance, and ease of completion

and grading. This allowed modifications to be made to produce the revised questionnaire that was prospectively assessed. After this assessment, questions that had poor reliability, substantially reduced the total or subset internal consistency, or contributed little to the clinical sensitivity of the over-all instrument were eliminated to produce the current questionnaire.

The Shoulder Rating Questionnaire includes six separately scored domains: global assessment, pain, daily activities, recreational and athletic activities, work, and satisfaction (Table 22). A final, nongraded domain allows the patient to select two areas in which he or she believes improvement is most important (Table 22).

The global assessment domain (Question 1) consists of a 10-cm long visual analog scale. A visual analog scale is a straight line, the ends of which are defined as the extreme limits of the response or sensation to be measured. In this case, the scale is from 0 (very poorly) to 10 (very well), with interval scores measured in millimetres between 0 and the mark made by the patient.

Each of the other scored domains consists of a series of multiple-choice questions with five selections scored from 1 (poorest) to 5 (best). Each domain is scored separately by averaging the scores of the completed questions and multiplying by two. Thus, the possible score for each domain ranges from 2 (poorest) to 10 (best).

The pain domain consists of four questions that assess the severity of pain at rest (Question 2) and during activities (Question 3), the frequency of pain that interferes with sleep (Question 4), and the frequency of severe pain (Question 5).

The daily activities domain consists of six questions, including one that requires a general assessment of the limitation of daily activities (Question 6) and a series of questions that assess difficulty with typical daily activities, such as putting on or removing a pullover shirt, combing hair, reaching shelves above the head, scratching or washing the lower back, and carrying groceries (Questions 7 to 11).

The recreational and athletic activities domain consists of three questions. One asks for a general assessment of limitation during recreational and athletic activities (Question 12), another requires an assessment of the degree of difficulty in throwing a ball overhand or serving in tennis (Question 13), and the third allows the patient to select an ac-

Table 22. Shoulder-rating questionnaire

Which is your dominant arm?

Left Right

For which shoulder(s) have you been evaluated or treated?

Left Right Both

Please answer the following questions regarding the shoulder for which you have been evaluated or treated. If a question does not apply to you, leave that question blank. If you indicated that both shoulders have been evaluated or treated, please complete a separate questionnaire for each shoulder and mark the corresponding side (left or right) at the top of each form.

1. Considering all the ways that your shoulder affects you, mark X on the scale below for how well you are doing
Very poorly _____ Very well

The following questions refer to *pain*.

2. During the past month, how would you describe the usual pain in your shoulder *at rest*?
 - A) Very severe
 - B) Severe
 - C) Moderate
 - D) Mild
 - E) None
3. During the past month, how would you describe the usual pain in your shoulder *during activities*?
 - A) Very severe
 - B) Severe
 - C) Moderate
 - D) Mild
 - E) None
4. During the past month, how often did the pain in your shoulder make it *difficult for you to sleep* at night?
 - A) Every day
 - B) Several days per week
 - C) One day per week
 - D) Less than 1 day per week
 - E) Never
5. During the past month, how often have you had *severe pain* in your shoulder?
 - A) Every day
 - B) Several days per week
 - C) One day per week
 - D) Less than 1 day per week
 - E) Never

Table 22 (continued)

The following questions refer to *daily activities*.

6. Considering all the ways you use your shoulder during *daily personal and household activities* (i.e., dressing, washing, driving, household chores, etc.), how would you describe your ability to use your shoulder?
 - A) Very severe limitation; unable
 - B) Severe limitation
 - C) Moderate limitation
 - D) Mild limitation
 - E) No limitation

Questions 7–11: During the past month, how much difficulty have you had in each of the following activities *due to your shoulder*?

7. Putting on or removing a pullover sweater or shirt.
 - A) Unable
 - B) Severe difficulty
 - C) Moderate difficulty
 - D) Mild difficulty
 - E) No difficulty
8. Combing or brushing
 - A) Unable
 - B) Severe difficulty
 - C) Moderate difficulty
 - D) Mild difficulty
 - E) No difficulty
9. Reaching shelves that are above your head
 - A) Unable
 - B) Severe difficulty
 - C) Moderate difficulty
 - D) Mild difficulty
 - E) No difficulty
10. Scratching or washing your lower back with your hand
 - A) Unable
 - B) Severe difficulty
 - C) Moderate difficulty
 - D) Mild difficulty
 - E) No difficulty
11. Lifting or carrying a full bag of groceries [8–10 lbs (3.6–4.5 kg)].
 - A) Unable
 - B) Severe difficulty
 - C) Moderate difficulty
 - D) Mild difficulty
 - E) No difficulty

Table 22 (continued)

The following questions refer to *recreational or athletic activities*.

12. Considering all the ways you use your shoulder *during recreational or athletic activities* (i.e., baseball, golf, aerobics, gardening, etc.), how would you describe the function of your shoulder?
- A) Very severe limitation; unable
 - B) Severe limitation
 - C) Moderate limitation
 - D) Mild limitation
 - E) No limitation
13. During the past month, how much difficulty have you had *throwing a ball overhand or serving in tennis* due to your shoulder?
- A) Unable
 - B) Severe difficulty
 - C) Moderate difficulty
 - D) Mild difficulty
 - E) No difficulty
14. List one activity (recreational or athletic) that you particularly enjoy and then select the degree of limitation you have, if any, *due to your shoulder*.
- Activity _____
- A) Unable
 - B) Severe limitation
 - C) Moderate limitation
 - D) Mild limitation
 - E) No limitation

The following questions refer to *work*.

15. During the past month, what has been your main form of work?
- A) Paid work (list type) _____
 - B) Housework
 - C) Schoolwork
 - D) Unemployed
 - E) Disabled due to your shoulder
 - F) Disabled secondary to other causes
 - G) Retired

If you answered D, E, F, or G to the above question, please skip questions 16–19 and go on to question 20.

Table 22 (continued)

16. During the past month, how often were you *unable* to do *any* of your usual work because of your shoulder?
 - A) All days
 - B) Several days per week
 - C) One day per week
 - D) Less than 1 day per week
 - E) Never
 17. During the past month, on the days that you did work, how often were you unable to do your work as *carefully* or as *efficiently* as you would like because of your shoulder?
 - A) All days
 - B) Several days per week
 - C) One day per week
 - D) Less than 1 day per week
 - E) Never
 18. During the past month, on the days that you did work, how often did you have to work a *shorter day* because of your shoulder?
 - A) All days
 - B) Several days per week
 - C) One day per week
 - D) Less than 1 day per week
 - E) Never
 19. During the past month, on the days that you did work, how often did you have to change the way that your *usual work* is done because of your shoulder?
 - A) All days
 - B) Several days per week
 - C) One day per week
 - D) Less than 1 day per week
 - E) Never
- The following questions refer to *satisfaction* and *areas for improvement*.
20. During the past month, how would you rate your overall degree of satisfaction with your shoulder?
 - A) Poor
 - B) Fair
 - C) Good
 - D) Very good
 - E) Excellent

Table 22 (continued)

21. Please rank the two areas in which you would most like to see *improvement* (place a 1 for the most important, a 2 for the second most important).

Pain _____

Daily personal and household activities _____

Recreational or athletic activities _____

Work _____

This is the end of the shoulder-rating questionnaire.

Thank you for your cooperation.

tivity that he or she particularly enjoys and to assess his or her limitation in that activity (Question 14).

The work domain includes a nongraded question that categorizes the form of work (Question 15) and four graded questions that assess the frequency of inability to do any work (Question 16), inability to work efficiently (Question 17), and the need to work a shorter day (Question 18) or to change the manner in which usual work is performed (Question 19).

The satisfaction domain (Question 20) consists of a single question that asks the patient to grade his or her over-all satisfaction from poor to excellent. This domain is not included in the total score but rather is scored and presented separately.

Finally, the importance domain (Question 21) allows the patient to rank the two areas in which he or she most desires improvement. These are rated 1, for most important, and 2, for second most important. This does not contribute to the total score but can be used with the scores of the individual domains to determine if substantial improvement has occurred in the areas most important to the patient or to individualize the weighting method used to determine the over-all score.

A suggested weighting system for the calculation of a total score was developed after consultation with several shoulder surgeons and patients regarding the relative importance of each of the domains. The maximum score was 15 points for global assessment (domain score multiplied by 1.5; score range, 0 to 15 points), 40 points for pain (domain score multiplied by four; score range, 8 to 40 points), 20 points for daily activities (domain score multiplied by two; score range, 4 to 20 points),

15 points for recreational and athletic activities (domain score multiplied by 1.5; score range, 3 to 15 points), and 10 points for work (domain score multiplied by one; score range, 2 to 10 points). Therefore, the total possible score ranged from 17 to 100 points.

19.11 "Oxford" questionnaire on the perceptions of patients about shoulder surgery [27]*

Development of the questionnaire. Initially, the authors interviewed 20 patients attending an outpatient shoulder clinic to identify how they experienced and reported problems with their shoulders. From these results and from established questionnaires, the authors drafted a 22-item questionnaire and tested it on 20 new patients. They were also given a second copy of the questionnaire, and asked to complete it at home on the following day and return it in a prepaid envelope. They were invited to add their comments to this copy and to include any further shoulder problems which were not addressed by it.

It became clear that there was a distinct group of patients with a tendency towards recurrent dislocation or subluxation of the shoulder. They were characterised by the anticipation of problems arising in relation to very specific activities. The authors excluded this group from the study in order to concentrate on patients presenting with a painful shoulder related to a degenerative or inflammatory condition.

The original questionnaire was modified after the pilot study and the revised version was tested on two further groups of patients until its final form was established. This contains 12 items, each of which has five response categories (Fig. 80). Each item is scored from 1 to 5, from least to most difficulty or severity, and combined to produce a single score with a range from 12 (least difficulties) to 60 (most difficulties).

The authors have developed and tested a short 12-item questionnaire which patients find easy to complete and which provides reliable, valid and responsive data regarding their perception of shoulder problems. It is intended for use as an outcome measure during specialist treatment and imposes very little burden on the patients. Few reported any difficulties in completing it.

OXFORD SHOULDER SCORE

RIGHT LEFT

Problems with your shoulder

During the past 4 weeks...

✓ tick one box for each question

<p>1 During the past 4 weeks ...</p> <p>How would you describe the <u>worst</u> pain you had <i>from your shoulder</i>?</p>	None	Mild	Moderate	Severe	Unbearable
	<input type="checkbox"/>	<input type="checkbox"/>	<input type="checkbox"/>	<input type="checkbox"/>	<input type="checkbox"/>
<p>2 During the past 4 weeks ...</p> <p>Have you had any trouble dressing yourself <i>because of your shoulder</i>?</p>	No trouble at all	A little bit of trouble	Moderate trouble	Extreme difficulty	Impossible to do
	<input type="checkbox"/>	<input type="checkbox"/>	<input type="checkbox"/>	<input type="checkbox"/>	<input type="checkbox"/>
<p>3 During the past 4 weeks ...</p> <p>Have you had any trouble getting in and out of a car or using public transport <i>because of your shoulder</i>?</p>	No trouble at all	A little bit of trouble	Moderate trouble	Extreme difficulty	Impossible to do
	<input type="checkbox"/>	<input type="checkbox"/>	<input type="checkbox"/>	<input type="checkbox"/>	<input type="checkbox"/>
<p>4 During the past 4 weeks ...</p> <p>Have you been able to use a knife and fork – <i>at the same time</i>?</p>	Yes, easily	With little difficulty	With moderate difficulty	With extreme difficulty	No, impossible
	<input type="checkbox"/>	<input type="checkbox"/>	<input type="checkbox"/>	<input type="checkbox"/>	<input type="checkbox"/>
<p>5 During the past 4 weeks ...</p> <p>Could you do the household shopping <i>on your own</i>?</p>	Yes, easily	With little difficulty	With moderate difficulty	With extreme difficulty	No, impossible
	<input type="checkbox"/>	<input type="checkbox"/>	<input type="checkbox"/>	<input type="checkbox"/>	<input type="checkbox"/>
<p>6 During the past 4 weeks ...</p> <p>Could you carry a tray containing a plate of food across a room?</p>	Yes, easily	With little difficulty	With moderate difficulty	With extreme difficulty	No, impossible
	<input type="checkbox"/>	<input type="checkbox"/>	<input type="checkbox"/>	<input type="checkbox"/>	<input type="checkbox"/>

Fig. 80. Oxford Shoulder Score

Oxford Shoulder Score

7	During the past 4 weeks ... Could you brush/comb your hair <i>with the affected arm</i>?	Yes, Easily	With little difficulty	With moderate difficulty	With extreme difficulty	No, impossible
		<input type="checkbox"/>	<input type="checkbox"/>	<input type="checkbox"/>	<input type="checkbox"/>	<input type="checkbox"/>
8	During the past 4 weeks ... How would you describe the pain you <i>usually</i> had from your shoulder?	None	Very mild	Mild	Moderate	Severe
		<input type="checkbox"/>	<input type="checkbox"/>	<input type="checkbox"/>	<input type="checkbox"/>	<input type="checkbox"/>
9	During the past 4 weeks ... Could you hang your clothes up in a wardrobe, – <i>using the affected arm</i>?	Yes, easily	With little difficulty	With moderate difficulty	With great difficulty	No, impossible
		<input type="checkbox"/>	<input type="checkbox"/>	<input type="checkbox"/>	<input type="checkbox"/>	<input type="checkbox"/>
10	During the past 4 weeks ... Have you been able to wash and dry yourself under both arms?	Yes, easily	With little difficulty	With moderate difficulty	With extreme difficulty	No, impossible
		<input type="checkbox"/>	<input type="checkbox"/>	<input type="checkbox"/>	<input type="checkbox"/>	<input type="checkbox"/>
11	During the past 4 weeks ... How much has <i>pain from your shoulder</i> interfered with your usual work (including housework)?	Not at all	A little bit	Moderately	Greatly	Totally
		<input type="checkbox"/>	<input type="checkbox"/>	<input type="checkbox"/>	<input type="checkbox"/>	<input type="checkbox"/>
12	During the past 4 weeks ... Have you been troubled by <i>pain from your shoulder</i> in bed at night?	No nights	Only 1 or 2 nights	Some nights	Most nights	Every night
		<input type="checkbox"/>	<input type="checkbox"/>	<input type="checkbox"/>	<input type="checkbox"/>	<input type="checkbox"/>



The finding that the questionnaire is unsuitable for patients with shoulder instability is not surprising and a similar experience has been reported with the Constant shoulder score (MacDonald 1993).

The shoulder questionnaire provides a measure of outcome for shoulder operations which is short, practical, reliable, valid and sensitive to clinically important changes.

19.12 Oxford shoulder instability questionnaire [26]*

Instability of the shoulder poses particular problems for assessment as symptoms are often intermittent, and characterised less by the everyday presence of pain than by the anticipation of problems arising in relation to specific activities.

Development of the questionnaire. Initially, the authors interviewed 20 patients attending an outpatient clinic to which they had been referred with instability of their shoulder, in order to identify ways in which they had experienced and reported their problem. The authors then drafted an 18-item questionnaire and tested it on 20 new patients. They were also given a second copy of the questionnaire and asked to complete it at home on the following day, and to return it. They were invited to add their comments to this copy and to include any further shoulder problems which were not addressed by it.

The original questionnaire was then modified and the revised version tested on two further groups of 20 patients until its final form was established. This contained 12 items, each of which had five response categories (Fig. 81). Each item was scored from 1 to 5, from least to most difficulty or severity and combined to produce a single score with a range from 12 (least difficulties) to 60 (most difficulties).

The authors have developed and tested a short 12-item questionnaire which patients have found easy to complete and which provides reliable, valid and responsive information as to their perception of shoulder instability. It is intended for use as an outcome measure, and poses few difficulties for the patients. The items are internally consistent and reproducible, and therefore the questionnaire may be considered to be at least as reliable as clinical scores used to assess outcomes.

OXFORD SHOULDER INSTABILITY SCORERIGHT **Problems with your shoulder**LEFT

✓ tick one box for each question

1	During the last 6 months ... how many times has your shoulder slipped out of joint (or dislocated)?	Not at all in 6 months	1 or 2 times in 6 months	1 or 2 times per month	1 or 2 times per week	More often than 1 or 2 times/week
		<input type="checkbox"/>	<input type="checkbox"/>	<input type="checkbox"/>	<input type="checkbox"/>	<input type="checkbox"/>
2	During the last 3 months ... have you had any trouble (or worry) with putting on a T-shirt or pullover <i>because of your shoulder?</i>	No trouble/ no worries	Slight trouble or worry	Moderate trouble or worry	Extreme difficulty	Impossible to do
		<input type="checkbox"/>	<input type="checkbox"/>	<input type="checkbox"/>	<input type="checkbox"/>	<input type="checkbox"/>
3	During the last 3 months ... how would you describe the <u>worst</u> pain you have had from your shoulder?	None	Mild ache	Moderate	Severe	Unbearable
		<input type="checkbox"/>	<input type="checkbox"/>	<input type="checkbox"/>	<input type="checkbox"/>	<input type="checkbox"/>
4	During the last 3 months ... how much has <i>the problem with your shoulder</i> interfered with your usual work? (including school or college work, or housework)	Not at all	A little bit	Moderately	Greatly	Totally
		<input type="checkbox"/>	<input type="checkbox"/>	<input type="checkbox"/>	<input type="checkbox"/>	<input type="checkbox"/>
5	During the last 3 months ... have you avoided any activities due to <i>worry about your shoulder</i> – feared that it might slip out of joint?	No, not at all	Very occasionally	Some days	Most days or more than one activity	Every day or many activities
		<input type="checkbox"/>	<input type="checkbox"/>	<input type="checkbox"/>	<input type="checkbox"/>	<input type="checkbox"/>
6	During the last 3 months ... has <i>the problem with your shoulder</i> prevented you from doing things that are important to you?	No, not at all	Very occasionally	Some days	Most days or more than one activity	Every day or many activities
		<input type="checkbox"/>	<input type="checkbox"/>	<input type="checkbox"/>	<input type="checkbox"/>	<input type="checkbox"/>

Fig. 81. Oxford Shoulder Instability Score

Oxford Instability Shoulder Score

7	During the last 3 months ... how much has <i>the problem with your shoulder</i> interfered with your social life? (including sexual activity – if applicable)	Not at all	Occasionally	Some days	Most days	Every day
		<input type="checkbox"/>	<input type="checkbox"/>	<input type="checkbox"/>	<input type="checkbox"/>	<input type="checkbox"/>
8	During the last 4 weeks ... how much has <i>the problem with your shoulder</i> interfered with your sporting activities or hobbies?	Not at all	A little/ occasionally	Some of the time	Most of the time	All of the time
		<input type="checkbox"/>	<input type="checkbox"/>	<input type="checkbox"/>	<input type="checkbox"/>	<input type="checkbox"/>
9	During the last 4 weeks ... how often has your shoulder been 'on your mind' – how often have you thought about it?	Never, or only if someone asks	Occasionally	Some days	Most days	Every day
		<input type="checkbox"/>	<input type="checkbox"/>	<input type="checkbox"/>	<input type="checkbox"/>	<input type="checkbox"/>
10	During the last 4 weeks ... how much has <i>the problem with your shoulder</i> interfered with your ability – or willingness – to lift heavy objects?	Not at all	Occasionally	Some days	Most days	Every day
		<input type="checkbox"/>	<input type="checkbox"/>	<input type="checkbox"/>	<input type="checkbox"/>	<input type="checkbox"/>
11	During the last 4 weeks ... how would you describe the pain you <i>usually</i> had from your shoulder?	None	Very mild	Mild	Moderate	Severe
		<input type="checkbox"/>	<input type="checkbox"/>	<input type="checkbox"/>	<input type="checkbox"/>	<input type="checkbox"/>
12	During the last 4 weeks ... have you avoided lying in certain positions, in bed at night, <i>because of your shoulder</i> ?	No nights	Only 1 or 2 nights	Some nights	Most nights	Every night
		<input type="checkbox"/>	<input type="checkbox"/>	<input type="checkbox"/>	<input type="checkbox"/>	<input type="checkbox"/>



Nuffield
Department of
Orthopaedic Surgery

Nuffield **NHS**
Orthopaedic Centre
NHS Trust

Fig. 81 (continued)

19.13 Rowe score [116]

The rating sheet (Table 23) was designed for the outcome measurement of Bankart repair.

Table 23. Rating sheet for Bankart repair

Scoring system	Units	Excellent (100–90)	Good (89–75)	Fair (74–51)	Poor (50 or Less)
<i>Stability</i>					
No recurrence, subluxation, or apprehension	50	No recurrences	No recurrences	No recurrences	Recurrence of dislocation or
Apprehension when placing arm in certain positions	30	No apprehension when placing arm in complete elevation and external rotation	Mild apprehension when placing arm in elevation and external rotation	Moderate apprehension during elevation and external rotation	Marked apprehension during elevation or extension
Subluxation (not requiring reduction)	10	No subluxations	No subluxations	No subluxations	
Recurrent dislocation	0				
<i>Motion</i>					
100% of normal external rotation, internal rotation, and elevation	20	100% of normal external rotation; complete elevation and internal rotation	75% of normal external rotation; complete elevation and internal rotation	50% of normal external rotation; 75% of elevation and internal rotation	No external rotation; 50% of elevation (can get hand only to face) and 50% of internal rotation
75% of normal external rotation, and normal elevation and internal rotation	15				

Table 23 (continued)

Scoring system	Units	Excellent (100–90)	Good (89–75)	Fair (74–51)	Poor (50 or Less)
50% of normal external rotation and 75% of normal elevation and internal rotation	5				
50% of normal elevation and internal rotation; no external rotation	0				
<i>Function</i>					
No limitation in work or sports; little or no discomfort	30	Performs all work and sports, no limitation in overhead activities;	Mild limitation in work and sports; shoulder strong;	Moderate limitation doing overhead work and heavy lifting; unable to throw, severe hard in tennis, or swim;	Marked limitation; unable to perform overhead work and lifting; cannot throw, play tennis, or swim; chronic discomfort
Mild limitation and minimum discomfort	25	strong in lifting, swimming, tennis, throwing; no discomfort	minimum discomfort		
Moderate limitation and discomfort	10				
Marked limitation and pain	0			moderate disabling pain	
Total units possible	100				

19.14 The modified Rowe Score according to Jobe et al. [64]

The grading system described by Rowe et al. [116] was modified for the use in athletes in overhand sports by including the ability to throw and return to their level of competition as well as subjective assessment of pain, stability, and motion (Table 24).

Table 24. Postoperative grading system

Assessment	Score
<i>Function</i>	
No limitation in throwing or overhand activities; returned to prior level of competition	50
No limitation in overhand activity; returned to preinjury sport but not at preinjury level	40
No limitation in overhand activity and throwing; did not return to preinjury sport	35
Moderate limitation in overhand activity and throwing; could not return to preinjury sport	20
Marked limitation in throwing; unable to work overhand	0
<i>Pain</i>	
None	10
Moderate	5
Severe	0
<i>Stability</i>	
Negative apprehension with no subluxation	30
Negative apprehension with pain during abduction in external rotation	15
Positive apprehension with positive sense of subluxation	0
<i>Motion</i>	
Full	10
Equal to or less than 25% loss in any plane	5
Greater than 25% loss in any plane	0

Excellent: 90–100 points; good: 70–89 points; fair: 40–69 points; poor: ≤ 39 points

19.15 The Western Ontario shoulder instability index (WOSI) [70] *

The purpose of this study was to develop a valid, reliable, and responsive measurement tool for patients with shoulder instability. Since it is the patient's subjective impression of his or her function that is most important to the success of a treatment, it was decided that a disease-specific quality of life measurement tool was most appropriate. This in-

SECTION A:
Physical Symptoms

INSTRUCTIONS TO PATIENTS

The following questions concern the physical symptoms you have experienced due to your shoulder problem. In all cases, please enter the amount of the symptom you have experienced in the last week. (Please answer with an "X" on the horizontal line.)

1. How much pain do you experience in your shoulder with overhead activities?

no	extreme
pain	pain
2. How much aching or throbbing do you experience in your shoulder?

no	extreme
aching/ throbbing	aching/ throbbing
3. How much weakness or lack of strength do you experience in your shoulder?

no	extreme
weakness	weakness
4. How much fatigue or lack of stamina do you experience in your shoulder?

no	extreme
fatigue	fatigue
5. How much clicking, cracking or snapping do you experience in your shoulder?

no	extreme
clicking	clicking
6. How much stiffness do you experience in your shoulder?

no	extreme
stiffness	stiffness

† On the actual form the lines are 100-mm long. This form is reproduced by permission of the Fowler - Kennedy Sports Medicine Clinic.

7. How much discomfort do you experience in your neck muscles as a result of your shoulder?

no	extreme
discomfort	discomfort

8. How much feeling of instability or looseness do you experience in your shoulder?

no	extreme
instability	instability

9. How much do you compensate for your shoulder with other muscles?

not	extreme
at all	at all

10. How much loss of range of motion do you have in your shoulder?

no	extreme
loss	loss

SECTION B:
Sports/Recreation/Work

INSTRUCTIONS TO PATIENTS

The following section concerns how your shoulder problem has affected your work, sports or recreational activities in the past week. For each question, please indicate the amount with an "X" on the horizontal line.

11. How much has your shoulder limited the amount you can participate in sports or recreational activities?

not	extremely
limited	limited
12. How much has your shoulder affected your ability to perform the specific skills required for your sport or work? (If your shoulder affects both sports and work, consider the area that is most affected.)

not	extremely
affected	affected

Fig. 82. The Western Ontario Shoulder Instability Index (WOSI)

strument, the Western Ontario shoulder instability index (WOSI), was designed to be used as the primary outcome measure in clinical trials evaluating treatments for patients with shoulder instability.

Development included (1) identification of a specific patient population; (2) generation of issues specific to the "disease" ("items") from reviewing the literature, interviewing health caregivers, and interviewing patients representing all demographics, disease type and severity, and treatments; (3) item reduction using patient-generated frequency-importance

13. How much do you feel the need to protect your arm during activities?

not extreme
at all

14. How much difficulty do you experience lifting heavy objects below shoulder level?

no extreme
difficulty difficulty

SECTION C:
Lifestyle

INSTRUCTIONS TO PATIENTS

The following section concerns the amount that your shoulder problem has affected or changed your lifestyle. Again, please indicate the appropriate amount for the past week with an "X" on the horizontal line.

15. How much fear do you have of falling on your shoulder?

no extreme
fear fear

16. How much difficulty do you experience maintaining your desired level of fitness?

no extreme
difficulty difficulty

17. How much difficulty do you have "roughhousing or horsing around" with family or friends?

no extreme
difficulty difficulty

18. How much difficulty do you have sleeping because of your shoulder?

no extreme
difficulty difficulty

SECTION D:
Emotions

INSTRUCTIONS TO PATIENTS

The following questions relate to how you have felt in the past week with regard to your shoulder problem. Please indicate your answer with an "X" on the horizontal line.

19. How conscious are you of your shoulder?

not extremely
conscious conscious

20. How concerned are you about your shoulder becoming worse?

no extremely
concern concerned

21. How much frustration do you feel because of your shoulder?

no extremely
frustration frustrated

Fig. 82 (continued)

tance products and correlation matrices; and (4) pretesting the prototype instrument on two groups of 10 patients.

The WOSI has 21 items. The first domain, which is physical symptoms, contains 10 items. The remaining domains are sports, recreation, and work (4 items); lifestyle (4 items); and emotions (3 items) (see Fig. 82).

The best score possible is 0, which signifies that the patient has no decrease in shoulder-related quality of life. The worst score possible is 2100. This signifies that the patient has an extreme decrease in shoulder-related quality of life.

The authors have presented a rigorously designed and evaluated measurement tool for patients with shoulder instability. Since the patient's own perception of changes in health status is the most important indicator of the success of a treatment, the authors suggest that this measurement tool should be used as the primary outcome in clinical trials

evaluating treatments in this patient population, although its features are equally attractive for use in monitoring the progress of patients in clinical practice.

19.16 The Walch-Duplay score for instability of the shoulder [133]

In 1987 Walch published a measurement tool for the assessment of anterior instability of the shoulder which is shown in Fig. 83.

19.17 The Western Ontario rotator cuff index (WORC) [69]*

The purpose of the study was to develop a valid and reliable disease-specific quality-of-life measurement tool for patients with rotator cuff disease.

Methodology for the development and evaluation of the tool included the following: (1) identification of a specific patient population. (2) Generation of potential items, (3) item reduction, (4) prototyping the prototype instrument, (5) determination of reliability, and (6) validation.

The WORC consists of 21 items representing five domains pertinent to health-related quality of life (HRQL). There are six questions in the physical symptoms domain, four in the sports and recreation domain, four in the work domain, four in the lifestyle domain, and three in the emotions domain (Fig. 84).

In the final instrument, each item has a possible score from 0 to 100 (100 mm VAS), and these scores are added to give a total score from 0 to 2100. The highest or most symptomatic score is 2100, and the best or asymptomatic score is 0. To present this in a more clinically meaningful format, the score can be reported as a percentage of normal by subtracting the total from 2100, dividing by 2100, and multiplying by 100. For example, a patient with a total score of 1800 would have a percentage score of $(2100-1800)/2100 \times 100 = 14.3\%$.

This measurement tool can be used as the primary outcome in clinical trials evaluating treatments in this patient population, although its

OUT-PATIENT CLINIC**SHOULDER UNIT****The Walch-Duplay Score for Instability of the Shoulder**

Patient's Details

Operation/Diagnosis: _____

Date: _____

Side: R L

Examination: 3 months	1 year
6 months	2 years
	___ years

1.- Level of Sport Practised (please circle):

C = Competition L = Leisure N = Not practising a sport

2.- Type of Sport (please circle):

0 = no sport

1 = risk free athletics, rowing, swimming, breaststroke, underwater diving, voluntary gymnastics, cross-country skiing, shooting, sailing.

2 = with contact martial arts, cycling, motorcycling or biking, scrambling, soccer, rugby, water-skiing, downhill skiing, parachute jumping, horse riding.

3 = with cocking of the arm climbing, weight lifting, shot-putting, swimming overarm and butterfly, pole vaulting, figure skating, canoeing, golf, hockey, tennis, baseball.

4 = high risk basketball, handball, volleyball, hand gliding, kayaking, water polo.

3.- Side (please circle): Right Left D = dominant d = nondominant**ROM**

Abduction: _____ FWF: _____ ER: _____ IR: _____ ER in 90 abduction: _____

POINTS (please circle)**A.- Daily Activity**

Return to same level in the same sport	+25 points	No discomfort
Decrease level in the same sport	+15 points	Slight discomfort in forceful movements
Change in sport	+10 points	Slight discomfort during simple movements
Decrease level and change, or stop sport	0 points	Severe discomfort

B.- Stability

+25 points: No apprehension
 +15 points: Persistent apprehension
 0 points: Feeling of instability
 -25 points: True recurrence

C.- Pain

+25 points: No or pain during certain climatic conditions
 +15 points: Pain during forceful movements or when tired
 0 points: Pain during daily life

D.- Mobility

+25 points: Pure frontal abduction against a wall: symmetrical
 Internal rotation limited to less than three vertebrae
 External rotation at 90 degrees abduction limited to less than 10% of the opposite side.

+15 points: Pure frontal abduction against a wall < 150 degrees
 IR: limited to less than three vertebrae
 ER: limited to less than 30% of the opposite side

+5 points: Pure frontal abduction against a wall < 120 degrees
 IR: limited to less than six vertebrae
 ER: limited to less than 50% of the opposite side

0 points: Pure frontal abduction against a wall < 90 degrees
 IR: limited to more than six vertebrae
 ER: limited to more than 50% of the opposite side

OVERALL

Excellent:	91 to 100 points
Good:	76 to 90 points
Medium:	51 to 75 points
Poor:	50 points or less

TOTAL(/100): A + B + C + D

Fig. 83. Walch-Duplay Score

features are equally attractive for monitoring patients' progress in clinical practice.

THE WESTERN ONTARIO ROTATOR CUFF INDEX (WORC)


Section A: Physical Symptoms INSTRUCTIONS TO PATIENTS

The following questions concern the physical symptoms you have experienced due to your shoulder problem. In all cases, please enter the amount of the symptom you have experienced in the last week. (Please mark your answers with a slash "/")


1. How much sharp pain do you experience in your shoulder?




2. How much constant, nagging pain do you experience in your shoulder?




3. How much weakness do you experience in your shoulder?




4. How much stiffness do you experience in your shoulder?



5. How much clicking, grinding or crunching do you experience in your shoulder?




6. How much discomfort do you experience in your neck because of your shoulder?




SECTION B: Sports/Recreation INSTRUCTIONS TO PATIENTS

The following section concerns how your shoulder problem has affected your sports or recreational activities in the past week. For each question, please mark your answers with a slash "/"


7. How much has your shoulder affected your fitness level?




8. How much has your shoulder affected your ability to throw hard or far?



9. How much difficulty do you have with someone or something coming in contact with your affected shoulder?



10. How much difficulty do you experience doing push-ups or other strenuous shoulder exercises because of your shoulder?




* On the actual form the lines are 100-mm long. This form is reproduced by permission of the Fowler Kennedy Sport Medicine Clinic

Fig. 84. The Western Ontario Rotator Cuff Index (WORC)


SECTION C: Work INSTRUCTIONS TO PATIENTS

The following section concerns the amount that your shoulder problem has affected your work around or outside of the home. Please indicate the appropriate amount for the past week with a slash "/".


11. How much difficulty do you experience in daily activities about the house or yard?




12. How much difficulty do you experience working above your head?



13. How much do you use your uninvolved arm to compensate for your injured one?




14. How much difficulty do you experience lifting heavy objects from the ground or below shoulder level?




SECTION D: Lifestyle INSTRUCTIONS TO PATIENTS

The following section concerns the amount that your shoulder problem has affected or changed your lifestyle. Again, please indicate the appropriate amount for the past week with a slash "/".


15. How much difficulty do you have sleeping because of your shoulder?




16. How much difficulty have you experienced with styling your hair because of your shoulder?



17. How much difficulty do you have "roughhousing or horsing around" with family or friends?




18. How much difficulty do you have dressing or undressing?




SECTION E: Emotions INSTRUCTIONS TO PATIENTS

The following questions relate to how you have felt in the past week with regard to your shoulder problem. Please indicate your answer with a slash "/".

19. How much frustration do you feel because of your shoulder?



20. How "down in the dumps" or depressed do you feel because of your shoulder?



21. How worried or concerned are you about the effect of your shoulder on your occupation or work?




Fig. 84 (continued)

19.18 The rotator cuff quality-of-life measure (RC-QOL) [59]*

Development of the disease-specific RC-QOL

The RC-QOL was developed through a process of item generation, item reduction, pretesting, and test/retest reliability analysis. Items were generated from a thorough review of the literature, discussions with clinicians experienced in the area of rotator cuff disease, and modifications of similar disease-specific quality-of-life outcome measures, as well as through direct input from a set of patients with a full spectrum of rotator cuff disease. These patients had documented rotator cuff pathoses ranging from primary impingement tendinopathy to massive rotator cuff defects. Their input resulted in the generation of a number of items directly pertaining to shoulder rotator cuff problems and generic quality-of-life issues. The items were formulated into a preliminary questionnaire in which a standard 100-point visual analog scale (VAS) response format was used.

This preliminary questionnaire was then administered and pretested on a separate group of 20 patients with documented rotator cuff disease. Each patient underwent a structured interview that was conducted by one of the investigators. The interview consisted of five questions pertaining to whether the items were semantically appropriate, whether the patient considered the items important to his or her quality of life, whether the patient could comprehend the questions, and whether the patient would suggest any modifications to the questionnaire.

A revised 55-item questionnaire was then developed; it was produced according to standard questionnaire development techniques, and it too made use of the VAS response format. On the basis of qualitative and quantitative criteria, reduction of this 55-item instrument to a smaller, more manageable questionnaire was considered. The qualitative criteria included the importance of each item in demonstrating a quality-of-life issue, the importance of each item to patients, and the elimination of redundancy or ambiguity in the final set of items. The quantitative criteria were the measures of reliability of the questions.

The reliability of the outcome was determined by administering the questionnaire to a group of 30 consecutive patients with documented rotator cuff disease. The questionnaire was administered on each of two

separate occasions, 2 weeks apart, so that test/retest reliability could be assessed. The reliability analysis involved calculating (1) the average differences between administrations of the questionnaires for each individual question and (2) the overall score, the maximum being 100. It was determined a priori that any question with an average error of 15% or greater would be considered for deletion from the final questionnaire.

The resulting questionnaire was then used in the second part of the investigation so that its validity could be determined. Two components of validation were tested. It was hypothesized that the RC-QOL should be able to distinguish between large and massive cuff tears; in this way, a measure of discriminant validity would be assessed.

The number of items in the RC-QOL questionnaire was reduced from 55 to 34; 21 of the original questions were eliminated because of poor test/retest reliability, redundancy, or lack of importance. These 21 items were eliminated on the basis of both quantitative and qualitative criteria. The final 34-item questionnaire had an overall average error differ-

Quality-of-Life Assessment in Rotator Cuff Patients

Section A

The first section is related to **symptoms and physical complaints**.

1. With any prolonged activity (ie, greater than half an hour), how much pain or discomfort do you experience in your shoulder?
0 _____ 100 N/A
Severe pain No pain at all
2. With respect to your overall shoulder function, how much are you troubled by stiffness or loss of motion?
0 _____ 100
Severely troubled Not troubled at all
3. With respect to your overall shoulder function and considering the strength of your muscles, how weak is your shoulder?
0 _____ 100
Totally weak Not weak at all
4. With respect to bathing or taking a shower, how much pain/difficulty do you experience because of your shoulder?
0 _____ 100
Severe pain/difficulty No pain/difficulty at all
5. With respect to putting on or removing clothing over your head, how much pain/difficulty do you experience because of your shoulder?
0 _____ 100
Severe pain/difficulty No pain/difficulty at all
6. With respect to putting on a belt through the loop holes of a pair of pants that you are wearing, how much pain/difficulty do you experience because of your shoulder?
0 _____ 100
Severe pain/difficulty No pain/difficulty at all
7. With respect to cutting food for preparation or at meals, how much pain/difficulty do you experience because of your shoulder?
0 _____ 100
Severe pain/difficulty No pain/difficulty at all
8. With respect to doing household chores (ie, mopping floor/vacuuming the rug, ironing clothes, making a bed, scrubbing pots/pans, cleaning bathtub/toilet), how much pain/difficulty do you experience because of your shoulder?
0 _____ 100 N/A
Severe pain/difficulty No pain/difficulty at all
9. With respect to carrying 4.5 to 6.8 kg (10 to 15 lb), with your arm at your side (ie, carrying a heavy briefcase, small suitcase, or shopping bags), how much

Fig. 85. The Rotator Cuff Quality-of-Life Measure (RC-QOL)

- pain/difficulty do you experience because of your shoulder?
 0 _____ 100
 Severe pain/difficulty No pain/difficulty at all
10. With respect to cutting the grass, raking the lawn, or shoveling snow, how much pain/difficulty do you experience because of your shoulder?
 0 _____ 100 N/A
 Severe pain/difficulty No pain/difficulty at all
11. Do you have pain/difficulty falling asleep because of your shoulder?
 0 _____ 100
 Severe pain/difficulty No pain/difficulty at all
12. Are you awakened from sleep because of your shoulder?
 0 _____ 100
 Always awakened Never awakened
13. With respect to driving a motor vehicle, how much pain/difficulty do you experience because of your shoulder?
 0 _____ 100 N/A
 Severe pain/difficulty No pain/difficulty at all
14. With respect to opening and closing a door with your affected arm, how much pain/difficulty do you experience because of your shoulder?
 0 _____ 100
 Severe pain/difficulty No pain/difficulty at all
15. With respect to reaching (ie, into the back of a car) with your affected arm, how much pain/difficulty do you experience because of your shoulder?
 0 _____ 100 N/A
 Severe pain/difficulty No pain/difficulty at all
16. Indicate the point ranging from 0 to 100 which most closely describes your overall present level of shoulder pain.
 0 _____ 100
 Severe pain/difficulty No pain/difficulty at all
- Are there any other physical issues that you feel should be addressed?

Section B

The following questions are related to your job or vocation (ie, **work-related concerns**). The questions are regarding your ability to function at work and the extent to which your shoulder has affected your current work-related concerns. If you are a full-time student/homemaker, then consider this and any part-time work together. Consider the last 3 months.

If you are not working for reasons other than your shoulder problem, proceed to question 21.

Indicate, with a slash on the line, the point ranging from 0 to 100 that most closely represents your situation.

17. With respect to working with your arm at shoulder level, how much pain/difficulty do you experience because of your shoulder?
 0 _____ 100 N/A
 Severe pain/difficulty No pain/difficulty at all
18. With respect to working with your arm above shoulder level, how much pain/difficulty do you experience because of your shoulder?
 0 _____ 100 N/A
 Severe pain/difficulty No pain/difficulty at all
19. How much of the time are you concerned with missing days from work because of problems with or re-injury to your shoulder? (Make a slash at the extreme left if you are unable to work because of your shoulder.)
 0 _____ 100 N/A
 Greatly concerned Not concerned at all
20. How much of the time are you concerned that the activities you do at work may result in the state of your shoulder becoming worse? (Make a slash at the extreme left if you are unable to work because of your shoulder.)
 0 _____ 100 N/A
 All of the time None of the time

Are there any other occupational issues that you feel should be addressed?

Section C

The following questions are being asked with respect to your **recreational activities and sport participation or competition**. The questions are concerned with

Fig. 85 (continued)

ence of 5.05%; this represents a 5-point error on the overall score (out of 100 points). The overall averages for the two administrations of the questionnaire were almost identical (58.84 vs. 59.63), and the range of responses demonstrated a normal distribution.

The final 34 questions were distributed into five separate domains representing different aspects of quality of life as it pertains to rotator cuff

the extent to which your painful shoulder affects your ability to function and participate in these activities. Consider the last 3 months.

If you are not involved in any sporting activities whatsoever, proceed to question 25.

21. With respect to participating in general sports activities, how much pain/difficulty do you experience because of your shoulder?

0 _____ 100 N/A
Severe pain/difficulty No pain/difficulty at all

22. With respect to participating in upper-extremity sports (eg, baseball, tennis, golf, squash, volleyball, swimming, throwing), how much pain/difficulty do you experience because of your shoulder?

0 _____ 100 N/A
Severe pain/difficulty No pain/difficulty at all

23. How much of the time are you concerned that your sporting/recreational activities may result in the status of your shoulder becoming worse?

0 _____ 100 N/A
All of the time None of the time

24. With respect to your current level of athletic or recreational performance, how does it compare with your pre-injury level?

0 _____ 100
Totally limited No limitations

Section D

The following questions are being asked with respect to your **lifestyle**. The questions are concerned with your lifestyle in general and the extent to which your painful shoulder affects activities other than those related to your work and sports/recreation. Consider the last 3 months.

25. How often do you have to concern yourself with general safety (eg, carrying small children, working in the yard, climbing a ladder, using power tools) with respect to your injured shoulder?

0 _____ 100 N/A
All of the time None of the time

26. How much has your enjoyment of life been limited by your shoulder problem?

0 _____ 100
Totally limited No limitations

27. How often are you aware of your shoulder problem?

0 _____ 100
All of the time None of the time

28. With respect to your lifestyle as it relates to you and your family together, how often are you concerned about your shoulder?

0 _____ 100
All of the time None of the time

29. You have had your problem shoulder for some time. During this time, have you modified your lifestyle to avoid potentially damaging activities to your shoulder?

0 _____ 100
Totally modified No modifications

Section E

The following questions are regarding the **social and emotional aspects** of your shoulder problem. The questions are concerned with your attitudes and feelings as they relate to your painful shoulder. Consider the last 3 months.

30. Do you experience difficulty making decisions at home or at work because of your shoulder problem?

0 _____ 100
Extremely difficult Not difficult at all

31. Do you have peace of mind, or are you too worried to sleep at night because of your shoulder problem?

0 _____ 100
Extremely worried Not worried at all

32. Are you afraid of re-injuring your shoulder?

0 _____ 100
Extremely afraid Not afraid at all

33. Do you experience psychological difficulty when engaging in sexual activity because of your shoulder problem?

0 _____ 100 N/A
Extremely difficult Not difficult at all

34. Does your shoulder problem interfere with your ability to socialize with friends and family?

0 _____ 100
Unable to socialize Able to socialize fully

Fig. 85 (continued)

disease of the shoulder. There were questions in the domains of (1) symptoms and physical complaints, (2) sports and recreation, (3) work-related concerns, (4) lifestyle issues, and (5) social and emotional issues (see Fig. 85). All questions were considered to have face validity on the basis of direct patient input at each stage of the development of the Instrument.

19.19 The Western Ontario osteoarthritis of the shoulder index (WOOS) [80]*

The purpose was to develop and validate a disease-specific quality of life measurement tool for osteoarthritis (OA) of the shoulder.

An Instrument which could be used as the primary outcome measure in clinical trials involving patients with OA of the shoulder was developed using a specific methodological protocol: (1) identification of a specific patient population; (2) item generation; (3) item reduction; (4) pretesting of the prototype questionnaire and (5) determining the validity reliability and responsiveness of the final questionnaire.

The final instrument has 19 items, representing the four domains (six questions for pain and physical symptoms, five questions for sport, recreation and work function, five questions for lifestyle function and three questions for emotional function (Fig. 86). The response time is approximately 10 min.

In the final instrument, each question has a possible score from 0–100 (100 mm VAS) and is not multiplied by any factor because of the equal weighting. These scores are added to give a total score of 1900.

The highest or most symptomatic score is 1900 and the best or asymptomatic score is 0. In order to present this in a clinically more meaningful format, the score can be reported as a percentage of normal by subtracting the total from 1900, dividing by 1900 and multiplying by 100. As an example, a patient with a total score of 450 would have a percentage score of

$$\frac{(1900 - 450)}{1900} \times 100 = 76.3\%$$

The instrument contains specific instructions to be read by the subjects prior to beginning and a supplement to the instrument may be referred to if patients are unsure of the meaning of any question. The instrument also has specific instructions to the clinician on how it should be scored. These features allow for a more consistent presentation to all subjects and evaluations can be done by mail when necessary. Thus, results using this measurement tool may be compared between centres.

The WOOS is a rigorously designed measurement tool for patients with OA of the shoulder that is valid, reliable and highly responsive. Since the patient's own perception of changes in health status is the most important indicator of the success of treatment, we suggest that this measurement tool may be used as the primary outcome in clinical trials of treatments in this patient population. Its properties also allow it to be used in the clinical setting.

SECTION A: Physical Symptoms
INSTRUCTIONS TO PATIENTS

The following questions concern the physical symptoms you have experienced due to your shoulder problem. In all cases, please enter the amount of the symptom you have experienced in the last week. (Please mark your answers with a slash "/")


1. How much pain do you experience in your shoulder with movement?



2. How much constant, nagging pain do you have in your shoulder?




3. How much weakness do you experience in your shoulder?




4. How much stiffness do you experience in your shoulder?



5. How much grinding do you experience in your shoulder?




6. How much is your shoulder affected by the weather?



SECTION B:
Sports/Recreation/Work
INSTRUCTIONS TO PATIENTS

The following section concerns how your shoulder problem has affected your sports or recreational activities in the past week. (Please mark your answers with a slash "/")

7. How much difficulty do you experience working or reaching above shoulder level?




8. How much difficulty do you experience with lifting objects (e.g. grocery bags, garbage can etc.) below shoulder level?



9. How much difficulty do you experience doing repetitive motions below shoulder level such as raking, sweeping or washing floors because of your shoulder?



10. How much difficulty do you experience pushing or pulling forcefully because of your shoulder?



11. How troubled are you by an increase in pain in your shoulder after activities?




Fig. 86. The Western Ontario Osteoarthritis of the Shoulder (WOOS)


SECTION C: Lifestyle**INSTRUCTIONS TO PATIENTS**

The following section concerns the amount that your shoulder problem has affected or changed your lifestyle. Again, please indicate the appropriate amount for the past week with a slash "/".


12. How much difficulty do you have sleeping because of your shoulder?




13. How much difficulty have you experienced with styling your hair because of your shoulder?




14. How much difficulty do you have maintaining your desired level of fitness because of your shoulder?



15. How much difficulty do you experience reaching behind to tuck in a shirt, get a wallet from your back pocket or do up clothing because of your shoulder?




16. How much difficulty do you have dressing or undressing?


**SECTION D: Emotions****INSTRUCTIONS TO PATIENTS**

The following questions relate to how you have felt in the past week with regard to your shoulder problem. Please indicate your answer with a slash "/".


17. How much frustration or discouragement do you feel because of your shoulder?



18. How worried are you about what will happen to your shoulder in the future?



19. How much of a burden do you feel you are on others?



References

1. Allman, F.L., Jr.: Fractures and ligamentous injuries of the clavicle and its articulation. *J Bone Joint Surg Am*, 49(4): 774–784, 1967
2. Amstutz, H.C., Sew Hoy, A.L., Clarke, I.C.: UCLA anatomic total shoulder arthroplasty. *Clin Orthop Relat Res*, (155): 7–20, 1981
3. Antuna, S.A., Sperling, J.W., Cofield, R.H., Rowland, C.M.: Glenoid revision surgery after total shoulder arthroplasty. *J Shoulder Elbow Surg*, 10(3): 217–224, 2001
4. Arlet, J., and Ficat, P.: Diagnosis of primary femur head osteonecrosis at stage 1 (preradiologic stage). *Rev Chir Orthop Reparatrice Appar Mot*, 54(7): 637–648, 1968 [in French]
5. Bayley, I.: The classification of shoulder instability: new light through old windows. In: 17th Congress of the European Society for Surgery of the Shoulder and the Elbow. Edited by Habermeyer, P., Magosch, P, Heidelberg, Germany, 2003
6. Bayley, I., Fisher, K, Tsutsui, H, Matthews, J: Functional biofeedback in the management of habitual shoulder instability: a pilot study. In: Third International Conference on Surgery of the Shoulder. Edited by Takagishi, N., pp. 312–317. Fukuoka, Japan, Professional Postgraduate Services, K.K., 1986
7. Bayne, O., Bateman J.E.: Long term results of surgical repair of full thickness rotator cuff tears. In: *Surgery of the shoulder*, pp. 167–171. Edited by Bateman, J.E., Welsch, R.P. Philadelphia, Saint Louis, Toronto, London, B.C. Decker Inc., The C.V. Mosby Company, 1984
8. Bennett, W.F.: Subscapularis, medial, and lateral head coracohumeral ligament insertion anatomy. Arthroscopic appearance and incidence of “hidden” rotator interval lesions. *Arthroscopy*, 17(2): 173–180, 2001
9. Bigliani, L.U., Morrison, D.S., April, E.W.: The morphology of the acromion and rotator cuff impingement. *Orthop Trans*, 10: 228, 1986
10. Bigliani, L.U., Newton, P.M., Steinmann, S.P., Connor, P.M., McLlveen, S.J.: Glenoid rim lesions associated with recurrent anterior dislocation of the shoulder. *Am J Sports Med*, 26(1): 41–45, 1998
11. Bigliani, L.U., Ticker, J.B., Flatow, E.L., Soslowsky, L.J., Mow, V.C.: The relationship of acromial architecture to rotator cuff disease. *Clin Sports Med*, 10(4): 823–838, 1991
12. Boehm, D.: Scores. In: *Schulter: das Standardwerk für Klinik und Praxis*, pp. 98–104. Edited by Gohlke, F., Hedtmann, A. Stuttgart, New York, Thieme, 2002

13. Boehm, D., Wollmerstedt, N., Doesch, M., Handwerker, M., Mehling, E., Gohlke, F.: Development of a questionnaire based on the Constant-Murley Score for self-evaluation of shoulder function by patients. *Unfallchirurg*, 107(5): 397–402, 2004 [in German]
14. Boileau, P., Lafosse, L., Merg, M: Arthroscopic classification of Labro-ligamentous lesions associated with chronic anterior instability of the shoulder. In: Nice shoulder course, pp. 35–46. Edited by Boileau. Nice, France, Sauramps médical, 2003
15. Boileau, P., Trojani, C., Walch, G., Krishnan, S.G., Romeo, A., Sinnerton, R.: Shoulder arthroplasty for the treatment of the sequelae of fractures of the proximal humerus. *J Shoulder Elbow Surg*, 10(4): 299–308, 2001
16. Bosworth, B.: Calcium deposits in the shoulder and subacromial bursitis. *J Am Med Assoc*, 2477–2484, 1941
17. Brunner, U., Scheiberer, L: Humeruskopffraktur. In: *Schulterchirurgie*, pp. 239–260. Edited by Habermeyer, P., Schweiberer, L. München, Wien, Baltimore, Urban und Schwarzenberg, 1996
18. Burkhart, S.S., De Beer, J.E: Traumatic glenohumeral bone defects and their relationship to failure of arthroscopic Bankart repairs: significance of the inverted-pear glenoid and the humeral engaging Hill-Sachs lesion. *Arthroscopy*, 16(7): 677–694, 2000
19. Calandra, J.J., Baker, C.L., Uribe, J.: The incidence of Hill-Sachs lesions in initial anterior shoulder dislocations. *Arthroscopy*, 5(4): 254–257, 1989
20. Cierny G.M.J., Pennick J.: A clinical staging system for adult osteomyelitis. *Contemp Orthop*, 5: 17, 1985
21. Cofield, R.H.: Subscapular muscle transposition for repair of chronic rotator cuff tears. *Surg Gynecol Obstet*, 154(5): 667–672, 1982
22. Collins, S.L., Moore, R.A., McQuay, H.J.: The visual analogue pain intensity scale: What is moderate pain in millimetres? *Pain*, 72(1–2): 95–97, 1997
23. Constant, C.R., Murley, A.H.: A clinical method of functional assessment of the shoulder. *Clin Orthop Relat Res*, (214): 160–164, 1987
24. Craig, E.V.: Fractures of the clavicle. In: *The shoulder*, pp. 367–412. Edited by Rockwood, C.A., Jr., Matsen F.A., III, pp. 367–412. Philadelphia, London, Toronto, Montreal, Sydney, Tokyo, W.B. Saunders Company, 1990
25. Cruess, R.L.: Osteonecrosis of bone. Current concepts as to etiology and pathogenesis. *Clin Orthop Relat Res*, 208: 30–39, 1986
26. Dawson, J., Fitzpatrick, R., Carr, A.: The assessment of shoulder instability. The development and validation of a questionnaire. *J Bone Joint Surg Br*, 81(3): 420–426, 1999
27. Dawson, J., Fitzpatrick, R., Carr, A.: Questionnaire on the perceptions of patients about shoulder surgery. *J Bone Joint Surg Br*, 78(4): 593–600, 1996
28. DePalma, A.: Regional, variational, and surgical anatomy. In: *Surgery of the shoulder*, pp. 35–64. Edited by DePalma, A., pp 35–64. Philadelphia, J.B. Lippincott Company, 1983

29. DePalma A.F., Callery G., Bennett G.A.: Variational anatomy and degenerative lesions of shoulder joint. *Instr Course Lect*: 255–281, 1949
30. DeCloux M.P., Lemerle M.P.: Omoplate. *Lille Chir*, 11: 215–227, 1956
31. DePalma, A.F.: Surgical anatomy of acromioclavicular and sternoclavicular joints. *Surg Clin North Am*, 43: 1541–1550, 1963
32. Ellman, H.: Diagnosis and treatment of incomplete rotator cuff tears. *Clin Orthop Relat Res*, (254): 64–74, 1990
33. Ellman, H., Gartsman, G.M.: Open repair of full-thickness rotator cuff tears. Edited by Ellman, H., Gartsman, G.M., pp 181–202. Philadelphia, Baltimore, Hong Kong, London, Munich, Sydney, Tokyo, Lea and Febiger, 1993
34. Ellman, H., Gartsman, G.M.: Treatment of partial-thickness rotator cuff tears: arthroscopic and mini-open. Edited by Ellman, H., Gartsman, G.M., pp. 155–180. Philadelphia, Baltimore, Hong Kong, London, Munich, Sydney, Tokyo, Lea and Febiger, 1993
35. Enneking, W.F., Spanier, S.S., Goodman, M.A.: A system for the surgical staging of musculoskeletal sarcoma. *Clin Orthop Relat Res*, 153: 106–120, 1980
36. Epstein, R.E., Schweitzer, M.E., Frieman, B.G., Fenlin, J.M., Jr., Mitchell, D.G.: Hooked acromion: prevalence on MR images of painful shoulders. *Radiology*, 187(2): 479–481, 1993
37. Euler, E., Rüedi, T.: Scapulafraktur. In: *Schulterchirurgie*, pp. 261–272. Edited by Habermeyer, P., Schweiberer, L., pp 261–272. München, Wien, Baltimore, Urban and Schwarzenberg, 1996
38. Favard, L., Lautmann, S., Clement, P.: Osteoarthritis with massive rotator cuff tear: the limitation of its current definitions. In: *The cuff*. Edited by Gazielly, D., Gleyze, P., Thomas, T., pp. 261–265. Paris, Elsevier, 1997
39. Fox, J., Romeo, A.A.: Arthroscopic subscapularis repair. In: *Annual Meeting of the American Academy of Orthopaedic Surgeons*. New Orleans, Louisiana, 2003
40. Franklin, J.L., Barrett, W.P., Jackins, S.E., Matsen, F.A., III: Glenoid loosening in total shoulder arthroplasty. Association with rotator cuff deficiency. *J Arthroplasty*, 3(1): 39–46, 1988
41. Friedman, R.J., Hawthorne, K.B., Genez, B.M.: The use of computerized tomography in the measurement of glenoid version. *J Bone Joint Surg Am*, 74(7): 1032–1037, 1992
42. Gächter, A.: Die Bedeutung der Arthroskopie beim Pyarthros. In 5. Deutsch-Österr.-Schweizerische Unfalltagung, pp. 132–136. Berlin, Heidelberg, New York, Springer, 1988
43. Gartner, J., Heyer, A.: Calcific tendinitis of the shoulder. *Orthopade*, 24(3): 284–302, 1995 [in German]
44. Gerber, C.: Les instabilités de l'épaule. *Cahiers d'enseignement de la SOFCOT*, 33: 51–74. Paris, Expansion Scientifique Française, 1988
45. Gerber, C., Nyffeler, R.W.: Classification of glenohumeral joint instability. *Clin Orthop Relat Res*, (400): 65–76, 2002
46. Gohlke, F., Essigkrug, B., Schmitz, F.: The pattern of the collagen fiber bundles of the capsule of the glenohumeral joint. *J Shoulder Elbow Surg*, 3: 111–128, 1994

47. Goss, T.P.: Double disruptions of the superior shoulder suspensory complex. *J Orthop Trauma*, 7(2): 99–106, 1993
48. Goss, T.P.: Scapular fractures and dislocations: diagnosis and treatment. *J Am Acad Orthop Surg*, 3(1): 22–33, 1995
49. Goutallier, D., Postel, J.M., Bernageau, J., Lavau, L., Voisin, M.C.: Fatty muscle degeneration in cuff ruptures. Pre- and postoperative evaluation by CT scan. *Clin Orthop Relat Res*, 304: 78–83, 1994
50. Habermeyer, P., Gleyze, P., Rickert, M.: Evolution of lesions of the labrum-ligament complex in posttraumatic anterior shoulder instability: a prospective study. *J Shoulder Elbow Surg*, 8(1): 66–74, 1999
51. Habermeyer, P., Lehmann, L.: Rotatorenmanschette, Rotatorenintervall und lange Bizepssehne. Edited by Habermeyer P., pp. 333–374. München, Jena, Urban und Fischer, 2002
- 51a. Habermeyer, P., Magosch, P., Lichtenberg, S.: Three dimensional glenoid deformity in patients with osteoarthritis. A radiographic analysis. *J Bone Joint Surg A*-2006
52. Habermeyer, P., Magosch, P., Pritsch, M., Scheibel, M.T., Lichtenberg, S.: Antero-superior impingement of the shoulder as a result of pulley lesions: a prospective arthroscopic study. *J Shoulder Elbow Surg*, 13(1): 5–12, 2004
53. Habermeyer, P., Schiller, K., Schweiberer L.: Rotatorenmanschette. In: *Schulterchirurgie*. Edited by Habermeyer, P., Krueger, P., Schweiberer, L., pp. 149–167. München, Wien, Baltimore, Urban und Schwarzenberg, 1990
54. Habermeyer, P., Walch G.: The biceps tendon and rotator cuff disease. In: *Rotator cuff disorders*. Edited by Burkead, W., Jr., pp. 142–159. Baltimore, Philadelphia, London, Paris, Bangkok, Buenos Aires, Hong Kong, Munich, Sydney, Tokyo, Warsaw, Williams and Wilkins, 1996
55. Hamada, K., Fukuda, H., Mikasa, M., Kobayashi, Y.: Roentgenographic findings in massive rotator cuff tears. A long-term observation. *Clin Orthop Relat Res*, 254: 92–96, 1990
56. Hattrup, S.J., Cofield, R.H.: Osteonecrosis of the humeral head: relationship of disease stage, extent, and cause to natural history. *J Shoulder Elbow Surg*, 8(6): 559–564, 1999
57. Hawkins, R., Schutte, J.P., Huckell, G.J., Abrams, J.: The assessment of glenohumeral translation using manual and fluoroscopic techniques. *Orthop Trans*, 12: 727, 1988
58. Hedtmann, A., Fett, H., Heers, G.: Läsionen im Bereich des Rotatorenintervalls und der langen Bizepssehne. In: *Schulter: das Standardwerk für Klinik und Praxis*. Edited by Gohlke, F., Hedtmann, A., Stuttgart, New York, Georg Thieme Verlag, 310–316, 2002
59. Hollinshead, R.M., Mohtadi, N.G., Vande Guchte, R.A., Wadey, V.M.: Two 6-year follow-up studies of large and massive rotator cuff tears: comparison of outcome measures. *J Shoulder Elbow Surg*, 9(5): 373–381, 2000
60. Hudak, P.L., Amadio, P.C., Bombardier, C.: Development of an upper extremity outcome measure: the DASH (disabilities of the arm, shoulder and hand) [cor-

- rected]. The Upper Extremity Collaborative Group (UECG). *Am J Ind Med*, 29(6): 602–608, 1996
61. Ideberg, R., Grevsten, S., Larsson, S.: Epidemiology of scapular fractures. Incidence and classification of 338 fractures. *Acta Orthop Scand*, 66(5): 395–397, 1995
 62. Jager, M., Breitner, S.: Therapy related classification of lateral clavicular fracture. *Unfallheilkunde*, 87(11): 467–473, 1984 [in German]
 63. Jakob, R., Kristiansen, T., Mayo, K., Ganz, R., Müller, M.E.: Classification and aspects of treatment of fractures of the proximal humerus. In: *Surgery of the shoulder*. Edited by Bateman, J., Welsh, R.P., pp. 330–343. Philadelphia, Toronto, Saint Louis, London, B.C. Decker Inc., The C.V. Mosby Company, 1984
 64. Jobe, F.W., Giangarra, C.E., Kvitne, R.S., Glousman, R.E.: Anterior capsulolabral reconstruction of the shoulder in athletes in overhand sports. *Am J Sports Med*, 19(5): 428–434, 1991
 65. Jobe, F.W., Jobe, C.M.: Painful athletic injuries of the shoulder. *Clin Orthop Relat Res*, (173): 117–124, 1983
 66. Jobe, F.W., Kvitne, R.S., Giangarra, C.E.: Shoulder pain in the overhand or throwing athlete. The relationship of anterior instability and rotator cuff impingement. *Orthop Rev*, 18(9): 963–975, 1989
 67. Katolik, L.I., Romeo, A.A., Cole, B.J., Verma, N.N., Hayden, J.K., Bach, B.R.: Normalization of the constant score. *J Shoulder Elbow Surg*, 14(3): 279–285, 2005
 68. Kibler, W.B., McMullen, J.: Scapular dyskinesia and its relation to shoulder pain. *J Am Acad Orthop Surg*, 11(2): 142–151, 2003
 69. Kirkley, A., Alvarez, C., Griffin, S.: The development and evaluation of a disease-specific quality-of-life questionnaire for disorders of the rotator cuff: the Western Ontario Rotator Cuff Index. *Clin J Sport Med*, 13(2): 84–92, 2003
 70. Kirkley, A., Griffin, S., McLintock, H., Ng, L.: The development and evaluation of a disease-specific quality of life measurement tool for shoulder instability. The Western Ontario Shoulder Instability Index (WOSI). *Am J Sports Med*, 26(6): 764–772, 1998
 71. Kjaersgaard-Andersen, P., Frich, L.H., Sojbjerg, J.O., Sneppen, O.: Heterotopic bone formation following total shoulder arthroplasty. *J Arthroplasty*, 4(2): 99–104, 1989
 72. Kumar, S., Sperling, J.W., Haidukewych, G.H., Cofield, R.H.: Periprosthetic humeral fractures after shoulder arthroplasty. *J Bone Joint Surg Am*, 86-A(4): 680–689, 2004
 73. Kvitne, R.S., Jobe, F.W., Jobe, C.M.: Shoulder instability in the overhand or throwing athlete. *Clin Sports Med*, 14(4): 917–935, 1995
 74. L'Insalata, J.C., Warren, R.F., Cohen, S.B., Altchek, D.W., Peterson, M.G.: A self-administered questionnaire for assessment of symptoms and function of the shoulder. *J Bone Joint Surg Am*, 79(5): 738–748, 1997
 75. Larsen, A., Dale, K., Eek, M.: Radiographic evaluation of rheumatoid arthritis and related conditions by standard reference films. *Acta Radiol Diagn (Stockh)*, 18(4): 481–491, 1977

76. Lévigne C, Franceschi J.: Rheumatoid arthritis of the shoulder: radiological presentation and results of arthroplasty. In: *Shoulder arthroplasty*. Edited by Walch, G., Boileau, P., pp. 221–230. Berlin, Heidelberg, New York, Barcelona, Hong Kong, London, Milan, Paris, Singapore, Tokyo, Springer, 1999
77. Liberson, F.: Os acromiale: a contested anomaly. *J Bone Joint Surg*, 19: 683–689, 1937
78. Lichtenberg, S., Habermeyer, P.: Operative Arthroskopie des Glenohumeralgelenks. In: *Schulterchirurgie*. Edited by Habermeyer, P., pp. 237–271. München, Jena, Urban und Fischer, 2002
79. Lippitt, S., Harryman D.T., Matsen, F.A.: A practical tool for evaluating function: the simple shoulder test. In: *The shoulder: a balance of mobility and stability*. Edited by Matsen, F. A., III, Fu, F. H., Hawkins, R. J., pp. 501–518. Rosemont, American Academy of Orthopaedic Surgeons, 1992
80. Lo, I.K., Griffin, S., Kirkley, A.: The development of a disease-specific quality of life measurement tool for osteoarthritis of the shoulder: the Western Ontario Osteoarthritis of the Shoulder (WOOS) index. *Osteoarthritis Cartilage*, 9(8): 771–778, 2001
81. Lundberg, B.J.: The frozen shoulder. Clinical and radiographical observations. The effect of manipulation under general anesthesia. Structure and glycosaminoglycan content of the joint capsule. Local bone metabolism. *Acta Orthop Scand Suppl*, 119: 1–59, 1969
82. Maffet, M.W., Gartsman, G.M., Moseley, B.: Superior labrum-biceps tendon complex lesions of the shoulder. *Am J Sports Med*, 23(1): 93–98, 1995
83. Marcus, N.D., Enneking, W.F., Massam, R.A.: The silent hip in idiopathic aseptic necrosis. Treatment by bone-grafting. *J Bone Joint Surg Am*, 55(7): 1351–1366, 1973
84. Matsen, F.A., III, Harryman, D.T., 2nd, Sidles, J. A.: Mechanics of glenohumeral instability. *Clin Sports Med*, 10(4): 783–788, 1991
85. Molé, D., Kempf, J.F., Gleyze, P., Rio, B., Bonnomet, F., Walch, G.: Results of endoscopic treatment of non-broken tendinopathies of the rotator cuff. 2. Calcifications of the rotator cuff. *Rev Chir Orthop Reparatrice Appar Mot*, 79(7): 532–541, 1993 [in French]
86. Molé, D., Roche, O., Riand, N., Lévigne, C., Walch, G.: Cemented glenoid component: results in osteoarthritis and rheumatoid arthritis. In: *Shoulder arthroplasty*. Edited by Walch, G., Boileau, P., pp. 163–171. Berlin, Heidelberg, New York, Barcelona, Hong Kong, London, Milan, Paris, Singapore, Tokyo, Springer, 1999
87. Morgan, C., Ramses, R.D., Snyder, S.J.: Anatomical variations of the glenohumeral ligaments. In: *58th Annual Meeting of the American Academy of Orthopaedic Surgeons*. Anaheim, California, 1991
88. Morgan, C.D., Burkhart, S.S., Palmeri, M., Gillespie, M.: Type II SLAP lesions: three subtypes and their relationships to superior instability and rotator cuff tears. *Arthroscopy*, 14(6): 553–565, 1998
89. Moseley, H.F.: *Shoulder lesions*, vol 28. Edinburgh, Churchill Livingstone, 1972

90. Mudge, M.K., Wood, V.E., Frykman, G.K.: Rotator cuff tears associated with os acromiale. *J Bone Joint Surg Am*, 66(3): 427–429, 1984
91. Müller, M.: The comprehensive classification of fractures of long bones. In: *Manual of internal fixation*. Edited by Müller, M., Allgöwer, M., Schneider, R., Wille-negger, H., pp. 118–125. Tokyo, Berlin, Heidelberg, New York, Springer-Verlag, 1988
92. Murthi, A.M., Vosburgh, C.L., Neviasser, T.J.: The incidence of pathologic changes of the long head of the biceps tendon. *J Shoulder Elbow Surg*, 9(5): 382–385, 2000
93. Neer II, C.S.: Displaced proximal humeral fractures. I. Classification and evaluation. *J Bone Joint Surg Am*, 52(6): 1077–1089, 1970
94. Neer II, C.S.: Four-segment classification of proximal humeral fractures: purpose and reliable use. *J Shoulder Elbow Surg*, 11(4): 389–400, 2002
95. Neer II, C.S.: Fracture of the distal clavicle with detachment of the coracoclavicular ligaments in adults. *J Trauma*, 3: 99–110, 1963
96. Neer II, C.S.: Fractures of the distal third of the clavicle. *Clin Orthop Relat Res*, 58: 43–50, 1968
97. Neer II, C.S.: Impingement lesions. *Clin Orthop Relat Res*, 173: 70–77, 1983
98. Neer II, C.S.: Nonunion of the clavicle. *J Am Med Assoc*, 172: 1006–1011, 1960
99. Neer II, C.S., Foster, C.R.: Inferior capsular shift for involuntary inferior and multidirectional instability of the shoulder. A preliminary report. *J Bone Joint Surg Am*, 62(6): 897–908, 1980
100. Neer II, C.S.: Dislocations. In: *Shoulder reconstruction*. Edited by Neer II, C.S., pp. 274–362. Philadelphia, London, Toronto, Montreal, Sydney, Tokyo, W.B. Saunders Company, 1990
101. Neer II, C.S.: Fractures. In: *Shoulder reconstruction*. Edited by Neer II, C.S., pp. 363–420. Philadelphia, London, Toronto, Montreal, Sydney, Tokyo, W.B. Saunders Company, 1990
102. Neer II, C.S.: Glenohumeral arthroplasty. In: *Shoulder reconstruction*. Edited by Neer II, C.S., pp. 143–271. Philadelphia, London, Toronto, Montreal, Sydney, Tokyo, W.B. Saunders Company, 1990
103. Neviasser, T.J.: Adhesive capsulitis. *Orthop Clin North Am*, 18(3): 439–443, 1987
104. Neviasser, T.J.: The anterior labroligamentous periosteal sleeve avulsion lesion: a cause of anterior instability of the shoulder. *Arthroscopy*, 9(1): 17–21, 1993
105. Neviasser, T.J.: The GLAD lesion: another cause of anterior shoulder pain. *Arthroscopy*, 9(1): 22–23, 1993
- 105a. Nové-Josserand, L., Basso, M.: Atraumatic avascular necrosis of the humeral head: clinical and radiographic classification. In: Walch, G., Boileau, P. (eds.): *Shoulder arthroplasty*, pp. 243–250. Berlin, Heidelberg, Springer, 1999
106. Outerbridge, R.E.: The etiology of chondromalacia patellae. *J Bone Joint Surg Br*, 43-B: 752–757, 1961
107. Patte, D.: Classification of rotator cuff lesions. *Clin Orthop Relat Res*, (254): 81–86, 1990

108. Ramsey, M., Klimkiewicz, J.J.: Posterior instability: diagnosis and management. In: Disorders of the shoulder: diagnosis and management. Edited by Iannotti, J., Williams, G.R., pp. 295–319. Philadelphia, Lippincott Williams & Wilkins, 1999
109. Reeves, B.: The natural history of the frozen shoulder syndrome. *Scand J Rheumatol*, 4(4): 193–196, 1975
110. Rengachary, S.S., Burr D., Lucas, S., Hassanein, K.M., Mohn, M.P., Matzke, H.: Suprascapular entrapment neuropathy: a clinical, anatomical, and comparative study. *Neurosurgery*, 5: 447–451, 1979
111. Research Committee, A.S.E.S., Richards, R.R., An, K.N., Bigliani, L.U., Friedman R.J., Gartsman, G.M., Gristina A.G., Iannotti, J.P., Mow, V.C., Sidles J.A., Zuckerman, J.D.: A standardized method for the assessment of shoulder function. *J Shoulder Elbow Surg*, 3: 347–352, 1994
112. Revill, S.I., Robinson, J.O., Rosen, M., Hogg, M.I.: The reliability of a linear analogue for evaluating pain. *Anaesthesia*, 31(9): 1191–1198, 1976
113. Roach, K.E., Budiman-Mak, E., Songsiridej, N., Lertratanakul, Y.: Development of a shoulder pain and disability index. *Arthritis Care Res*, 4(4): 143–149, 1991
114. Robinson, C.M.: Fractures of the clavicle in the adult. *Epidemiology and classification*. *J Bone Joint Surg Br*, 80(3): 476–484, 1998
115. Rockwood, C.A., Jr., Williams G.R., Young, D.C.: Injuries of the acromioclavicular joint. In: Fractures in adults. Edited by Rockwood, C.A.J., Green D.P., Buchholz, R.W., Heckmann, J.D., pp. 1341–1414. Philadelphia, New York, Lippincott–Raven, 1996
- 115a. Rockwood, C.A., Jr., Wirth, M.A.: Injuries to the Sternoclavicular Joint. In: Fractures in adults. Edited by Rockwood, C.A. Jr., Green, D.P., Buchholz, R.W., Heckmann, J.D., pp. 1415–1471. Philadelphia, New York, Lippincott–Raven, 1996
116. Rowe, C.R., Patel, D., Southmayd, W.W.: The Bankart procedure: a long-term end-result study. *J Bone Joint Surg Am*, 60(1): 1–16, 1978
117. Samilson, R.L., Prieto, V.: Dislocation arthropathy of the shoulder. *J Bone Joint Surg Am*, 65(4): 456–460, 1983
118. Schneeberger, A.G., Hersche, O., Gerber, C.: The unstable shoulder. Classification and therapy. *Orthopade*, 26(10): 909–914, 1997 [in German]
119. Silliman, J.F., Hawkins, R.J.: Classification and physical diagnosis of instability of the shoulder. *Clin Orthop Relat Res*, 291: 7–19, 1993
120. Sirveaux, F., Favard, L., Oudet, D., Huquet, D., Walch, G., Mole, D.: Grammont inverted total shoulder arthroplasty in the treatment of glenohumeral osteoarthritis with massive rupture of the cuff. Results of a multicentre study of 80 shoulders. *J Bone Joint Surg Br*, 86(3): 388–395, 2004
121. Snyder, S.J.: Arthroscopic classification of rotator cuff lesions and surgical decision making. In: Shoulder arthroscopy. Edited by Snyder, S. J., pp. 201–207. Philadelphia, Lippincott Williams and Wilkins, 2003
122. Snyder, S.J.: Labral lesions (non-instability) and SLAP lesions. In: Shoulder arthroscopy. Edited by Snyder, S.J., pp. 115–132. New York, St. Louis, San Francisco, Auckland, Bogotá, Caracas, Lisbon, London, Madrid, Mexico City, Milan,

- Montreal, New Delhi, Paris, San Juan, Singapore, Sydney, Tokyo, Toronto, McGraw-Hill, 1994
123. Snyder, S.J.: Superior labrum, anterior to posterior lesions of the shoulder. In: *Shoulder arthroscopy*. Edited by Snyder, S.J., pp. 147–165. Philadelphia, Baltimore, New York, London, Buenos Aires, Hong Kong, Sydney, Tokyo, Lippincott Williams and Wilkins, 2003
 124. Sperling, J.W., Cofield, R.H., O'Driscoll, S.W., Torchia, M.E., Rowland, C.M.: Radiographic assessment of ingrowth total shoulder arthroplasty. *J Shoulder Elbow Surg*, 9(6): 507–513, 2000
 125. Stutz, G., Kuster, M.S., Kleinstuck, F., Gachter, A.: Arthroscopic management of septic arthritis: stages of infection and results. *Knee Surg Sports Traumatol Arthrosc*, 8(5): 270–274, 2000
 126. Tan, V., Pepe, M.D., Esterhai, J.L., Jr.: Sepsis of the shoulder girdle. In: *Disorders of the shoulder: diagnosis and management*. Edited by Iannotti, J., Williams, G.R., pp. 951–976. Philadelphia, Baltimore, New York, London, Buenos Aires, Hong Kong, Sydney, Tokyo, Lippincott Williams and Wilkins, 1998
 127. Thomas, S.C., Matsen, F.A., III: An approach to the repair of avulsion of the glenohumeral ligaments in the management of traumatic anterior glenohumeral instability. *J Bone Joint Surg Am*, 71(4): 506–513, 1989
 128. Thomazeau, H., Rolland, Y., Lucas, C., Duval, J.M., Langlais, F.: Atrophy of the supraspinatus belly. Assessment by MRI in 55 patients with rotator cuff pathology. *Acta Orthop Scand*, 67(3): 264–268, 1996
 129. Tossy, J.D., Mead, N.C., Sigmond, H.M.: Acromioclavicular separations: useful and practical classification for treatment. *Clin Orthop Relat Res*, 28: 111–119, 1963
 130. Uthoff, H.K., Loehr, J.W.: Calcific tendinopathy of the rotator cuff: pathogenesis, diagnosis, and management. *J Am Acad Orthop Surg*, 5(4): 183–191, 1997
 131. Vangsness, C.T., Jr., Jorgenson, S.S., Watson, T., Johnson, D.L.: The origin of the long head of the biceps from the scapula and glenoid labrum. An anatomical study of 100 shoulders. *J Bone Joint Surg Br*, 76(6): 951–954, 1994
 132. Visotsky, J.L., Basamania, C., Seebauer, L., Rockwood, C.A., Jensen, K.L.: Cuff tear arthropathy: pathogenesis, classification, and algorithm for treatment. *J Bone Joint Surg Am*, 86–A Suppl 2: 35–40, 2004
 133. Walch, G.: Directions for the use of the quotation of anterior instabilities of the shoulder. In: *First Opne Congress of the European Society of Surgery of the Shoulder and Elbow*, pp. 51–55. Paris, 1987
 134. Walch, G., Badet, R., Boulahia, A., Khoury, A.: Morphologic study of the glenoid in primary glenohumeral osteoarthritis. *J Arthroplasty*, 14(6): 756–760, 1999
 135. Wallace, W.A., Barton, J.B., Wiley, A.M.: The power available during movement of the shoulder. In: *Surgery of the shoulder*. Edited by Bateman, J.E., Welsch, R.P., pp. 1–5. Toronto, C.V. Mosby, 1984
 136. Wilde, A., Borden, L.S., Brems, J.J.: Experience with the Neer total shoulder replacement. In: *Surgery of the shoulder*. Edited by Bateman, J.E., Welsch, R.P., pp. 224–228. Philadelphia, Toronto, B.C. Decker Inc., The C.V. Mosby Company, 1984

137. Wolf, E.M., Cheng, J.C., Dickson, K.: Humeral avulsion of glenohumeral ligaments as a cause of anterior shoulder instability. *Arthroscopy*, 11(5): 600–607, 1995
138. Wolf, R.E., Enneking, W.F.: The staging and surgery of musculoskeletal neoplasms. *Orthop Clin North Am*, 27(3): 473–481, 1996
139. Wright, T.W., Cofield, R.H.: Humeral fractures after shoulder arthroplasty. *J Bone Joint Surg Am*, 77(9): 1340–1346, 1995
140. Yamaguchi, K., Bindra, R.: Disorders of the biceps tendon. In: *Disorders of the shoulder: diagnosis and management* Edited by Iannotti, J., Williams, G.R., pp. 159–190. Philadelphia, Baltimore, New York, London, Buenos Aires, Hong Kong, Sydney, Tokyo, Lippincott Williams and Wilkins, 1999
141. Yian, E.H., Ramappa, A.J., Arneberg, O., Gerber, C.: The Constant score in normal shoulders. *J Shoulder Elbow Surg*, 14(2): 128–133, 2005
142. Zanetti, M., Gerber, C., Hodler, J.: Quantitative assessment of the muscles of the rotator cuff with magnetic resonance imaging. *Invest Radiol*, 33(3): 163–170, 1998
143. Zdravkovic, D., Damholt, V.V.: Comminuted and severely displaced fractures of the scapula. *Acta Orthop Scand*, 45(1): 60–65, 1974
144. Gerber C., Krushell R.: Isolated rupture of the tendon of the subscapularis muscle. *J Bone Joint Surg (Br)*, 73: 389–394, 1991
145. Gagey O.J., Gagey N.: The hyperabduction test: an assessment of the laxity of the inferior glenohumeral ligament. *J Bone Joint Surg*, 82B: 69–74, 2001
146. Pande P., Hawkins R., Peat M.: Electromyography in voluntary posterior instability of the shoulder. *Am J Sports Med*, 17: 644–648, 1989
147. Ficat R.P., Arlet J.: Ischemia and necrosis of bone. In: *Necrosis of the femoral head*. Williams and Wilkins, p 53. Baltimore, 1980
148. Springfield D.S., Enneking W.J.: Surgery of aseptic necrosis of the femoral head. *Clin Orthop*, 130: 175, 1978
149. Cruess R.L.: Steroid induced avascular necrosis of the head of the humerus. *J Bone Joint Surg*, 58-B: 313, 1976

Subject Index

A

- AC-joint dislocation 93
- acquired recurrent posterior subluxation 77
- acromioclavicular dislocations 96
- acromioclavicular injuries 93
- acromioclavicular joints 91
- acromion 1
- acromion shape 2
- adhesive capsulitis 14
- ALPSA lesion 73
- AMBRII 61
- American Shoulder and Elbow Surgeons (ASES) 222
 - patient self-evaluation 222
 - physician assessment 227
 - shoulder score index 228
- anatomic neck 127
- AO-Classification 131
 - anatomic location 133
 - bone segments 133
 - coding 137
 - fractures types 135
 - humerus proximal 137
 - long bones 133
 - principle 132
- articular surface defect 131
 - head-splitting fractures 131
 - impaction fracture 131
- avascular necrosis 167
 - humeral head 167

B

- Bankart line 73
- biceps, origin of the long head 35
 - types of attachment 35

- biceps tendon disorders 41
 - dislocation 43
 - histological changes 42
 - subluxation
- bone defects, inverse shoulder arthroplasty 195
- Bony Bankart lesion 73

C

- calcific deposit 11
- calcifying tendinosis 9
- capsuloligamentous lesions 87
- chondromalacia 155
 - macroscopic aspect 155
- chronic locked shoulder instability 65
- clavicle 117
- clavicular fractures 106, 107, 111
 - distal 109
 - nonunion 117
- Codman's triangles 187
- complete (C) rotator cuff tears 23
 - extent off 24
- Constant-Murley score 199
 - normative age- and gender-related 204
 - normative age- and sex specific 202
 - questionnaire based 205
 - valuation 204
- creosote tears 26
- cuff tear arthropathy 21, 160
 - osteoarthritis 162

D

- degenerative calcification 9
- Disability of the Arm, Shoulder and Hand (DASH) 213

- instructions 220
- scoring 220
- Disability/symptom score 221
- missing items 221
- optional modules 221
- dislocation arthropathy 163
- dislocation
 - AC-joint 93
 - acromioclavicular 96
 - recurrent 59
- double labral lesion 73
- dynamic instabilities 64
- dysplastic recurrent posterior subluxation 77

E

- epiphyseal fractures 117
- clavicle 117
- extralabral ligament lesion 75

F

- fatty muscle degeneration 33
- CT scan 34
- four-part,
 - fractures 129
 - valgus impact 129
- fracture
 - clavicular 106, 107, 111
 - - distal 109
 - - nonunion 117
 - epiphyseal 117
 - - clavicle 117
 - four-part 129
 - glenoid 148
 - glenoid cavity 148
 - glenoid neck 150
 - head-splitting 123
 - humerus, sequelae of proximal 140
 - interligamentous 110
 - intraarticular 147
 - one part 126
 - periprosthetic humeral 142
 - proximal humeral 119
 - scapular 143
 - surgical-neck 121

- fracture-dislocation 123, 130
- frozen shoulder 13
- primary 13
- secondary 13
- full thickness rotator of cuff tears 26

G

- GLAD lesion 75
- glenohumeral ligament 49, 53, 56
- inferior 54
- middle 53
- normal variations 56
- topographical relationship 50
- glenohumeral translation 58
- glenoid bone deficiencies 195
- glenoid cavity, fractures 148
- glenoid erosion 162
- glenoid fractures 148
- glenoid morphology in primary glenohumeral osteoarthritis 155
- glenoid morphology, vertical 157
- glenoid neck fractures 150
- glenoid rim lesions 79

H

- HAGL lesion 75
- head-splitting fracture 123
- heterotopic bone 197
- hidden rotator interval lesions 45
- Hill-Sachs lesions 79
- engaging 80
- nonengaging 80
- humeral head 167
- avascular necrosis 167
- humeral head subluxation 157
- humerus fracture, sequelae of proximal 140

I

- IGHL, posterior band 55
- impingement 7, 8
- inclination deformity 157
- inferior glenohumeral ligament 54
- injuries, acromioclavicular 93

injury, SC-joint 103
 instability static 62
 instability
 – chronic locked shoulder 65
 – dynamic 64
 – multidirectional 68
 – posterior shoulder 76
 – – acute 76
 – – recurrent 76
 – – voluntary recurrent 76
 – unidirectional 65
 – voluntary 69
 interligamentous fractures 110
 intraarticular fractures 147

J

joint infection 179
 joints
 – acromioclavicular 91
 – sternoclavicular 91

L

L'Insalata 246
 lesion
 – ALPSA lesion 73
 – Bankart line 73
 – Bony Bankart lesion 73
 – capsuloligamentous 87
 – double labral lesion 73
 – extralabral ligament lesions 75
 – GLAD lesion 75
 – glenoid rim 79
 – HAGL lesion 75
 – Hill-Sachs 79
 – – engaging 80
 – – nonengaging 80
 – LHB- lesions 40
 – McLaughlin lesion 66
 – Non-Bankart lesions 75
 – Perthes line 73
 – pulley lesions 46
 – Quattro labral lesions 75
 – “satellite” 188
 – SLAP 36
 – – definition 36

– – subtypes 39
 – triple labral 75
 Lockwick IA 186
 Lockwick IB 187
 Lockwick III 189

M

massive rotator cuff tears 158
 – osteoarthritis 159
 massive tear 28
 McLaughlin lesion 66
 metastases 184
 middle glenohumeral ligament 53
 multidirectional hyperlaxity 61
 multidirectional instability 61, 68
 muscle patterning 72
 musculoskeletal neoplasm 184
 – metastases 184
 musculoskeletal sarcoma 183

N

Non-Bankart lesions 75

O

one part fractures 126
 origin of the long head of the biceps 35
 – types of attachment 35
 os acromiale 3
 – definition 4
 – incidence 4
 osteonecrosis 165
 – humeral head, classification 169
 overhand of throwing athletes 84
 Oxford questionnaire 253
 Oxford shoulder instability question-
 naire 256

P

partial-thickness tears 20
 periprosthetic humeral fracture 142
 Perthes line 73
 polar groups 71
 posterior band of the IGHL 55

- posterior Bankart 66
- posterior shoulder instability 76
 - acute 76
 - recurrent 76
 - voluntary recurrent 76
- proximal humeral fracture 119
- pulley lesions 46

Q

- Quattro labral lesion 75
- questionnaires 246
 - shoulder rating questionnaire 248
- QuickDASH 214

R

- radiolucent lines 191
 - glenoid component 192, 194
 - - cemented 193, 194
 - humeral component 191
- recurrent dislocation 59
- rheumatoid arthritis 171
 - ascending form 174
 - centralization 172
 - centred form 175
 - destructive form 175
 - dry form 171
 - glenoid wear 173
 - wear of the humeral head 173
 - wet and resorptive form 172
 - wet form 172
- rotator cuff quality-of-life measure (RC-QOL) 266
- rotator cuff tears 17
 - complete 23
 - extent of 24
 - full thickness 26
 - topography 17, 19
- Rowe score 259
 - modified 259

S

- “satellite” lesions 188
- scapular dyskinesis 49
 - definition 49

- scapular fractures 143
- SC-joint injury 103
- septic arthritis 179
 - anatomic types 180
 - clinical host 181
 - host 180
- sequelae of proximal Humerus fracture 140
- SF-36 233
 - Construction 240
 - SF-36v1 Acute 235
 - SF-36v1 Standard 234
 - SF-36v2 Acute 238
 - SF-36v2 Standard 237
 - SF-36v2™ 241
 - Version2.0 241
- shoulder 13
- shoulder pain disability index (SPADI) 243
 - scoring index 245
- simple shoulder test (SST) 228
 - test kit 229
- SLAP lesions 36
 - definition 36
 - subtypes 39
- Southern Californian Orthopedic Institute rotator cuff classification system (PASTA) 22
- static instabilities 62
- sternoclavicular joints 91
- subluxation
 - acquired recurrent posterior 77
 - dysplastic recurrent posterior 77
 - humeral head 157
- subscapularis tendon tears 28
- superior shoulder suspensory complex (SSSC) 151
- supracapular notch 5
- supraspinatus muscle atrophy 29
 - MRI 29
 - occupation ratio 30
- surgical-neck fracture 121
- synovial recesses 49
 - variations 49

T

- tangent sign 31
- tear
 - crescent 26
 - massive 28
 - trapezoidal 28
- tendon retraction 29
- tendon tears, subscapularis 28
- three-part 129
- trauma, unidirectional Bankart, and surgery (TUBS) 59
- triangular defect 26
- triple labral lesion 75
- TUBS 59
- two-part shaft 17, 127
 - comminuted 128
 - impacted 127
 - unimpacted 127

U

- UCLA shoulder rating 212
- unidirectional instability 65

V

- VAS 242
- vertical glenoid morphology 157
- voluntary instability 69

W

- Walch-Duplay score 264
- Western Ontario osteoarthritis of the shoulder index (WOOS) 273
- Western Ontario rotator cuff index (WORC) 266
- Western Ontario shoulder instability index (WOSI) 259